

CASE REPORT / ПРИКАЗ БОЛЕСНИКА

Surgical treatment of a carotid artery aneurysm associated with kinking – A case report and review of literature

Predrag Matić^{1,2}, Mihailo Nešković¹, Dragoslav Nenezić^{1,2}, Slobodan Tanasković^{1,2}, Srđan Babić^{1,2}, Petar Popov^{1,2}, Đorđe Radak^{1,2}

¹"Dedinje" Cardiovascular Institute, Vascular Surgery Clinic, Belgrade, Serbia;

²University of Belgrade, School of Medicine, Belgrade, Serbia



SUMMARY

Introduction An extracranial carotid artery aneurysm is a rare clinical entity with potentially debilitating consequences. Our aim is to present a case of a large internal carotid artery aneurysm combined with medial internal carotid artery (ICA) kinking successfully treated by resection with an end-to-end anastomosis.

Case outline A 34-year-old female patient was admitted to our hospital due to dizziness and frequent non-specific headaches. On admission, routine echocardiography showed an aneurysm of the atrial septum. Multislice computed tomography of the supraaortic branches showed medial kinking of the right ICA with a 15 mm aneurysm localized on the vertex of the angulation. Kinking was present on the left ICA as well, with a small aneurysm of 5 mm in diameter. The right ICA aneurysm was resected and the artery was reconstructed with an end-to-end anastomosis. The postoperative course was uneventful and the patient was symptom-free after a one-year follow-up.

Conclusion We showed that surgery of an aneurysm and kinking of the carotid artery in the medial segment of the ICA is possible and safe to perform. Detailed preoperative preparation, precise surgical technique, and short clamping time all contributed to a good final outcome.

Keywords: carotid artery aneurysm; kinking; surgical treatment

INTRODUCTION

An extracranial carotid artery aneurysm is a rare clinical entity with potentially debilitating consequences [1]. According to major referral centers, they account for 0.4–0.9% of all repaired aortic and peripheral artery aneurysms [1, 2]. Therefore, only a small number of reports in the literature describes an internal carotid artery (ICA) aneurysm associated with kinking [3–7]. Our aim is to present a case of a large ICA aneurysm combined with medial ICA kinking successfully treated with resection with an end-to-end anastomosis.

CASE REPORT

A 34-year-old female patient was admitted to our hospital due to dizziness and frequent non-specific headaches. Arterial hypertension, hyperlipidemia, smoking, and positive family history were identified as risk factors for atherosclerosis. The patient denied any other chronic illnesses, previous surgery, or trauma.

On admission, routine echocardiography showed an aneurysm of the atrial septum and a potentially patent foramen ovale. Subsequent transesophageal echocardiography confirmed the presence of the aneurysm, but the presence of a shunt between the atria was excluded.

Multislice computed tomography of the supraaortic branches showed medial kinking of the right ICA with a 15 mm aneurysm localized on the vertex of the angulation (Figure 1). Kinking was also present on the left ICA with a small aneurysm of 5 mm in diameter. Other supraaortic branches and intracranial arterial network had no significant lesions. In addition, computed tomography of the brain without contrast did not reveal any pathological findings.

The patient underwent surgery in general anesthesia. Carotid arteries were exposed

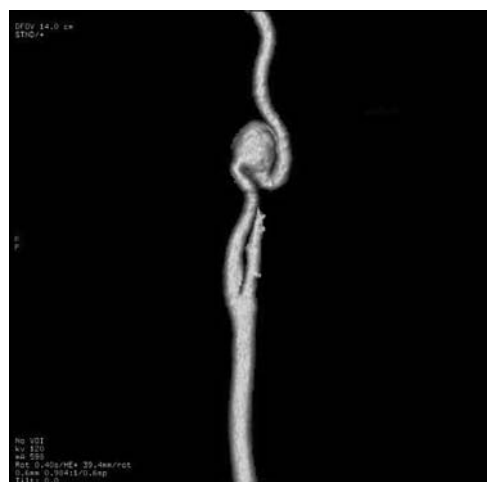

Figure 1. Multislice computed tomography angiography; the right internal carotid artery aneurysm associated with medial kinking

Примљено • Received:
December 28, 2015

Прихваћено • Accepted:
September 21, 2016

Online first: May 30, 2017

Correspondence to:

Mihailo NEŠKOVIĆ
"Dedinje" Cardiovascular Institute
Vascular Surgery Clinic
1 Heroja Milana Tepića Street
11000 Belgrade, Serbia
mihailoneskovic@yahoo.com

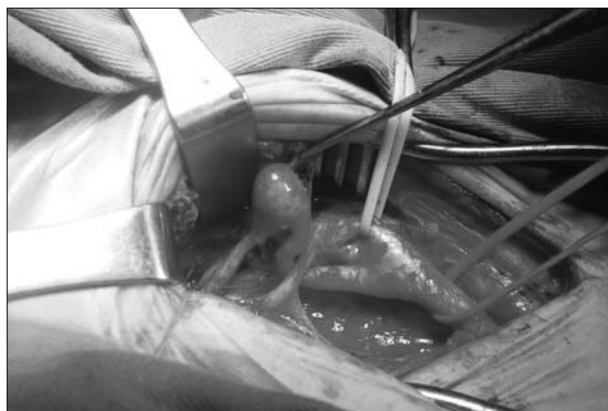


Figure 2. Intraoperative findings; the right internal carotid artery aneurysm associated with kinking, positioned cranial to the hypoglossal nerve

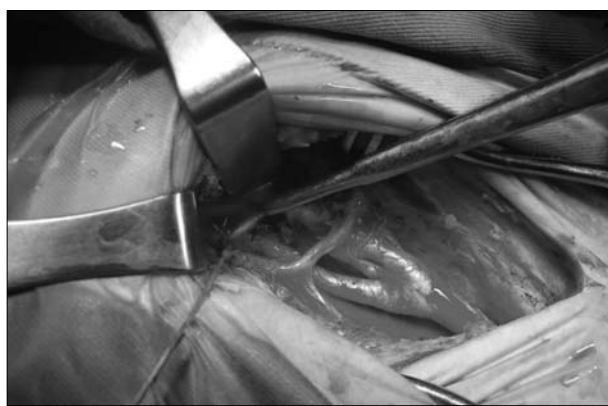

Figure 3. Intraoperative findings; the right internal carotid artery reconstructed with end-to-end anastomosis

through a typical longitudinal incision on the right side of the neck. The aneurysm and the kinked segment of the ICA were dissected. The aneurysm was located approximately 5 cm from the carotid bifurcation, and about 1.5 cm distally from the hypoglossal nerve (Figure 2). After systemic heparin administration, carotid arteries were clamped (without shunt insertion), the aneurysm was resected and the ICA was reconstructed with an end-to-end anastomosis (Figure 3). Clamping time was 7 minutes.

The resected aneurysm was sent for pathohistology, which showed that the arterial wall was irregularly thinned, with a discrete intimal layer and congestion in the adventitial layer.

On the second postoperative day, the patient had a mild edema of the right hypopharynx, which was successfully treated with corticosteroids. There were no other complications in the immediate postoperative period. She was discharged from the hospital in good condition on the fourth postoperative day. After the one-year follow-up the patient was symptom-free and Doppler ultrasound revealed normal findings on the right carotid artery.

DISCUSSION

Carotid artery aneurysm treatment accounts for only 1–1.5% of all surgeries performed in treatment of extra-

cranial cerebrovascular disease [1, 8]. The patients' age varies from 26 to 82 years throughout the studies, and is typically related to the etiology of the disease [1].

Most authors report atherosclerosis as the most common cause of true extracranial ICA aneurysms. On the other hand, pseudoaneurysms can be a result of trauma or infection, especially in younger population. There is also a subgroup of patients with pseudoaneurysms related to previous carotid endarterectomy with patch angioplasty [1, 2, 9, 10].

Carotid aneurysms are often identified by the presence of a pulsatile mass on the lateral side of the neck. Symptomatic ICA aneurysms usually give neurological symptoms, global in more cases than hemispheric. In addition, a significant number of patients with larger aneurysms also have symptoms due to the compression of the surrounding structures. However, prevention of complications like rupture, complete thrombosis of the aneurysm, and brain embolisation resulting in an acute ischemic event is the main goal of treatment.

Treatment of carotid artery aneurysm comprises of surgical and endovascular approaches. In distant past, ligation of the common carotid artery was the treatment of choice, but had high rates of morbidity and mortality [11]. Later, various surgical techniques were developed, including aneurysmectomy with primary/patch closure, resection of the aneurysm with primary anastomosis or grafting (both venous and synthetic) [12].

A recent systematic review identified 281 articles reporting carotid artery aneurysms from 1900 to July 2014 [10]. Although natural history of this disease is not well understood, aneurysms seem to rupture rarely. Consequently, the focus of treatment was mainly the prevention of thromboembolic events. Most authors conducted surgical treatment with good long-term results, but with considerable incidence of cranial nerve damage. Endovascular approach also showed satisfying results, but with no mid- or long-term follow-up.

True prevalence of ICA kinking in the general population is unknown. Several reports show that this condition is bilateral in 25–50% of cases and that it is more common in women [13, 14]. The relationship between the degree of ICA kinking and neurologic symptoms is still unclear. Patients with tortuous carotid arteries are rarely symptomatic, but if so, they usually present with global neurological symptomatology. In a randomized controlled trial, including patients with ICA kinks and coils with hemispheric neurological symptoms, the authors showed significantly better results with surgical than with best medical treatment [13]. Changes in hemodynamics of the blood flow through the kinked ICA segment can mimic stenosis and can also influence changes in the intimal layer of the arterial wall, leading to ulcerations and predisposition for thrombosis.

We identified just a few cases in the literature concerning ICA aneurysms secondary to carotid artery kinks and coils, and, to our knowledge, none of them presented a case of such a young female patient [3, 4, 6, 7]. In our case, a saccular aneurysm of the ICA was formed secondary to hemodynamically significant kinking of the vessel.

According to Welleweerd et al. [14], carotid artery aneurysms can be histologically classified as degenerative

and dissective. Although our sample was not identically processed, it could be categorized as degenerative due to the variable thickness of the arterial wall and the absence of any intimal disruptions. However, there were no inflammatory cells found in the sample, which differs from the majority of findings in the abovementioned study.

The incidental finding of atrial septal aneurysm without patent foramen ovale could have been important for our patient. Several studies linked this condition to cerebrovascular symptoms and recent strokes in patients with normal carotid arteries [15, 16]. Considering the age of the patient, the presence of the ICA kinking bilaterally, and the two separate entities resulting from the weakness of the cardiovascular wall structure, our opinion is that these conditions might have embryological background.

In our case, the kinking and aneurysm were located well above the mandible angle and cranial to hypoglossal nerve. Meticulous surgical technique and high approach to ICA were performed with the resection of the posterior belly of the digastric muscle. According to our previous experience with treatment of carotid artery aneurysms, the presence of kinking facilitates the resection of the aneurysm with the reconstruction of the ICA with the end-to-end anastomosis [17].

We showed that surgery of an aneurysm and kinking of carotid artery in the medial segment of the ICA is possible and safe to perform. Detailed preoperative preparation, precise surgical technique, and short clamping time all contributed to a good final outcome.

REFERENCES

1. El-Sabroun R, Cooley DA. Extracranial carotid artery aneurysms: Texas Heart Institute experience. *J Vasc Surg.* 2000; 31(4):702–12.
2. McCollum CH, Wheeler WG, Noon GP, DeBakey ME. Aneurysms of the extracranial carotid artery. Twenty-one years' experience. *Am J Surg.* 1979; 137(2):196–200.
3. Dadashov SA, Vinogradov OA, Antsupov KA, Lavrent'ev AV, Shcherbiuk AN. Gigantic aneurysm resulting from pathological kinking of the internal carotid artery. *Angiol Sosud Khir.* 2010; 16(4):198–200.
4. Belov YV, Stepanenko AB, Bogopol'skaia OM, Kizyma AG. Surgical treatment of aneurysm and kinking of the internal carotid artery. *Angiol Sosud Khir.* 2006; 12(4):115–8.
5. Benedetto F, Massara M, Lentini S, Spinelli F. A case of aneurysm and kinking of the extracranial internal carotid artery. *Asian Cardiovasc Thorac Ann.* 2012; 20(6):705–7.
6. Alpagut U, Ugurlucan M, Kafali E, Ali Sayin O, Demir T, Basaran M, et al. Aneurysm of the kinked extracranial internal carotid artery case report and review of the literature. *Acta Chir Belg.* 2005; 105(4):407–9.
7. Nenezic D, Tanaskovic S, Radak D, Babic S, Gajin P. Primary repair of internal carotid artery aneurysm secondary to kinking and cystic medial degeneration. *Vasc Endovasc Surg.* 2013; 47(4):304–9.
8. Schechter DC. Cervical carotid aneurysms. Part II. *NY State J M.* 1979; 79(7):1042–8.
9. Moreau P, Albat B, Thevenet A. Surgical treatment of extracranial internal carotid artery aneurysm. *Ann Vasc Surg.* 1994; 8(5):409–16.
10. Welleweerd JC, den Ruijter HM, Nelissen BG, Bots ML, Kappelle LJ, Rinkel GJ, et al. Management of extracranial carotid artery aneurysm. *Eur J Vasc Endovasc Surg.* 2015; 50(2):141–7.
11. Brackett CE Jr. The complications of carotid artery ligation in the neck. *J Neurosurg.* 1953; 10(2):91–106.
12. Rosset E, Albertini JN, Magnan PE, Ede B, Thomassin JM, Branchereau A. Surgical treatment of extracranial internal carotid artery aneurysms. *J Vasc Surg.* 2000; 31(4):713–23.
13. Ballotta E, Thiene G, Baracchini C, Ermani M, Militelio C, Da Giau G, et al. Surgical vs medical treatment for isolated internal carotid artery elongation with coiling or kinking in symptomatic patients: a prospective randomized clinical study. *J Vasc Surg.* 2005; 42(5):838–46; discussion 46.
14. Welleweerd JC, Nelissen BG, Koole D, de Vries JP, Moll FL, Pasterkamp G, et al. Histological analysis of extracranial carotid artery aneurysms. *PloS One.* 2015; 10(1):c0117915.
15. Mattioli AV, Aquilina M, Oldani A, Longhini C, Mattioli G. Atrial septal aneurysm as a cardioembolic source in adult patients with stroke and normal carotid arteries. A multicentre study. *Eur Heart J.* 2001; 22(3):261–8.
16. Mugge A, Daniel WG, Angermann C, Spes C, Khandheria BK, Kronzon I, et al. Atrial septal aneurysm in adult patients. A multicenter study using transthoracic and transesophageal echocardiography. *Circulation.* 1995; 91(11):2785–92.
17. Radak D, Davidovic L, Tanaskovic S, Banzic I, Matić P, Babic S, et al. A tailored approach to operative repair of extracranial carotid aneurysms based on anatomic types and kinks. *Am J Surg.* 2014; 208(2):235–42.

Хирушко лечење анеуризме каротидне артерије удружене са кинкингом – приказ болесника и преглед литературе

Предраг Матић^{1,2}, Михаило Нешковић¹, Драгослав Ненезић^{1,2}, Слободан Танасковић^{1,2}, Срђан Бабић^{1,2}, Петар Попов^{1,2}, Ђорђе Радак^{1,2}

¹Институт за кардиоваскуларне болести „Дедиње“, Клиника за васкуларну хирургију, Београд, Србија;

²Универзитет у Београду, Медицински факултет, Београд, Србија

САЖЕТАК

Увод Екстракранијална анеуризма каротидних артерија је ретак клинички ентитет са могућим онеспособљавајућим последицама. Циљ рада је да прикажемо случај велике анеуризме унутрашње каротидне артерије (УКА) удружене са кинкингом, која је успешно хируршки третирана ресекцијом анеуризме са термино-терминалном реконструкцијом артерије.

Приказ болесника Жена стара 34 године примљена је у болницу због вртоглавица и учесталих неспецифичних главобоља. На ехокардиографском прегледу уочена је анеуризма атријалног септума. Мултислајсна компјутеризована

томографија супраорталних грана показала је медијални кинкинг десне УКА са анеуризмом промера 15 mm на врху ангулације. Кинкинг је уочен и на левој УКА са анеуризмом промера 5 mm. Анеуризма десне УКА је ресецирана, а артерија је реконструисана термино-терминалном анастомозом. Постоперативни ток је био уредан, као и годину дана после операције.

Закључак Хирушко лечење анеуризме УКА удружене са медијалним кинкингом је ефикасно и безбедно.

Кључне речи: анеуризма каротидне артерије; кинкинг; хируршко лечење