

CASE REPORT / ПРИКАЗ БОЛЕСНИКА

Hypercalciuria caused by *CYP24A1* mutation – fourteen years of the patient's follow-up

Amira Peco-Antić¹, Biljana Ivelja², Gordana Miloševski-Lomić¹, Dušan Paripović¹, Martin Konrad³

¹University Children's Hospital, Belgrade, Serbia;

²Medical Center, Cetinje, Montenegro;

³University Hospital Münster, Department of General Pediatrics, Germany



SUMMARY

Introduction Recently, inactivation mutations of *CYP24A1*, the gene encoding vitamin D 24-hydroxylase, were identified in hypercalciuric nephrolithiasis and nephrocalcinosis. Here, we describe a long-term follow-up of a patient with hypercalciuric nephrolithiasis caused by *CYP24A1* mutations.

Case outline A male Montenegro patient first presented with microhematuria at the age of five years. Hypercalciuria had been documented and for some time he had been treated by hydrochlorothiazide. After 12 years, the patient presented with macrohematuria and left-sided nephrolithiasis. He was found to have intermittent borderline hypercalcemia, suppressed parathyroid hormone, hypercalciuria, and increased plasma 25-hydroxy vitamin D [$25(\text{OH})\text{D}_3$]. The patient denied any vitamin D supplementation and all other causes of hypercalcemia were ruled out. Positive family history for nephrolithiasis (both parents and grandmother) and similar biochemical abnormalities detected in father and son pointed to an inherited disorder. A homozygous mutation in *CYP24A1* (E143del) was found in the patient and his father, while mother is heterozygous. During the follow-up of two years, the patient underwent four extracorporeal shockwave lithotripsies, he was advised to increase water intake, and to avoid sunlight exposure. At the end of follow-up he was asymptomatic, and his renal ultrasound was normal, as well as his renal function, but hypercalciuria and low parathyroid hormone levels persisted.

Conclusion Hypervitaminosis D should be considered in children with idiopathic hypercalciuria, nephrolithiasis and nephrocalcinosis of unknown etiology. Recognition of *CYP24A1* mutations in these patients may help to decrease the serious consequences by avoiding vitamin D supplements and excessive sun exposure.

Keywords: hereditary nephrolithiasis; nephrocalcinosis; hypervitaminosis D; idiopathic hypercalcemia

INTRODUCTION

Metabolic disorders are a common cause of nephrolithiasis in childhood [1]. Of these, the most common is hypercalciuria, which is found in 30–50% of children with stones in the urinary system [2]. Hypercalciuria may be associated with normal, increased, or decreased calcium in the blood (Table 1). Hypercalcemic hypercalciuria may be found in hyperparathyroidism, but also in long-lasting immobilization, sarcoidosis, malignancy, juvenile idiopathic arthritis, corticosteroid excess, adrenal failure, William's syndrome, and vitamin D hypervitaminosis.

Historically, vitamin D hypervitaminosis has been mainly attributed to vitamin D intoxication and/or to an intrinsic hypersensitivity to vitamin D [3, 4, 5]. However, with advances in the molecular examination of vitamin D metabolism, our understanding of vitamin D hypervitaminosis significantly improved [6, 7]. Hypersensitivity to vitamin D, which has been observed in earlier studies [4, 5], now may be explained by a gene mutation leading to defective metabolism of active vitamin D [6]. Indeed, mutations of vitamin D 24-hydroxylase (*CYP24A1*), which normally breaks down both

$1,25(\text{OH})_2\text{D}_3$ and $25(\text{OH})\text{D}_3$, result in excessive formation of $1,25(\text{OH})_2\text{D}_3$ [7]. Increased $1,25(\text{OH})_2\text{D}_3$ levels cause hypercalcemia due to enhanced intestinal calcium absorption and hypercalciuria, because of reduced parathyroid hormone- (PTH) dependent calcium reabsorption in the distal renal tubule [7]. Affected individuals have hypercalcemia and hypercalciuria due to which they are prone to nephrolithiasis/nephrocalcinosis, and consequently renal failure may occur. Being autosomal recessive inherited, this genetic disorder often shows familial occurrence with an increased risk in siblings, who may experience the first clinical signs and diagnosis only in adulthood [8].

It is not rare that nephrolithiasis and nephrocalcinosis caused by *CYP24A1* mutations remain unrecognized despite extensive classical evaluation. The aim of our work is to draw attention to hypercalciuria and nephrolithiasis caused by the *CYP24A1* gene defects.

CASE REPORT

We report a male Montenegro patient who had primarily presented with microhematuria due to idiopathic hypercalciuria at five years of age.

Примљено • Received:

January 16, 2017

Прихваћено • Accepted:

February 22, 2017

Online first: March 31, 2017

Correspondence to:

Amira PECO-ANTIĆ

Dr Nike Miljanića 5

11000 Belgrade

Serbia

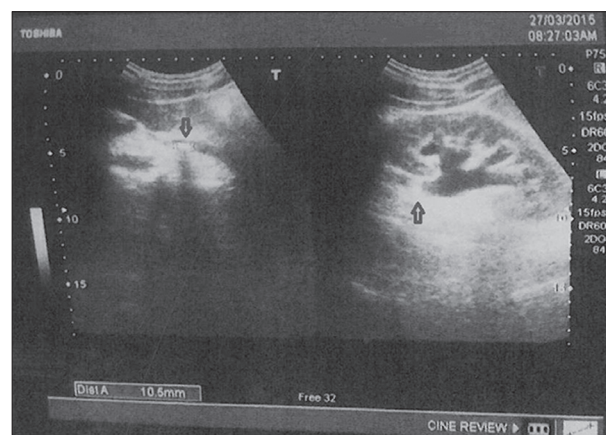
amirapecoantic@yahoo.com

Table 1. The causes of hypercalciuria

HEREDITARY HYPERCALCIURIA	ACQUIRED HYPERCALCIURIA
Normocalcemic hypercalciuria	
Idiopathic	Prematurity
Dent's disease	Drugs: diuretics (furosemide, and acetazolamide), anticonvulsant use (topiramate, zonisamide), ketogenic diet
Antenatal Bartter syndrome	
Familial hypomagnesemia and nephrocalcinosis with hypercalciuria	
Distal renal tubular acidosis	
Hereditary hypophosphatemic rickets with hypercalciuria	
Hypocalcemic hypercalciuria	
Hypoparathyroidism	
Autosomal dominant hypocalcemic hypercalciuria	
Hypercalcemic hypercalciuria	
Primary hyperparathyroidism (PHPT)	PHPT sporadic: single parathyroid adenoma, not inherited
MEN1 syndrome-associated PHPT	Long-lasting immobilization
Familial isolated PHPT	Sarcoidosis
Hyperparathyroidism 2	Malignancies
Metaphyseal chondrodysplasia Jansen type	Juvenile idiopathic arthritis
Inherited hypophosphatasia	Corticosteroid excess
	Adrenal failure
	Vitamin D / vitamin A intoxication
Williams Beuren syndrome	Chronic kidney disease
Vitamin D induced infantile hypercalcemia-CYP24A1 gene mutation	Drugs: calcium carbonate, lithium

Renal ultrasound was normal, and he was treated by hydrochlorothiazide. After 12 years, the patient presented with macrohematuria and left-sided renal colic due to nephrolithiasis (Figure 1). He was found to have intermittent borderline hypercalcemia (serum Ca 2.46–2.66 mmol/l), low level of intact PTH (< 0.26 pmol/l), hypercalciuria (11.6 mmol / 24 hours), and increased plasma 25-hydroxy vitamin D [$25(\text{OH})\text{D}_3$] (137.3 nmol/l). Serum $1,25(\text{OH})_2\text{D}_3$ was not measured. The patient denied using vitamin D supplementation, but certainly had a great deal of seasonal sunlight exposure due to Mediterranean climate. Serum electrolytes including magnesium and phosphorus were normal, as well as serum bicarbonate, urea, and creatinine. Twenty-four-hour urine evaluations excluded hyperuricosuria and oxaluria. Also, other causes of hypercalcemia were ruled out. Chemical analysis of stone found calcium oxalate.

During further follow-up of two years the patient was treated with four courses of extracorporeal shockwave lithotripsy, increased water intake, and he was advised to avoid sunlight exposure. At the end of the follow-up he was asymptomatic, and his renal ultrasound was normal, as well as his renal function. The latest biochemical findings were as follows: serum calcium normal (2.34 mmol/l; Ca^{++} 1.12 mmol/l), intact PTH low (1.37 pmol/l), $25(\text{OH})\text{D}_3$

**Figure 1.** Renal ultrasound displaying the patient's left kidney – hydronephrosis due to a stone in the proximal part of the left ureter (arrowed)

in the upper normal range (123.5 nmol/l) and increased 24-hour calciuria (8.88 mmol / 24 hours).

The patient's family history was positive for kidney stones: in the father (at the age of 17 years), the mother (at the age of 35 years) and the paternal grandmother. At the time of this study, renal ultrasound was normal in the parents, but hypercalcemia (2.62 mmol/l), hypercalciuria (12.41 mmol / 24 hours), depressed PTH (1.07 pmol/l) and increased $25(\text{OH})\text{D}_3$ (94.3 nmol/l) were found in the father as well as in our patient. Familial occurrence of nephrolithiasis pointed out its inherited occurrence. Using polymerase chain reaction and Sanger sequencing, a homozygous mutation in *CYP24A1* (E143del) was found in the patient and his father, while the mother is heterozygous. The parents declared not to be consanguineous.

DISCUSSION

Our patient as well as his father have an E143del homozygous mutation in *CYP24A1*. This mutation, previously described by Schlingmann et al. [9], leads to a complete loss of 25-OH-D₃-24-hydroxylase activity that results in persistently increased levels of both $1,25(\text{OH})_2\text{D}_3$ and $25(\text{OH})\text{D}_3$ and the absence of any measurable inactive metabolite. Basal renal and extrarenal *CYP24A1* is usually low but is highly induced by its substrate $1,25(\text{OH})_2\text{D}_3$.

In regulating the level of vitamin D₃, *CYP24A1* plays a role in calcium homeostasis and the vitamin D endocrine system. Its highest expression is in the intestine, the kidneys, and the skin, where this enzyme acts to remove metabolites of vitamin D [10]. It has been demonstrated that *CYP24A1* knockout ($-/-$) mice suffer from increased sensitivity to exogenous vitamin D intake and approximately half of them die due to severe hypercalcemia [11]. In humans, *CYP24A1* mutations can cause idiopathic infantile hypercalcemia (IIH) [12–19], idiopathic hypercalciuria [9], nephrocalcinosis, and possibly reduced bone density [20]. In patients with IIH due to *CYP24A1* mutations, even small doses of vitamin D, as prescribed for vitamin D prophylaxis, may provoke symptomatic hypercalcemic

crisis which need treatment by acute hemodiafiltration [16]. Increased sensitivity to vitamin D in patients with *CYP24A1* mutations has been also documented by seasonal variations of vitamin D and calcium parameters due to sunlight exposure [17, 18]. Calcemia may also be influenced by alimentary factors. Those may explain the intermittent character of hypercalcemia in our patient as well, as he did not receive any vitamin D supplementation. During his first clinical examination at five years of age, it was winter time and investigation did not reveal hypercalcemia, but only hypercalciuria. Therefore, in patients with idiopathic hypercalciuria, serum calcium level should be monitored carefully throughout life.

Kidney damage may occur in patients with *CYP24A1* mutations, because of nephrolithiasis and/or nephrocalcinosis. It has been estimated that the overall frequency of kidney stones due to *CYP24A1* deficiency is 4–20% [20, 21]. However, it probably may be even higher in children as the majority of children with nephrolithiasis have a metabolic background and familial occurrence [1]. Our patient had familial history of nephrolithiasis. His father, who

has the identical *CYP24A1* mutation and almost identical biochemical alterations, had a kidney stone at adolescent age, but with milder clinical course. It is only uncertain if transient nephrolithiasis in the patient's mother was the consequence of the heterozygous *CYP24A1* mutation. Data from literature suggest that most heterozygous *CYP24A1* mutation carriers have a normal vitamin D level, usually are asymptomatic, but may possibly be at an increased risk of nephrolithiasis [22].

Treatment options for *CYP24A1* mutation disorders include avoidance of vitamin D supplementation, sunlight exposure and tanning beds, and high water intake, while in severely affected patients, treatment with cytochrome ketoconazole inhibitor may be beneficial [23].

ACKNOWLEDGMENT

Writing of this paper was supported by the Ministry of Education, Science and Technological Development of the Republic of Serbia, grant No. 175079.

REFERENCES

- Habbig S, Beck BB, Hoppe B. Nephrocalcinosis and urolithiasis in children. *Kidney Int.* 2011; 80(12):1278–91.
- Tabel Y, Mir S. The long-term outcomes of idiopathic hypercalciuria in children. *J Pediatr Urol.* 2006; 2(5):453–8.
- British Paediatric Association. Hypercalcaemia in infants and vitamin D. *BMJ.* 1956; 2:149.
- Lightwood R. Idiopathic hypercalcaemia with failure to thrive: nephrocalcinosis. *Proc R Soc Med.* 1952; 45:401.
- Smith DW, Blizzard RM, Harrison HE. Idiopathic hypercalcemia; a case report with assays of vitamin D in the serum. *Pediatrics.* 1959; 24(2):258–69.
- Prosser DE, Jones G. Enzymes involved in the activation and inactivation of vitamin D. *Trends Biochem Sci.* 2004; 29(12):664–73.
- Miller WL. Genetic disorders of Vitamin D biosynthesis and degradation. *J Steroid Biochem Mol Biol.* 2017; 165(Pt A):101–8.
- Jobst-Schwan T, Pannes A, Schlingmann KP, Eckardt KU, Beck BB, Wiesener MS. Discordant clinical course of vitamin-D-hydroxylase (*CYP24A1*) associated hypercalcemia in two adult brothers with nephrocalcinosis. *Kidney Blood Press Res.* 2015; 40(5):443–51.
- Schlingmann KP, Kaufmann M, Weber S, Irwin A, Goos C, John U, et al. Mutations in *CYP24A1* and idiopathic infantile hypercalcemia. *N Engl J Med.* 2011; 365(5):410–21.
- Akeno N, Matsunuma A, Maeda T, Kawane T, Horiuchi N. Regulation of vitamin D-1 α -hydroxylase and -24-hydroxylase expression by dexamethasone in mouse kidney. *J Endocrinol.* 2000; 164(3):339–48.
- St-Arnaud R, Arabian A, Travers R, Barietta F, Raval-Pandya M, Chapin K, et al. Deficient mineralization of intramembranous bone in vitamin D-24-hydroxylase-ablated mice is due to elevated 1,25-dihydroxyvitamin D and not to the absence of 24,25-dihydroxyvitamin D. *Endocrinology.* 2000; 141(7):2658–66.
- Molin A, Baudoin R, Kaufmann M, Souberbielle JC, Ryckewaert A, Vantghem MC, et al. *CYP24A1* Mutations in a cohort of hypercalcemic patients: Evidence for a recessive trait. *J Clin Endocrinol Metab.* 2015; 100(10):E1343–52.
- Marks BE, Doyle DA. Idiopathic infantile hypercalcemia: case report and review of the literature. *J Pediatr Endocrinol Metab.* 2016; 29(2):127–32.
- Gigante M, Santangelo L, Diella S, Caridi G, Argentiero L, D'Alessandro MM, et al. Mutational spectrum of *CYP24A1* gene in a cohort of Italian patients with idiopathic infantile hypercalcemia. *Nephron.* 2016; 133(3):193–204.
- Tray KA, Laut J, Saidi A. Idiopathic infantile hypercalcemia, presenting in adulthood—no longer idiopathic nor infantile: Two case reports and review. *Conn Med.* 2015; 79(10):593–7.
- Fencel F, Bláhová K, Schlingmann KP, Konrad M, Seeman T. Severe hypercalcemic crisis in an infant with idiopathic infantile hypercalcemia caused by mutation in *CYP24A1* gene. *Eur J Pediatr.* 2013; 172(1):45–9.
- Ertl DA, Raimann A, Csicsich D, Patsch JM, Laccone F, Haeusler GA. Pediatric patient with a *CYP24A1* mutation: Four years of clinical, biochemical, and imaging follow-up. *Horm Res Paediatr.* 2017; 87(3):196–204.
- Figueres ML, Linglart A, Bienaime F, Allain-Launay E, Roussey-Kessler G, Ryckewaert A, et al. Kidney function and influence of sunlight exposure in patients with impaired 24-hydroxylation of vitamin D due to *CYP24A1* mutations. *Am J Kidney Dis.* 2015; 65(1):122–6.
- Dinour D, Davidovits M, Aviner S, Ganon L, Michael L, Modan-Moses D, et al. Maternal and infantile hypercalcemia caused by vitamin-D-hydroxylase mutations and vitamin D intake. *Pediatr Nephrol.* 2015; 30(1):145–52.
- Nesterova G, Malicdan MC, Yasuda K, Sakaki T, Vilboux T, Ciccone C, et al. 1,25-(OH)₂D-24 Hydroxylase (*CYP24A1*) deficiency as a cause of nephrolithiasis. *Clin J Am Soc Nephrol.* 2013; 8(4):649–57.
- Figueres ML, Linglart A, Bienaime F, Allain-Launay E, Roussey-Kessler G, Ryckewaert A, et al. Kidney function and influence of sunlight exposure in patients with impaired 24-hydroxylation of vitamin D due to *CYP24A1* mutations. *Am J Kidney Dis.* 2015; 65(1):122–6.
- Cools M, Goemaere S, Baetens D, Raes A, Desloovere A, Kaufman JM, et al. Calcium and bone homeostasis in heterozygous carriers of *CYP24A1* mutations: A cross-sectional study. *Bone.* 2015; 81:89–96.
- Sayers J, Hynes AM, Srivastava S, Downen F, Quinton R, Datta HK, et al. Successful treatment of hypercalcaemia associated with a *CYP24A1* mutation with fluconazole. *Clin Kidney J.* 2015; 8(4):453–5.

Хиперкалциурија изазвана мутацијом *CYP24A1* – четрнаест година праћења

Амира Пецо-Антић¹, Биљана Ивеља², Гордана Милошевски-Ломић¹, Душан Париповић¹, Мартин Конрад³

¹Универзитетска дечја клиника, Београд, Србија;

²Медицински центар, Цетиње, Црна Гора;

³Универзитетска дечја клиника у Минстеру, Одељење опште педијатрије, Минстер, Немачка

САЖЕТАК

Увод Недавно је као узрок хиперкалциуричне нефролитијазе и нефрокалцинозе откривена инактивациона мутација *CYP24A1*, гена који кодира витамин Д 24-хидроксилазу.

Циљ овог рада је опишемо дуготрајно праћење болесника са хиперкалциуричном нефролитијазом изазваном *CYP24A1* мутацијом.

Приказ болесника Дечак из Црне Горе први пут је испитан због микрохематурије у петој години живота. Доказана је хиперкалциурија, због које је једно време лечен хидрохлортиазидом. После 12 година поново се јавио због макрохематурије и левостране нефролитијазе. Доказани су интермитентна хиперкалцемија, низак ниво паратхормона, хиперкалциурија и повећан ниво 25-хидрокси витамина Д [$25(\text{OH})_2\text{D}_3$] у плазми. Болесник није узимао суплементе са витамином Д и сви познати узроци хиперкалцемије су искључени. Фамилијарна историја је позитивна за нефролитијазу (оба родитеља и баба по оцу), а сличне биохемиј-

ске абнормалности код оца и сина су указале на наследни поремећај. Откривена је хомозиготна мутација *CYP24A1* (*E143del*) код болесника и његовог оца, док је мајка била хетерозигот. У току даљег праћења од две године болесник је лечен екстракорпоралном литотрипсијом у четири наврата, повећаним уносом течности и избегавањем сунчања. На крају праћења он је био без симптома, нормалне глобалне функције бубрега, нормалног ултрасонографског налаза уринарног тракта, али са хиперкалциуријом и ниским нивоом паратхормона у плазми.

Закључак Код болесника који имају идиопатску хиперкалциурију, нефролитијазу и нефрокалцинозу непознатог узрока, треба испитати витамин Д. Код мутације *CYP24A1* озбиљне компликације могу се избећи једноставним мерама: избегавање сунчања и витамина Д у витаминским суплементима и храни.

Кључне речи: херидитарна нефролитијаза; нефрокалциноза; хипервитаминоза Д; идиопатска хиперкалцемија