

ORIGINAL ARTICLE / ОРИГИНАЛНИ РАД

Modified orthotopic ileal neobladder – surgical technique and initial results

Vuk Sekulić^{1,2}, Jovo Bogdanović^{1,2}, Jasenko Đozić^{1,2}, Ranko Herin¹, Dimitrije Jeremić^{1,2}¹Clinical Center of Vojvodina, Clinic of Urology, Novi Sad, Serbia;²University of Novi Sad, Faculty of Medicine in Novi Sad, Novi Sad, Serbia**SUMMARY**

Introduction/Objective *Vesica ileale Padovana* is the surgical technique for reconstruction of lower urinary tract following radical cystectomy using isolated ileal segment. This operative technique requires dissection of both ureters in full length that cannot be possible in some cases. The paper is aimed to present our experience with modified surgical technique of *vesica ileale Padovana* using 40 cm of an isolated ileal segment.

Methods Ten male patients received modified ileal neobladder following radical cystectomy at our institution during the period from 2008 to 2011. The mean age of patients was 59 years (range 45–70). Median follow-up was 76 months (range 62–93). Patients were monitored cautiously for functional outcome, local recurrence, and distant progression.

Results Perioperative, early, and late postoperative mortality have not been noticed. There were only two major complications: prolonged postoperative ileus and prolonged urinary leakage requiring percutaneous nephrostomy and subsequent ureteral reimplantation due to stenosis of ureterovesical anastomosis in one patient (10%).

Average ileal neobladder capacity was 450 ml. Daytime and night continence were achieved in nine (90%) and seven (70%) patients, respectively.

Conclusion This modification of orthotopic ileal neobladder has not been difficult to perform in our hands. Modified technique provides a clear advantage in easier ureteral implantation more proximally than in the original technique, requiring less length of ureters. Initial encouraging results should be confirmed in further clinical practice.

Keywords: adult; male; urinary bladder neoplasms; cystectomy; urinary diversion; reconstructive surgery

**INTRODUCTION**

Radical cystectomy with urinary diversion is the gold standard in the treatment of patients having non-metastatic muscle invasive bladder cancer (T2-4a, N0-x, M0). Radical cystectomy is also indicated in patients with recurrent, BCG-refractory, high-risk superficial tumors, as well as in those with primary unresectable superficial tumors [1]. Urinary diversions can be classified as heterotopic and orthotopic. In heterotopic urinary diversions, urine is derived through urostomy, which can be incontinent, such as ureterocutaneostomy and ileal conduit, or continent, such as Indiana pouch and Kock pouch. In orthotopic urinary diversions, urine is derived through the urethra. A plentitude of orthotopic bladder substitutes following radical cystectomy have been reported in the literature [2, 3]. These procedures are attractive for patients requiring radical cystectomy because an avoidance of abdominal urostomy improves the patient's satisfaction with preserved body image.

Surgical technique of *vesica ileale Padovana* was originally reported by Pagano et al. [4].

This technique was created to imitate the natural bladder with implantation of the ureter in an antireflux manner. However, this technique requires careful preparation of ureters in

full length because insufficient length of ureters can pose a real obstacle to the accomplishment of this procedure. Our modification of ileal folding after funnel creation enables more proximal implantation of ureters into the neobladder.

The aim of this paper is to present our modification of this surgical technique, as well as the initial results.

METHODS

During the period from January 2001 to November 2016, 420 patients underwent radical cystectomy at our institution. Out of them, 135 patients received ileal orthotopic bladder substitution.

During the 2008–2011 period, 10 male patients with muscle-invasive bladder cancer or BCG-refractory, T1G3 recurrent bladder cancer underwent radical cystectomy with modified *vesica ileale Padovana* orthotopic bladder replacement. The patients were selected for this procedure using the following criteria: (1) preoperative pathological stage \leq pT2b; (2) absence of tumor in the prostatic urethra; (3) preserved morphology of the upper urinary tract; (4) American Society of Anesthesiologists (ASA) score \leq 3; (5) no preoperative chemotherapy nor radiotherapy.

Received • Примљено:

April 7, 2017

Accepted • Прихваћено:

July 21, 2017

Online first: August 1, 2017**Correspondence to:**

Jovo BOGDANOVIĆ
1–3 Hajduk Veljkova Street
Novi Sad 21000
Serbia
jovo.bogdanovic@mf.uns.ac.rs

Surgical technique

After pelvic lymphadenectomy and cystectomy with prostatectomy, the procedure is continued with reconstructive surgery. A 40-cm segment of ileum is isolated and detubularized (Figure 1) to create the orthotopic reservoir. The continuity of intestinal tract is re-established with a two-layer end-to-end ileal anastomosis. Only 10 cm of the distal end of the isolated ileum is used for the creation of the funnel for anastomosis with the urethra (Figure 2). The funnel is sewn by two running polyglactin 3-0 sutures as described in the original technique [4].

Further steps represent a modification of the original technique. The rest of the isolated ileal segment is folded in the form of the letter M (Figure 3). Lateral arms of the let-

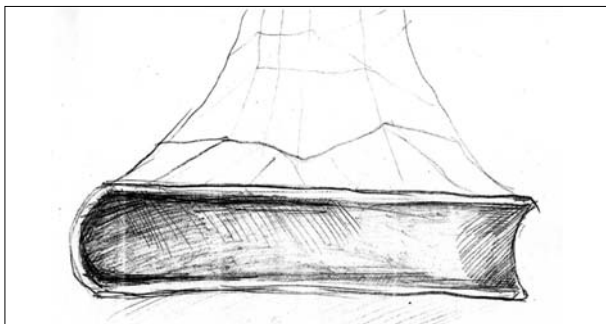


Figure 1. Detubularized isolated ileal segment in the full length

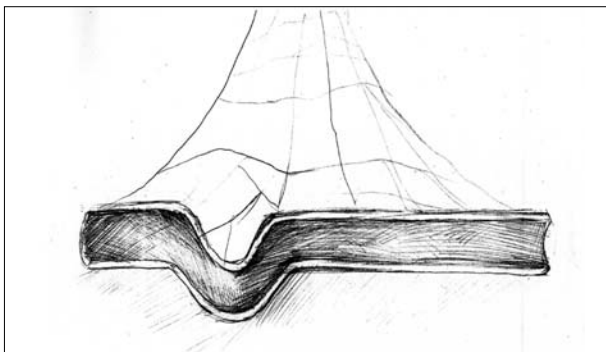


Figure 2. Preparation for the creation of the funnel outlet

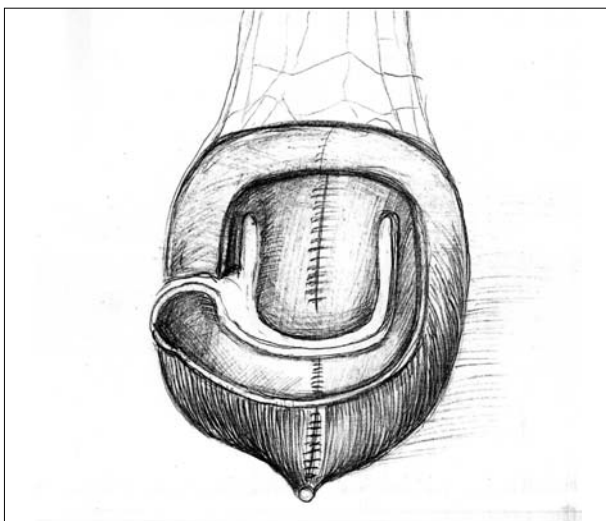


Figure 3. Creation of the "M" plane

ter M serve for the creation of an extraluminal serosa-lined tunnel for the insertion of the ipsilateral ureter (Figure 4). The left ureter has to be carefully pulled through the mesenterium of the neobladder, taking care to avoid injury to mesenteric vessels. Both ureters are spatulated on the anterior side in the length of 12–15 mm and sutured in the lateral serosal tunnel by six to eight interrupted polyglactin 3-0 stitches. Both ureteral anastomoses are protected by ureteral catheter 6 to 8 Fr. Migration of the ureteral catheters is prevented by fixation to the ureteral wall with rapidly absorbable 4-0 polyglactin suture, taking care not to damage ureteral blood supply. Following anastomosis of the ureter with the neobladder, the serosal tunnel is closed over ureter using polyglactin 3-0 running suture (Figure 4).

Finally, the "M" plane is folded anteriorly to create an anterior wall of the neobladder and sutured to the anterior side of the previously formed funnel using seromuscular running suture with polyglactin 3-0 (Figure 5). Before

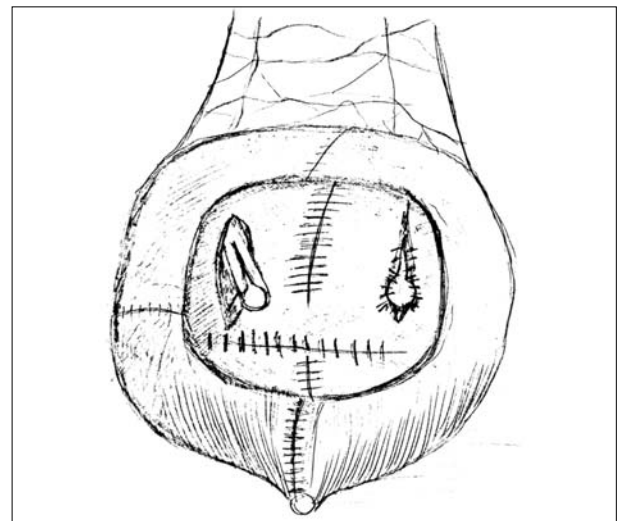


Figure 4. The posterior wall is created with serous-lined extramural tunnels and both ureters are indwelled into the neobladder; in the next step, the ureters have to be spatulated on the anterior side, splinted, and anastomosed to the neobladder; thereafter, serous-lined tunnels are closed over the ureters

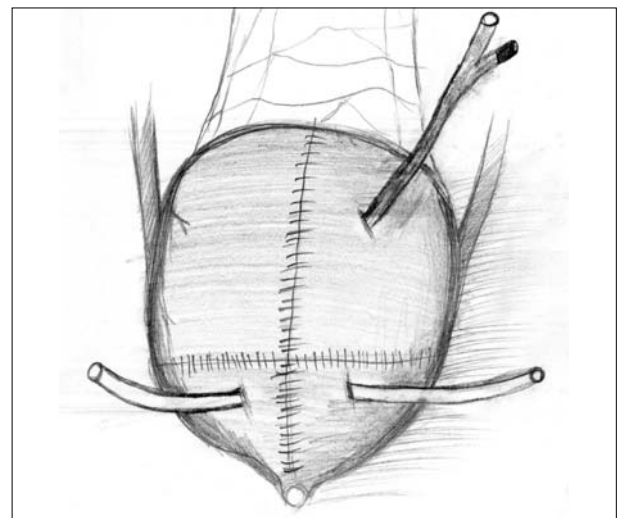


Figure 5. The final aspect of the neobladder following the closure of the anterior wall with cystostomy catheter and ureteral splints

completing reservoir closure, ureteral catheters are passed through the anterior wall of neobladder. In addition, 12 Fr two-way Foley catheter is placed for suprapubic cystoscopy. Neobladder-urethral anastomosis is created with six interrupted polyglactin stitches over 18 Fr three channel Foley catheter.

Follow-up

In all the patients, scheduled follow-up visits were performed every three months during the first year, every four months during the second year, twice per year until the fifth year, and thereafter once per year. Upper urinary tract status was assessed using intravenous pyelogram or computed tomography urography six months and two years after surgery. Routine laboratory analyses including sedimentation rate, white blood cell count, red blood cell count, blood urea nitrogen, creatinine, liver function tests and urine were performed for each patient on every visit. In addition, ultrasound of the upper abdomen and chest X-ray were performed on all the patients on every visit. Uroflowmetry was performed at their six months visit, and urodynamic study at 12 months after the surgery. Daytime and nighttime continence were assessed by interviewing each patient during the follow-up visits.

RESULTS

Seven male patients with muscle invasive bladder cancer and three male patients with recurrent BCG-refractory T1G3 bladder cancer underwent radical cystectomy and orthotopic ileal neobladder using described modified technique. The patients were aged 59 years on average, the age range being 45–70 years. Bladder-confined disease (< pT3a) without lymph node metastases (pN0) was confirmed in all the patients by histopathological examination of the surgical specimen. There was no perioperative, early, or late postoperative mortality.

There were only two major complications: prolonged postoperative ileus and prolonged urinary leakage requiring percutaneous nephrostomy and subsequent ureteral reimplantation due to stenosis of uretero-neobladder anastomosis in one patient. There were no significant metabolic disorders.

Uroflowmetry at the six-month follow-up visit has shown $Q_{max} = 20.3$ ml/s on average, ranging 10–31 ml/s. Observed curves have not been interrupted, although they were more or less undulated. Postvoiding residual urine was 13 ml on average, ranging 0–90 ml. The mean capacity of the neobladder is 450 ml, ranging 350–600 ml. All the patients had satisfying bladder compliance and no patient had spontaneous neobladder contractions or pressure over 15 cmH₂O during the filling phase.

Daytime and nighttime continence were achieved in nine (90%) and seven (70%) patients, respectively.

DISCUSSION

Orthotopic bladder substitution is probably the most complex reconstructive procedure in uro-oncological surgery. The original technique of vesica ileale Padovana was described in 1990 [4]. This neobladder seems to resemble the natural bladder the most. Unfortunately, the technique has not become widely popular among the urologists due to several reasons. First, a preparation of full length of both ureters is required to perform their implantation correctly. Second, some authors have reported that funnel-shaped neobladders were disposed to emptying difficulties [5]. Finally, creating vesica ileale Padovana seems to be complicated for the majority of urologists.

On the other hand, widely accepted neobladders, such as Studer or Hautmann, require approximately 60 cm of ileum for the creation of the reservoir. Aleksić et al. [6] found that higher capacity neobladders were associated with higher postvoiding residual volume as well as higher reabsorption of urine. In addition, these orthotopic bladder substitutes are associated with a higher probability of malabsorption syndrome due to the use of the longer segment of terminal ileum.

Vesica ileale Padovana is a spheroidal reservoir that ensures optimal volume-to-surface ratio. In addition, this type of neobladder provides low end-filling pressure. Implantation of ureters using serous-lined extramural tunnel technique originally described by Abol-Enein and Ghoneim [7] provides excellent antireflux mechanism. However, ureters sometimes do not have sufficient length for the creation of tension-free uretero-neobladder anastomosis. Therefore, we suggest this modification, using different ileal folding to achieve serous-lined extramural tunnel more proximally than in the original technique. This modification also enables the creation of a shorter funnel-shaped outlet of the neobladder, diminishing long-term problems with bladder emptying.

Average neobladder capacity in the study was 450 ml at 12 months after surgery. Yadav et al. [8] reported an increase of the neobladder capacity up to three years after surgery. They created modified ileal neobladder using 45 centimeters of ileum and reported bladder capacity of 410 ml, 502 ml, and 588 ml at one, two, and three years after surgery, respectively.

The average Q_{max} was 20.3 ml/s with a range of 10–31 ml/s. The vast majority of studies have similar flow rates. However, the neobladder does not have significant contractions. Urinary flow rate depends on the driving force (straining of abdominal muscles or Crede's maneuver), as well as on the relaxation of the urethral sphincter. Therefore, patients with neobladder usually have undulated shapes on the uroflowmetric curve.

One patient with advanced age in the study lost daytime continence three years after surgery probably due to decreased tonus of the urethral sphincter. The nighttime leakage of urine was persistent during the follow-up period in three (30%) patients. However, an expert panel at the consensus conference, convened by the World Health Organization and the Société Internationale d'Urologie,

has found a 20–30% prevalence of nighttime incontinence in most of the reported series [9]. Detubularization of the isolated ileal segment is the key maneuver leading to the low-pressure reservoir. All neobladders have a good compliance due to characteristics of the bowel, and pressures over 15 cmH₂O have not been recorded during the filling phase of cystometry.

CONCLUSION

In our experience, this modification of vesica ileale Padovana neobladder is not difficult to perform. In our opinion,

this technique provides a clear advantage in easier ureteral implantation, more proximally than in the original technique, requiring less length of the ureter. Initial encouraging results should be confirmed in further clinical practice.

ACKNOWLEDGEMENTS

The authors are thankful to Mr. Vidoje Tucović for his technical assistance with drawings, as well as to Mr. Igor Baić for his help in improving the writing style of the manuscript.

REFERENCES

1. Witjes AJ, Le Bret T, Compérat EM, Cowan NC, De Santis M, Bruins HM, et al. Updated 2016 EAU Guidelines on Muscle-invasive and Metastatic Bladder Cancer. *Eur Urol.* 2017; 71(3):462–75.
2. Hautmann RE, Abol-Enein H, Lee CT, Mansson W, Mills RD, Penson DF, et al. Urinary diversion: how experts divert. *Urology.* 2015; 85(1):233–8.
3. Nagele U, Sievert KD, Merseburger AS, Anastasiadis AG, Stenzl A. Urinary diversion following cystectomy. *European Association of Urology Update Series* 3. 2005; 129–37.
4. Pagano F, Artibani W, Ligato P, Piazza R, Garbeglio A, Passerini G. Vesica ileale Padovana: a technique for total bladder replacement. *Eur Urol.* 1990; 17(2):149–54.
5. Studer UE, Burkhard FC, Schumacher M, Kessler TM, Thoeny H, Fleischmann A, et al. Twenty years experience with an ileal orthotopic low pressure bladder substitute – lessons to be learned. *J Urol.* 2006; 176(1):161–6.
6. Aleksic P, Bancevic V, Milovic N, Kosevic B, Stamenkovic DM, Karanikolas M, et al. Short ileal segment for orthotopic neobladder: a feasibility study. *Int J Urol.* 2010; 17(19):768–73.
7. Abol-Enein H, Ghoneim MA. Functional results of orthotopic ileal neobladder with serous-lined extramural ureteral reimplantation: experience with 450 patients. *J Urol.* 2001; 165(5):1427–32.
8. Yadav SS, Gangkav G, Mathur R, Yadav RG, Tomar V. Long-Term Functional, Urodynamic, And Metabolic Outcome Of A Modified Orthotopic Neobladder Created With A Short Ileal Segment: Our 5-Year Experience. *Urology.* 2016; 94:167–72.
9. World Health Organization (WHO) Consensus Conference on Bladder Cancer, Hautmann RE, Abol-Enein H, Hafez K, Haro I, Mansson W, Mills RD, et al. Urinary Diversion. *Urology.* 2007; 69(Suppl 1):17–49.

Модификована ортотопска илеална необешика – хируршка техника и почетни резултати

Вук Секулић^{1,2}, Јово Богдановић^{1,2}, Јасенко Ђозић^{1,2}, Ранко Херин¹, Димитрије Јеремић^{1,2}

¹Клинички центар Војводине, Клиника за урологију, Нови Сад, Србија;

²Универзитет у Новом Саду, Медицински факултет у Новом Саду, Нови Сад, Србија

САЖЕТАК

Увод/Циљ *Vesica ileale Padovana* је један од начина реконструкције доњег уринарног тракта после радикалне цистектомије коришћењем изолованог сегмента илеума. Оперативна техника захтева препарацију оба уретера читавом дужином, што није могуће код свих болесника.

Циљ рада је да се прикажу наша модификација оперативне технике *Vesica ileale Padovana* употребом изолованог сегмента илеума дужине 40 cm и иницијални резултати њене примене.

Материјал и методе У периоду 2008–2011. године код 10 болесника је урађена радикална цистектомија са деривацијом урина модификованом техником *Vesica ileale Padovana*. Просечна старост болесника била је 59 година (45–70). Просечно време праћења било је 76 месеци (62–93), а посматрани су функционални и онколошки резултати.

Резултати Периоперативни, рани и касни постоперативни морталитет нису забележени. Биле су само две компликације: протраховани динамски илеус и цурење урина на уретеронеобешичној анастомози која је захтевала перкутану нефростому са накнадном реимплантацијом уретера ради стенозе, код једног болесника. Просечан капацитет необешике био је 450 ml. Дневна и ноћна континенција су постигнуте код 9 (90%), тј. 7 (70%) болесника.

Закључак Модификовану технику илеумске необешике није тешко извести, а пружа значајну предност због једноставније анастомозе уретера и необешике која се налази нешто проксималније у односу на оригиналну технику. Охрабрујући иницијални резултати треба даље да се потврде у клиничкој пракси.

Кључне речи: неоплазме мокраћне бешике; цистектомија; деривације урина; реконструктивна хирургија