

## CASE REPORT / ПРИКАЗ БОЛЕСНИКА

# Surgical treatment of a cranio-facial dermoid cyst

Nenad Živkovic, Vuk Aleksić

Zemun Clinical-Hospital Center, Department of Neurosurgery, Belgrade, Serbia

**SUMMARY****Introduction** Intracranial extension is rarely seen with craniofacial dermoid cysts, with few cases reported in the literature.**Case outline** We report a case of a 30-year-old woman who initially presented with a subcutaneous mass of the frontotemporal region. The patient underwent a right craniectomy by a frontal approach. Histopathologic analysis confirmed the diagnosis of a dermoid cyst.**Conclusion** Craniofacial dermoid cysts may be associated with an intracranial extension.**Keywords:** dermoid cyst; congenital tumor; frontotemporal region; intracranial extension**INTRODUCTION**

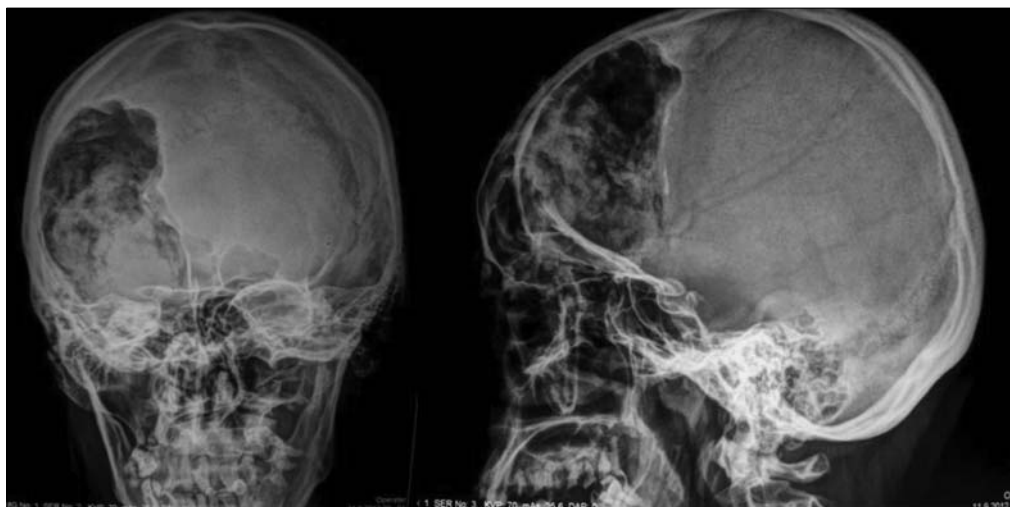Craniofacial dermoid cysts are presented as solitary, slow-growing, subcutaneous masses [1–4]. During congenital development they result from sequestration of epidermal and dermal cells and consist of epithelium-lined cysts with skin appendages. Dermoid cysts are associated with mature adnexal structures (hair follicles, sebaceous and eccrine glands) and this differentiates them from epidermoid cysts. They are visible at birth or in childhood as a slow-growing, subcutaneous mass, which can sometimes become inflamed or infected [5]. Rarely, dermoid cysts of the frontotemporal region may be associated with an intracranial extension [4, 5].

We report an unusual case of a 30-year-old female patient with a fronto-temporal dermoid cyst presenting as a massive subcutaneous mass associated with intracranial involvement.

**CASE REPORT**

A 30-year-old female patient was admitted to our department of neurosurgery with severe headaches and a loss of eyesight on the right side. She had a history of more than 12 years of a slowly progressing mass in the right frontal region. A neurologic clinical examination revealed right sided supraorbital subcutaneous mass with exophthalmos resulting in diplopia and reduced visual acuity. There was no organic problem in her medical history and there was no family history of oncologic diseases. Routine hematological and biochemical parameters were normal. The patient denied any kind of trauma to this region.

A routine X-ray of the skull was made and lesion of the frontal bone was detected (Figure 1). A magnetic resonance imaging (MRI) brain scan showed an enhancing extradural lytic bone lesion of  $6.16 \times 7.21$  cm in size, well-defined hyperdense, on T2-weighted image, mass lesion in the right frontal lobe without perilesional edema (Figure 2). Preoperative cerebral



**Figure 1.** Skull X-ray showing extradural lytic bone lesion.

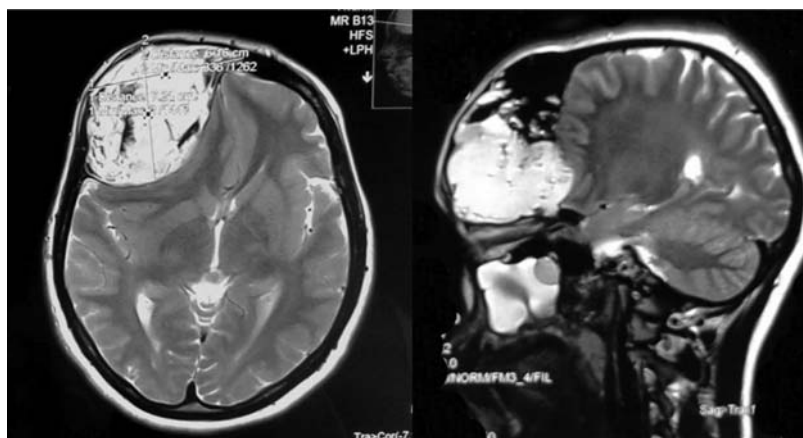
**Received • Примљено:**  
December 20, 2016

**Accepted • Прихваћено:**  
May 23, 2017

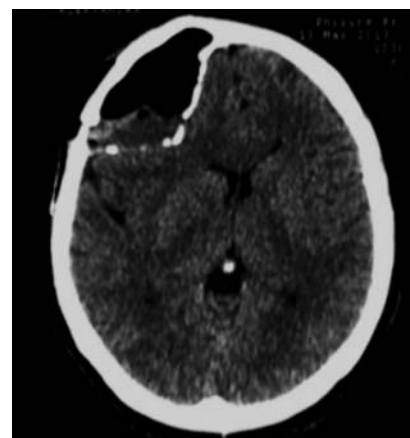
**Online first:** May 30, 2017

**Correspondence to:**

Nenad ŽIVKOVIĆ  
Vukova 9  
11000 Belgrade  
Serbia  
[drnzivkovic@yahoo.com](mailto:drnzivkovic@yahoo.com)



**Figure 2.** MR image showing a well-circumscribed, heterogeneous and fat-density mass involving the right frontal wall



**Figure 3.** MR image six months after cranioplasty showing no recurrence of the dermoid cyst

angiography was undertaken to check the blood supply of the mass and eliminate vascular anomalies: abnormalities were not observed. No further neuroradiological examination was needed because the present finding clearly showed an extracerebral mass with frontal bone erosion.

Complete removal of the lesion was carried out through a right frontal craniectomy under general anesthesia. A curved incision was performed in the frontal region of the scalp and a large cyst was found to have created a cavity in the frontal bone and intracranially. The dura was intact. The cyst was yellow, containing dirty brown, grumous, oily material. Hair and other dermal elements were observed.

Microscopic examination revealed a cystic lesion of the dermoid type. Histologic examination showed a keratinized stratified squamous epithelial lining, associated with mature adnexal structures (hair follicles and shafts, sebaceous and eccrine glands).

The patient was then referred to our maxillofacial unit for treatment. We performed a second operation together with a maxillofacial specialist. We performed a reconstruction of the bone deficit with cranioplasty and a reconstruction of the frontal sinus (Figure 3).

Postoperative recovery was uneventful, and the patient was discharged 10 days after the second surgery. In the early postoperative period, improvement was evident. During the following six months after the surgery there was no evidence of tumour recurrence.

## DISCUSSION

Dermoid cysts are benign soft tissue cysts of embryonic origin that arise along the lines of skin fusion. During congenital development they result from sequestration of epidermal and dermal cells and consist of epithelium-lined cysts with skin appendages (hair follicles, sebaceous and eccrine glands). They are described as “oil cysts” by Hirschberg [6], and they represent a common mass of the orbitofacial region in the pediatric population. Very rarely they can be found in adults, as slow-growing subcutaneous masses of the head and face region. Our case presents a 30-year-old woman who initially presented a subcutaneous

mass of the frontotemporal region, which revealed an intracranial dermoid cyst, so we emphasize that a dermoid cyst should be included in the differential diagnosis of all nodular cyst-like lesions in the head and face region.

In 1993, Bartlett et al. [7] proposed a topographic dermoid segregation into three groups: frontotemporal, orbital, and nasolabellar. The algorithm was based on the potential extension of the lesions to the contiguous structures (meninges, orbital soft tissues, skin). According to Bartlett et al. [7], frontotemporal and orbital dermoids with definable margins are superficial, slow-growing masses that can be excised, without an extensive radiologic diagnostic workup. However, orbital dermoid cysts required a thin-section MRI because of their propensity to extend beyond the bone (into the orbit, intracranially). In contrast to this research and other data we were able to find, intracranial involvement very rarely occurs with frontotemporal dermoids and there are only several cases of it [7, 8, 9]. This is more common with midline nasal and scalp cysts [7, 8, 9].

Our case represents frontotemporal dermoid in a 30-year-old adult with intracranial extension and close contact with meninges and orbital soft tissues which caused exophthalmus resulting in diplopia and reduced visual acuity.

The diagnosis of dermoid cyst was suggested by imaging (skull radiographs, CT scan, MRI) and confirmed by histology. MRI scan allows for good assessment of both skull involvement and intracranial extension and reveals the exact site, limits, and characteristic bone defects of these lesions. Differential diagnosis should include epidermoid cyst, hydatid cyst, cholesterol granuloma, eosinophilic granuloma, and meningioma [10]. It is particularly common to misdiagnose a dermoid cyst as an epidermoid cyst, as the difference between them is mainly histological. The definite diagnosis can be achieved by surgical removal and histopathological confirmation.

The indications for surgery include cosmetic effect, prevention of progression of psychiatric symptoms and neurological deficit, treatment of osteomyelitis, and resection of cysts with malignant degeneration [11, 12]. Most cranial dermoids are small and do not extend intracranially, but progressive growth may result in large

cranial defects or compression of the brain and vascular structures [5, 6]. There are two considerations about surgical treatment of dermoid cysts. The first concern is the recurrence and potential for malignant transformation, which results from an incomplete excision, especially when a long-standing dermoid cyst extends deeply intracranially. The second concern are the possible complications, including inflammation, osteomyelitis, meningitis, and cerebral abscess.

Removal of these tumors and subsequent cranioplasty, despite their large size, are recommended, particularly for very large dermoid cysts associated with significant bony defects [11]. Total removal of these cysts is associated with a very good long-term prognosis [8, 9]. Recurrence is likely if the cyst wall is not completely removed, with a recurrence rate of 8–25% and potential malignant transformation [5, 11, 12]. In our patient, we were able to remove the cyst and capsule completely with combined intracranial–extracranial approach proposed by Sessions [13]. Repeated washing of the cavity with

0.9% saline prevented aseptic meningitis and recurrence. A postoperative antibiotic regimen was implemented to prevent infection.

The orbitofacial dermoid typically presents as a slow-growing, non-fixed, asymptomatic mass. These features may not be apparent in intracranial situated lesions. It is important to be aware that the subcutaneous mass of the face and head region may represent the “tip of the iceberg” of a deep dermoid cyst. For this reason, early recognition and accurate diagnosis by means of CT scan or MRI facilitate successful treatment.

Although rare, all nodular cysts-like lesions in the head and neck (orbitofacial) region, in adults, should be included in the differential diagnosis of dermoid cysts. Failure to recognize and treat these lesions may lead to a progressive neurological deficit, bone distortion, or recurrent infections with severe complications such as meningitis or cerebral abscess. For this reason, early clinical recognition and diagnostic procedures like CT scan or MRI facilitate successful treatment.

## REFERENCES

- Gordon PE, Faquin WC, Lahey E, Kaban LB. Floor-of-Mouth Dermoid Cysts: Report of 3 Variants and a Suggested Change in Terminology. *J Oral Maxillofac Surg.* 2013; 71(6):1034–41.
- Hachach-Haram N, Benyon S, Shanmugarajah K, Kirkpatrick NW. Back to basics: A case series of angular dermoid cyst excision. *J Plast Reconstr Aesthet Surg.* 2013; 66(1):57–60.
- Golden BA, Jaskolka MS, Ruiz RL. Craniofacial and Orbital Dermoids in Children. *Oral Maxillofac Surg Clin North Am.* 2012; 24(3):417–25.
- Sillifant P, Duncan C. Dermoid cysts in the craniofacial region: the Liverpool experience. *British Journal of Oral and Maxillofacial Surgery.* 2011; 49:S101–2.
- Reissis D, Pfaff MJ, Patel A, Steinbacher DM. Craniofacial dermoid cysts: histological analysis and inter-site comparison. *Yale J Biol Med.* 2014; 87(3):349–57.
- Hirschberg J. Oil cyst of orbit. *Arch Ophthalmic.* 1879; 8:373–5.
- Bartlett SP, Lin KY, Grossman R, Katowitz J. The surgical management of orbitofacial dermoids in the pediatric patient. *Plast Reconstr Surg.* 1993; 91(7):1208–15.
- Steele MH, Suskind DL, Moses M, Kluka E, Liu DC. Orbitofacial masses in children: an endoscopic approach. *Arch Otolaryngol Head Neck Surg.* 2002; 128(4):409–13.
- Hong SW. Deep frontotemporal dermoid cyst presenting as a discharging sinus: a case report and review of literature. *Br J Plast Surg.* 1998; 51(3):255–7.
- Živković N, Marković M, Mihajlović G, Jovanović M. Surgical Treatment of Intradiploic Epidermoid Cyst Treated as Depression. *Srp Arh Celok Lek.* 2014; 142(1-2):67–71.
- Ayhan A, Tuncer ZS, Bilgin F, Kucukali T. Squamous cell carcinoma arising in dermoid cyst. *Eur J Gynaecol Oncol.* 1996; 17(2):144–7.
- Stephenson GC, Ironside JW. Squamous cell carcinoma arising in a subcutaneous dermoid cyst. *Postgrad Med J.* 1991; 67(783):84–6.
- Sessions RB. Nasal dermal sinuses—new concepts and explanations. *Laryngoscope.* 1982; 92:1–28.

## Хирушко лечење кранио-фацијалне дермоидне цисте

Ненад Живковић, Вук Алексић

Клиничко-болнички центар Земун, Одељење неурохирургије, Београд, Србија

### САЖЕТАК

**Увод** Интракранијална екстензија је ретко виђена код краниофацијалних дермоидних циста, са неколико случајева пријављених у литератури.

**Приказ болесника** Код 30-годишње жене првобитно је уочена субкутана маса фронтотемпоралног региона. Урађена

је краниотомија фронталним приступом. Хистопатолошка анализа потврдила је дијагнозу дермоидне цисте.

**Закључак** Краниофацијална дермоидна циста може бити повезана са интракранијалним ширењем.

**Кључне речи:** дермоидна циста; урођен тумор; фронтотемпорална област; интракранијално ширење