

CASE REPORT / ПРИКАЗ БОЛЕСНИКА

Subacute liver failure of unknown origin

Dragan Delić^{1,2}, Nikola Mitrović², Aleksandar Urošević^{1,2}, Jasmina Simonović^{1,2}, Ksenija Bojović^{1,2}¹University of Belgrade, Faculty of Medicine, Belgrade, Serbia;²Clinical Center of Serbia, Clinic for Infectious and Tropical Diseases, Belgrade, Serbia**SUMMARY****Introduction** Acute liver failure is a rare and very complex clinical syndrome, a consequence of sudden and severe liver dysfunction. There are several causes of this condition (viruses, medications, toxins, metabolic, autoimmune and malignant diseases), but etiological agent often remains undiscovered.**Case outline** A 40-year-old male patient had suddenly taken ill with signs and symptoms of acute hepatitis, which was confirmed through biochemical analyses. The cause of acute liver failure was not determined. Despite all therapeutic measures, the clinical course of the disease was unfavorable: severe icterus, decreased synthetic function of the liver and hepatic encephalopathy developed. In the later, subacute course of the disease, ascites and episodes of hepatic encephalopathy developed, and biochemical findings indicated chronic hepatocellular failure. After three months of treatment in hepatic coma there was lethal outcome. Histopathological findings confirmed the diagnosis of decompensated liver cirrhosis of unknown origin.**Conclusion** The cause of acute liver failure often remains unclear; potential causes should be looked for in infections by unknown viruses or in exposures to toxins. The disease is most commonly presented as a subacute failure with the development of liver cirrhosis. Survival rate is low.**Keywords:** subacute liver failure; acute hepatitis non A-E; liver cirrhosis; hepatic encephalopathy**INTRODUCTION**

Acute liver failure (ALF) is a complex clinical syndrome which develops as a consequence of massive or submassive hepatic cell necrosis, with a development of hepatic encephalopathy (HE) and a severe disturbance in liver functions. It is usually fatal (in 60–90%), most often within the first week of the disease [1]. Since there are several etiological factors, with different clinical course and outcome of the disease and many complications, different authors give diverse classifications of ALF [2, 3]. The researches of King's College Hospital, based on experience with 558 patients with ALF and 47 patient with later-developed liver failure, gave a new classification of ALF. Their suggestion is that ALF should be used as a frame term, which should be predetermined with prefixes hyper- or sub-, which would be two extremes of this clinical syndrome. The term 'hyperacute liver failure' relates to patients who develop encephalopathy within seven days after the onset of jaundice. This group of patients has significant survival rate (around 40%) with the use of usual medications. For patients who develop encephalopathy eight to 28 days after the appearance of jaundice the term 'acute liver failure' is used. These patients have extremely low survival rate (7%). For patients in whom encephalopathy develops after four weeks (29–84 days after the appearance of jaundice) the term 'subacute liver failure' should be used. Survival rate for the last group is low, about 14%. The most common etiological factor was acute hepatitis non-A, non-B, making 83% of all cases [4]. Adopting

this terminology allowed for standardized approach and interpretation of controlled clinical studies, and also for the application of new therapeutical methods, including bioartificial liver support and liver transplantation.

In addition to time elapsing between the appearance of jaundice and encephalopathy, other prognostic factors of outcome of ALF were discovered, such as the level of serum bilirubin, ammonemia, international normalized ratio (INR), thyroid status, etc. By combining these factors different prognostic models were made in order to predict mortality, and to timely indicate the need for liver transplantation, the only remaining therapeutic option [5]. This is especially important for ALF of unknown origin since there is no specific therapy.

CASE REPORT

A 40-year-old male patient from Belgrade, married, with two children, was admitted to the Clinic for Infectious and Tropical Disease in Belgrade, Clinical Centre of Serbia, due to nausea, loss of appetite, aversion to food, dark urine, and yellowing of the eyes. The disease started 10 days before his admission to the hospital. Epidemiological data excluded the possibility of liver infection by primary and potentially hepatotropic viruses, and acute toxic liver failure (caused by alcohol, medications, herbs, different supplements, etc.). At admission, the patient was afebrile, had jaundice, the liver was palpable 2 cm below the right rib cage, and there were no signs of HE. Biochemical

Received • Примљено:
March 29, 2017Revised • Ревизија:
May 29, 2017Accepted • Прихваћено:
May 30, 2017

Online first: June 6, 2017

Correspondence to:Dragan DELIĆ
Bulevar Oslobođenja 16,
11000 Belgrade
Serbia
delic_co@neobee.net

analysis suggested acute hepatitis without hepatocellular insufficiency: aspartate aminotransferase (AST) 1,249 U/L, alanine aminotransferase (ALT) 2,907 U/L, total-val-ue bilirubin (TBil) 393 $\mu\text{mol/L}$, direct bilirubin (DBil) 169 $\mu\text{mol/L}$, gamma-glutamyl transferase 194 U/L, alkaline phosphatase 115 U/L, prothrombin time (PT) 62.3%, INR 1.3. Hematological analyses were normal. Virological tests excluded hepatitis B virus (HBV) infection (HBsAg, anti-HBc IgM, and HBV DNA were negative), hepatitis C virus (HCV) infection (anti-HCV and HCV RNA were negative), hepatitis A virus (HAV) infection (anti-HAV IgM was negative), hepatitis E virus (HEV) infection (anti-HEV IgM negative), as well as the Epstein-Barr virus, cytomegalovirus, adenovirus, herpes simplex virus, and West Nile virus infection (IgM-class antibodies were negative measured by ELISA). Autoimmune liver disease, Wilson disease and hemochromatosis were excluded as well. A several-fold increase of the levels of alpha-fetoprotein (AFP) – 659 ng/L – was pointing to the regenerative potential of the liver. Ultrasound examination of the abdomen excluded the obstruction of the bile ducts, even though a gallstone of 1 cm in diameter was detected in the gallbladder. Thrombosis of the hepatic veins was excluded as well. A hematologist excluded hematology disease with possible liver infiltration.

In the further course of the disease, fatigue and loss of appetite continued, with an increase in serum transaminases (AST 3,113 U/L; ALT 4,957 U/L), jaundice (TBil 655 $\mu\text{mol/L}$; DBil 256 $\mu\text{mol/L}$) and a gradual fall of the liver synthetic function (albumin level 31 g/L; PT 46%; INR 1.61; AFP 129 ng/L). Since there was progressive liver failure with threatening hepatocellular insufficiency, prednisone and 20% human albumins were included in the therapy. In the further course there was no positive therapeutic response; hence, on the 30th day of the treatment the patient fulfilled the criteria for ALF – PT 40%, INR 1.81. Three days later, the flapping tremor (asterixis) appeared as a sign of the second phase of HE. Lactulosis, L-ornithine-L-aspartate (LOLA) and fresh frozen human plasma were added to the preceding therapy. In the further course of the disease the patient had episodes of HE with severe jaundice (TBil around 500 $\mu\text{mol/L}$), low AFP (17.5 ng/L), and hepatocellular insufficiency (PT 36%, INR 2.01). At the end of two months of treatment, for the first time, abdominal ultrasound verified inhomogeneous liver parenchyma, splenomegaly (12.5 cm) and some ascites in the abdomen. Our conclusion was that our patient had subacute liver failure with cirrhotic transformation. The patient was put on the transplant waiting list.

Further course of the disease corresponded to decompensated liver cirrhosis with HE. Biochemical analysis showed inversion of transaminases activity (AST 302 U/L; ALT 281 U/L), hyperbilirubinemia (TBil up to 639 $\mu\text{mol/L}$), hepatocellular insufficiency (albumin level 30 g/l, PT 27%, INR 2.28), and hyperammonemia (177 nmol/L). Magnetic resonance imaging scan of the abdomen and magnetic resonance cholangiopancreatography was performed – cirrhotic liver and multiple nodular lesions with atypical magnetic resonance imaging

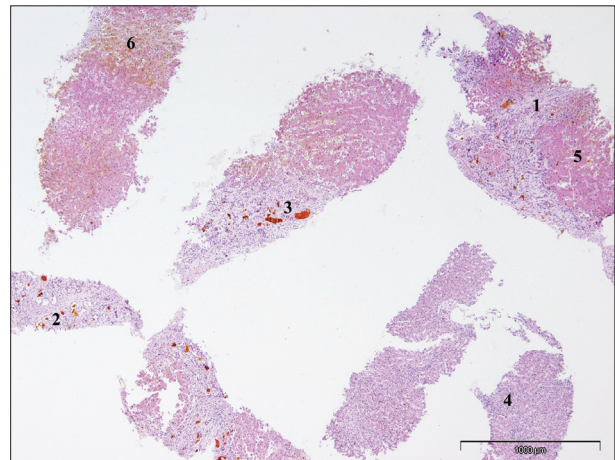


Figure 1. Postnecrotic cirrhosis with signs of liver insufficiency; fibrosis septa are seen around parenchymal nodules (1); there is proliferation of biliary ductules (2); bile stasis is seen in some of the dilated ducts (3); inflammatory infiltrates are scant (4); the parenchyma shows a nodular appearance (5); there are cellular and canalicular cholestasis (6); some hepatocytes show ischemic change

characteristics were found. Free fluid in the abdomen, portal hypertension, and a gallstone were also observed.

After three months of treatment the patient's disorder of consciousness deepened, up to the level of coma with hyperpyrexia. A lethal outcome occurred 102 days after the onset of the disease, in deep coma. Necropsy of the liver was performed and a cylindrical sample of 3.5 cm in diameter was obtained. The architecture of the liver was damaged in the cirrhotic manner. Cholestasis was severe and there were large zones of ischemic necrosis of hepatocytes. Iron staining results were negative, as well as copper-associated protein staining. There was no tumor tissue of hepatocellular carcinoma (Figure 1).

DISCUSSION

ALF with multiple organ dysfunctions, i.e. insufficiency, can be caused by many agents and pathological conditions: viruses, medications, toxins, alcohol, congenital metabolism disorders, autoimmune liver disease, cardiovascular disease, leukemia, reticulosis, etc. [6]. Globally, HAV and HEV infections are the most common cause of ALF in developing countries, with the mortality rate over 50% [7]. Of the known primary hepatotropic viruses, HBV is the most common (67.8%) cause of ALF in our country [1]. Over the last several years in Western Europe and the USA, there are an increased number of occurrences of herbal products causing hepatotoxicity; cases with ALF with lethal outcome have also been reported [8]. Around 50% of ALF in the United States are caused by medications, especially acetaminophen [9].

ALF of unknown origin (undetermined cause) is registered with diverse frequency worldwide and is not dependent on epidemiological characteristics of the area – from 11% in Sweden to 38% in Sudan [10, 11]. In our previous research, undetermined cause of ALF was the second most frequent cause (12.6%), just behind HBV infection. These patients had the worst prognosis, and the mortality rate was 100%.

Clinical course of the disease was either acute or subacute liver failure [12]. Our patient had subacute course of liver failure (signs of HE appeared 33 days after jaundice) with undetermined cause – infection with known primary and potentially hepatotropic viruses were excluded, as well as occult HBV and HCV infection, autoimmune liver disease, Wilson disease and hemochromatosis. Based on a detailed anamnesis, biochemical analysis and histopathological findings, as well as regarding previous researches, this could be the case of infection by an unknown hepatotropic virus [13].

The way the hepatocytes die or, to be more precise, the amount of simultaneously died hepatocytes and intracinus localization of necrosis are at the center of today's histological classifications of acute viral hepatitis (AVH). Therefore, there are four basic histological forms of AVH: with focal necrosis, with confluent bridging necrosis, with panacinar necrosis, and with periportal necrosis [14]. The outcome of AVH with confluent bridging necrosis varies. Complete or almost complete healing can occur, by recovering of the parenchyma with rare remaining fibrosis.

REFERENCES

1. Delić D. Akutna insuficijencija jetre. Beograd: Zavod za udžbenike i nastavna sredstva; 1999.
2. Lucke B, Mallory T. Fulminant form of epidemic hepatitis. *Am J Pathol.* 1946; 22(5):867–945.
3. Bernuau J, Rueff B, Benhamou JP. Fulminant and subfulminant liver failure: definitions and causes. *Sem Liv Dis.* 1986; 6(2):97–106.
4. O'Grady J, Schalm SW, Williams R. Acute liver failure: redefining the syndromes. *Lancet.* 1993; 342(8866):273–5.
5. Kumar R, Shalimar, Sharma H, Goyal R, Kumar A, Khanal S, et al. Prospective derivation and validation of early dynamic model for predicting outcome in patients with acute liver failure. *Gut.* 2012; 61(7):1068–75.
6. Mas A, Eodes J. Fulminant hepatic failure. *Lancet.* 1997; 349(9058):1081–5.
7. Bernal W, Wendon J. Acute liver failure. *N Engl J Med.* 2013; 369(26):2525–34.
8. Stournaris E, Tziomalos K. Herbal medicine-related hepatotoxicity. *World J Hepatol.* 2015; 7(19):2189–93.
9. Reuben A, Koch DG, Lee WM, Acute Liver Failure Study Group. Drug-induced acute liver failure: results of a U.S. multicenter, prospective study. *Hepatology.* 2010; 52(6):2065–76.
10. Wei G, Bergquist A, Broome U, Lindgren S, Wallerstedt S, Almer S, et al. Acute liver failure in Sweden: etiology and outcome. *J Intern Med.* 2007; 262(3):393–401.
11. Mudawi HMY, Yousif BA. Fulminant hepatic failure in an Africa setting: etiology, clinical course, and predictors of mortality. *Dig Dis Sci.* 2007; 52(11):3266–9.
12. Urošević A. Etiologija, kliničke karakteristike, faktori prognoze i histopatološki nalaz kod bolesnika sa akutnom insuficijencijom jetre. Magistarska teza. Beograd: Medicinski fakultet; 2012.
13. Delić D, Mitrović N, Radovanović Spurnić A, Stojković Švirtlih N, Simonović Babić J. Epidemiological characteristics and clinical manifestations of acute non-A-E hepatitis. *Vojnosanit Pregl.* 2010; 67(11):903–9.
14. Scheuer PJ. Viral Hepatitis. In: MC Sween RNM, Anthony PP, Scheuer PJ, editors. *Pathology of the Liver.* Edinburg: Churchill Livingstone; 1987. p. 202–23.
15. Begić Janeva A. Patologija jetre i žučne beške i žučnih puteva. Gornji Milanovac: Dečije novine; 1991.
16. Altinbas A, Bechmann LP, Akkiz H, Gerken G, Canbay A. Acute liver failure. In: Mauss S, Rockstroh J, Wedemeyer H, Berg T, Sarrazin C, editors. *Hepatology. A clinical textbook.* Hamburg: Medizin Fokus Verlag; 2017. p. 715–29.

In some patients, lethal outcome is possible in the first 10 days of the disease with signs of ALF, or in two or three months of the disease with signs of subacute liver failure with fibrosis. In rare cases, real cirrhosis and nodular regeneration hyperplasia of the parenchyma can be found [15]. In our patient, subacute course of the disease and histopathologically proved liver cirrhosis could relate, by the course and the outcome, to acute viral hepatitis with confluent bridging necrosis. Liver transplantation is the last treatment option in patients with ALF, when conservative treatment options fail and lethal outcome is imminent [16]. Our patient was put on the transplant waiting list.

ACKNOWLEDGEMENT

The authors wish to thank Prof. Ivan Boričić, MD, from the Institute of Pathology, Belgrade, Serbia, for the histopathological picture and his description of our patient's liver tissues.

Субакутна инсуфицијенција јетре непознате етиологије

Драган Делић^{1,2}, Никола Митровић², Александар Урошевић^{1,2}, Јасмина Симоновић^{1,2}, Ксенија Бојовић^{1,2}

¹Универзитет у Београду, Медицински факултет, Београд, Србија

²Клинички центар Србије, Клиника за инфективне и тропске болести, Београд, Србија

САЖЕТАК

Увод Акутна инсуфицијенција јетре је редак и веома сложен клинички синдром, настао као последица изненадне и тешке дисфункције јетре. Узроци су бројни (вируси, лекови, токсини, метаболичке, аутоимунске и малигне болести) и врло често се не открију.

Приказ болесника Мушкарац узраста 40 година разболео се нагло са тегобама и знацима акутног хепатитиса, што је биохемијским анализама и потврђено. Узрочник акутног оштећења јетре није доказан. И поред предузетих терапијских мера, клинички ток болести је неповољан: изражен иктерус, пад синтетске функције јетре, развој хепатичке енцефалопатије. У даљем, субакутном току болести долази

до појаве асцитеса, епизода хепатичке енцефалопатије и биохемијских показатеља хроничне хепатоцелуларне инсуфицијенције. После три месеца лечења, у хепатичкој коми, долази до смртног исхода. Хистопатолошким прегледом ткива јетре потврђена је дијагноза декомпензоване цирозе јетре непознате етиологије.

Закључак Узрок акутне инсуфицијенције јетре често остаје нејасан; потенцијалне узрочнике треба тражити у инфекцијама са непознатим вирусима или у изложености токсинима. Болест се најчешће презентује као субакутна инсуфицијенција са развојем цирозе јетре. Степен преживљавања је низак.

Кључне речи: субакутна инсуфицијенција јетре; акутни хепатитис не-А-Е; цироза јетре; хепатичка енцефалопатија