

CASE REPORT / ПРИКАЗ БОЛЕСНИКА

En bloc paired cadaveric renal transplantation from an 18-month-old infant as a donor to an adult recipient – case report and literature review

Aleksandar Tomić, Ivan Marjanović, Saša Micković

University of Defence, Military Medical Academy, Clinic for Vascular and Endovascular Surgery, Belgrade, Serbia

**SUMMARY**

Introduction Even in the modern era of kidney transplantation, the use of small grafts from pediatric cadaver donors remains controversial. This kind of transplantation is rare and, to date, limited data are presented. Major problems with infant kidney transplantation are difficulties in performing vascular anastomosis, vasospasm, renal vein thrombosis, and small infant kidneys with poor venous runoff. However, en bloc infant kidney transplantation could resolve these problems.

Case outline We report on transplantation of en bloc cadaver kidneys from an 18-month-old infant. The transplant recipient was a 32-year-old male, with a body weight of 65 kg. Abdominal ultrasonography showed kidneys growing, and no hydronephrosis, perirenal, or retroperitoneal collections were seen.

Conclusion Transplantation of infantile kidneys en bloc in our adult recipient provided good results. The follow-up will show the final effect.

Keywords: kidney transplantation, methods; dual kidney transplant; pediatric kidney donor; patient selection

INTRODUCTION

Single infant kidney transplantation is technically more demanding; complications, as well as graft loss, are present more often, either due to injury at the beginning or later due to hyperfiltration [1, 2]. Transplantation of a pair of kidneys in the block constitutes a solution, and in the era of ever-increasing organ needs, it halves the number of potential recipients. Even in the modern era of kidney transplantation, the use of small grafts from pediatric cadaver donors remains controversial. This kind of transplantation is rare and, to date, limited data are presented. This was the first case of infant kidney cadaver transplantation to an adult recipient performed at our institution. We report a case of kidney transplantation from an 18-month-old infant to an adult man.

CASE REPORT

An 18-month-old male infant was diagnosed with brain death as a consequence of extreme dehydration. After parents' approval, organ procurement was planned. En bloc kidney procurement was performed, including both kidneys with segments of the aorta, inferior vena cava, and both ureters (Figure 1). Kidney perfusion was performed in situ with Euro-Collins solution (1,000 mL). Cold ischemia time was 13 hours. Kidney measurements were

5.7 × 4.2 × 1.7 cm and aortic and inferior vena cava diameter was about 10 mm.

A 32-year-old male (65 kg, 175 cm) with end-stage renal disease was chosen as the recipient, as no child with terminal kidney disease was compatible. The donor was A-positive, with 3/6 human leukocyte antigen compatibility and negative "cross-match" using complement dependent cytotoxicity. The patient was on hemodialysis for the previous four years (three times per week), with no diuresis, and his serum creatinine level was 1,052 mmol/L. Preoperative examination included abdominal ultrasonography, multislice computed tomography with pelvic angiography and intravenous urography. The operation was performed through the right Gibson incision. The kidneys were placed at both sides of the right iliac blood vessels: the left kidney in the right iliac fossa, and the right kidney below aortic bifurcation (Figure 2). End-to-side anastomosis of the infrarenal infant aorta and inferior vena cava and external iliac vessels with continuous GORE-TEX CV7 sutures (W. L. Gore & Associates, Inc., Newark, DE, USA) were performed. Suprarenal portions of the aorta and inferior vena cava were oversewn with continuous 5-0 nonabsorbable monofilament sutures. Separate anti-reflux uretero-cysto-neostomies with two J-J stents were made (Figure 3). Diuresis started after 15 minutes with good perfusion of both kidneys. In the postoperative period, diuresis was about 9 L/24 hours, and creatinine level fell to 200 mmol/L.

Received • Примљено:
May 3, 2017

Revised • Ревизија:
November 3, 2017

Accepted • Прихваћено:
November 9, 2017

Online first: November 17, 2017

Correspondence to:

Aleksandar TOMIĆ
Clinic for Vascular and
Endovascular Surgery
Military Medical Academy
Crnotravska 17, 11000 Belgrade
Serbia
tomicdoc@gmail.com

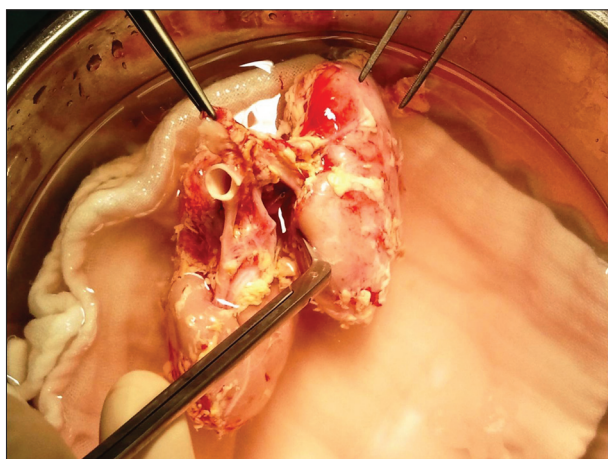


Figure 1. Preparation of the kidneys

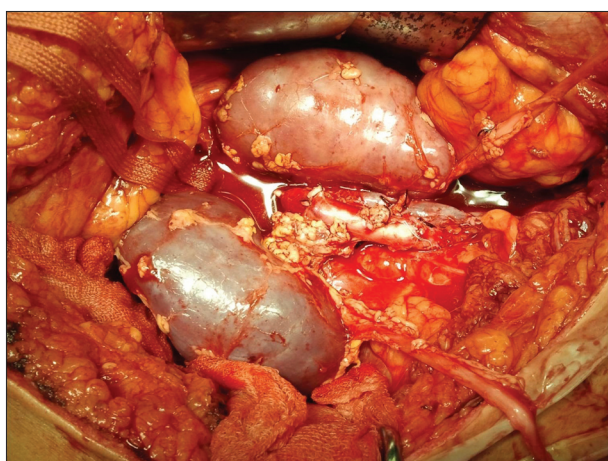

Figure 2. Sutured proximal end of the infant's aorta and the inferior vena cava; end-to-side anastomosis of the infant's inferior vena cava to the recipient's external iliac vein; end-to-side anastomosis of the infant's aorta to the recipient's external iliac artery

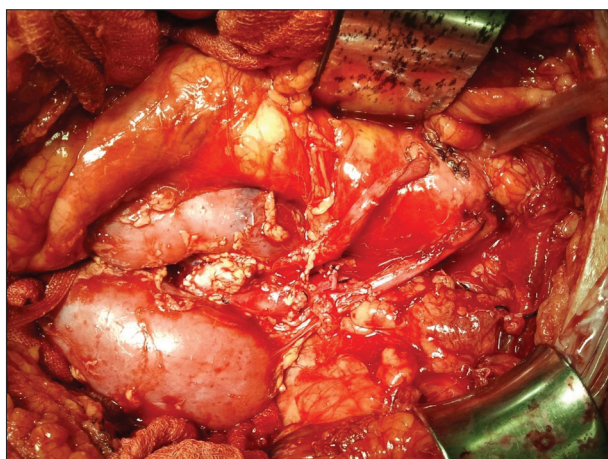

Figure 3. Separate uretero-cysto-neostomies for both ureters

Abdominal ultrasonography showed kidneys' enlargement ($8 \times 4 \times 2$ cm). Moreover, no signs of hydronephrosis, perirenal, or retroperitoneal collections were recorded. Good flow through arterial and venous anastomosis, and good perfusion of both kidneys were recorded by a color Doppler

examination. Anti-thymocyte globulin, methylprednisolone, mycophenolate mofetil, and tacrolimus were used as immunosuppressive therapy. There were no surgical complications, postoperative recovery was uneventful, and the patient was discharged on the 15th postoperative day.

DISCUSSION

Modern transplant surgery is challenged with a lack of available organs needed for transplantation. This is the main reason why marginal donors are used more frequently for organ procurement. The main characteristics of these donors are increased transplantation risks, deficiency of functional nephrons, diabetes, hypertension, and the age of over 60 years. In recent years, more infant organ donors have been accepted for kidney procurement. In 1969, a report was submitted on the first successful transplantation of a pair of kidneys from a pediatric kidney donor to an adult [3]. Different techniques are being developed; Salehipour et al. [4] explain this in their paper. Small vascular and urethral anastomoses present a technical challenge for the surgeon. Small and immature kidney vascular vessels and large and mature vessels of the recipient make vascular anastomosis technically more difficult. This problem is overcome with end-to-side anastomoses of the infrarenal donor vena cava and aorta to the recipient vessels [5]. The other method is interposition grafting of the aorta and vena cava to the recipient vessels [6]. Moreover, tiny and underdeveloped ureters and strong adult urinary bladder detrusor make uretero-cysto-neostomy very difficult. Venous thrombosis, the major complication and cause of kidney rejection was reported by García Buitrón et al. [7]. They noted that two of four en bloc renal transplants from pediatric donors aged less than one year were lost due to venous thrombosis.

Kayler et al. [8] had good results with the opposite technique, where distal parts of the infant aorta and inferior vena cava were oversewn and anastomoses were done with proximal parts of the mentioned vessels. The UCLA Renal Transplant Registry reported that a one-year graft survival rate after kidney transplantations obtained from 276 donors younger than three years was less than 54% [9]. Small infant kidneys with poor venous runoff make transplantation of one kidney to an adult insufficient. In 1967, Kelly et al. [10] showed that only one in five individual single kidneys transplanted to an adult recipient has an adequate function. Uemura et al. [11] found that kidneys from pediatric donors > 6 cm in size can be successfully transplanted as single kidneys. Sureshkumar et al. [12] suggested that pediatric donors weighing more than 10 kg were suitable for single-kidney transplantations. In some retrospective studies, it was noted that hyperfiltration remains the main problem with single infant kidney transplantations [13, 14]. Vascular hyperinfiltration injury can be reduced by dividing the blood flow into both small graft kidneys. In addition, the overall survival rate is significantly higher from paired kidneys compared to a single transplanted kidney [15]. Therefore, both kidneys were transplanted to

one recipient as en bloc transplantation. Enlargement of both kidneys after transplantation has also been noticed by other authors [14]. Another challenge for small organs is the creation of ureterocystostomy, so Lippman et al. [16] believe that poor surgical technique is a cause for urinary leakage, occurring secondary to necrotic ureter caused by inadequate blood supply [16]. However, successful transplantation of a pair of cadaveric renal kidneys aged six months with 4.75 cm in length performed by Huang et al. [13] once again demonstrates that it is possible to extend

the marginal donor limit when it relates to the size of the organs and the donor's age.

CONCLUSION

Transplantation of infantile kidneys en bloc in our adult recipient provided good results. This kind of transplantation is a good option, for it extends the number of marginal donors. The follow-up will show the final effect.

REFERENCES

- Sharma A, Fisher RA, Cotterell AH, King AL, Maluf DG, Posner MP. En bloc kidney transplantation from pediatric donors: comparable outcomes with living donor kidney transplantation. *Transplantation* 2011; 92(5):564–9.
- Beltran S, Kanter J, Plaza A, Pastor T, Gavela E, Avila A, et al. One-year follow-up of en bloc renal transplants from pediatric donors in adult recipients. *Transplant Proc*. 2010; 42(8):2841–4.
- Martin LW, Gonzalez LL, West CD, Swartz RA, Sutorius DJ. Homotransplantation of both kidneys from an anencephalic monster to a 17 pound boy with Eagle-Barret syndrome. *Surgery*. 1969; 66(3):603–7.
- Salehipour M, Bahador A, Nikeghbalian S, Kazemi K, Shamsaeifar AR, Ghaffaripour S, et al. En-bloc transplantation: an eligible technique for unilateral dual kidney transplantation. *Int J Organ Transplant Med*. 2012; 3(3):111–4.
- Nghiem DD. En bloc transplantation of kidneys from donors weighing less than 15 kg into adult recipients. *J Urol*. 1991; 145(1):14–6.
- Amante AJ, Kahan BD. En bloc transplantation of kidneys from pediatric donors. *J Urol*. 1996; 155:852.
- García Buitrón J, Rodríguez-Rivera García J, Chantada Abal V, González Martín M.. [Kidney transplant with pediatric grafts from donors under a year old. The implantation technics]. *Arch Esp Urol*. 1993; 46(9):793–7.
- Kayler L, Blisard D, Basu A, Tan HP, McCauley J, Wu C, et al. Transplantation of En Bloc Pediatric Kidneys When the Proximal Vascular Cuff Is Too Short. *Transplantation*. 2007; 83(1):104–5.
- Bretan PN, Koyloe M, Singh K, Barba L, Ward H, Sender M, et al. Improved survival of en bloc allografts from pediatric donors. *J Urol*. 1997; 157(5):1592–5.
- Kelly WD, Lillehi RC, Aust JB. Kidney transplantation: experience at the University of Minnesota Hospital. *Surgery*. 1967; 62:704.
- Uemura T, Liang J, Khan A, Kwon O, Ghahramani N, Wang Li, et al. Outcomes of transplantation of single pediatric renal allografts equal to or more than 6 cm in length. *Transplantation*. 2010; 89(6):710–3.
- Sureshkumar KK, Patel AA, Arora S, Marcus RJ. When is it reasonable to split pediatric en bloc kidneys for transplantation into two adults? *Transplant Proc*. 2010; 42(9):3521–3.
- Huang CP, Ho HC, Su CK, Ou YC, Cheng CL, Yang CR. Successful Kidney Transplantation Using Paired Cadaver Kidneys Procured From a 6-month-old Brain Death Infant. *JTUA*. 2005; 16(3):120–3.
- Modi P, Rizvi SJ, Trivedi HL. Successful en bloc transplantation of pediatric deceased donor kidneys with grade 1 injury. *Indian J Nephrol*. 2009; 19(4):167–9.
- Gruessner RWG, Matas, AJ, Lloveras G, Fryd DS, Dunn DL, Payne, WD, et al: A comparison of single and double pediatric cadaver donor kidneys for transplantation. *Clin Transplant*. 1989; 3(4):209–14.
- Lippman H, Jacoby K, McFarlin L, Nicastro C, Aaberg RJ, Banowsky L. Surgical complications in 50 adult renal transplant recipients of single kidneys from cadaveric donors aged 11 to 48 months. *Clin Transplant*. 1992; 6:350–6.

En bloc кадаверична трансплантација два бубрега са детета старости 18 месеци као даваоца на одраслог примаоца – приказ случаја и преглед литературе

Александар Томић, Иван Марјановић, Саша Мицковић

Универзитет одбране, Војномедицинска академија, Клиника за васкуларну и ендоваскуларну хирургију, Београд, Србија

САЖЕТАК

Увод И у модерној ери трансплантације бубрега, употреба малих органа са кадаверичних педијатријских давалаца остаје контроверзна. Оваква трансплантација је ретка и са мало објављених података. Главни проблеми код трансплантација са једним дечјим бубрегом су тешкоћа у креирању васкуларних анастомоза, спазам крвних судова, тромбоза реналне вене и мала величина дечјег бубрега са недовољним венским протоком. Трансплантација два дечја бубрега „у блоку“ могла би да реши ове потенцијалне проблеме.

Приказ болесника Приказујемо „у блоку“ кадаверичну трансплантацију бубрега са 18 месеци старог, мождано

мртвог дечјег даваоца. Прималац је био одрасли мушкарац старости 32 године и телесне тежине 65 kg. Контролни ултразвук трбуха је потврдио увећање оба бубрега, без присутне хидронефрозе, перианалне и ретроперитонеалне течности.

Закључак Трансплантација парних дечјих бубрега „у блоку“ на одраслог примаоца у нашем случају је дала добре резултате. Праћење ће показати коначни резултат.

Кључне речи: трансплантација бубрега, методе; трансплантација два бубрега, дете давалац бубрега; селекција болесника