

CASE REPORT / ПРИКАЗ БОЛЕСНИКА

A complication during endoscopic removal of a long esophageal foreign body in an eight-month-old girl

Zlatko Djurić, Dragoljub Živanović

University of Niš, Faculty of Medicine, Children's Hospital, Department of Gastroenterology, Niš, Serbia; University of Niš, Faculty of Medicine, Children's Hospital, Department of Surgery and Orthopedics, Niš, Serbia

**SUMMARY****Introduction** Esophageal foreign bodies can cause a wide array of acute and delayed complications.

The aim of this paper was to report a complication during endoscopic removal of a long esophageal foreign body.

Case outline An eight-month-old girl was admitted to our hospital due to an acute onset of dysphagia, drooling, and vomiting. From the result of a plain anteroposterior X-ray, the patient was found to have a long hairpin retained in her esophagus. During endoscopic removal using a polypectomy snare, the hairpin was found to be stuck in the hypopharynx. It could not be removed by moving the scope and placing the patient in different positions. Finally, the hairpin was pulled out using a pair of Magill forceps under the control of a laryngoscope.**Conclusion** The Magill forceps can be a very useful tool if a foreign body is stuck in the hypopharynx during an endoscopic removal and should be readily available in any setting where this kind of endoscopic procedure is being performed.**Keywords:** complication; esophageal; foreign body; endoscopy; removal; Magill forceps**INTRODUCTION**

Foreign body ingestion is a relatively common problem in the pediatric population. In most cases (98%), it occurs accidentally [1]. Foreign bodies most commonly found in the digestive tract are coins, batteries, magnets, and toy parts. Approximately 80–90% of ingested foreign bodies pass through the body spontaneously, while the rest (10–20%) may require a non-surgical intervention or, rarely (less than 1%), surgery [2].

Esophageal foreign bodies tend to be retained in areas of physiologic narrowing, such as the upper and lower esophageal sphincter and the level of the aortic arc. They can be more commonly found in children with anatomical defects (such as esophageal stenosis and diverticula), experience of previous surgery (such as treatment for esophageal atresia), or pre-existing disease (such as eosinophilic esophagitis) [3]. Children can be asymptomatic or can present symptoms such as the following: dysphagia, vomiting, drooling, refusal of meals, stridor, and respiratory distress. Regardless of being symptomatic or asymptomatic, these patients are prone to complications that range from negligible to life-threatening.

The aim of this paper was to report a complication during endoscopic removal of a long esophageal foreign body.

CASE REPORT

An eight-month-old girl was admitted to our hospital because of an acute onset of dysphagia, drooling, and vomiting. Her medical and family history was unremarkable. Physical examination showed signs of mild dehydration. A plain anteroposterior X-ray revealed a long hairpin in her esophagus (Figure 1). The patient was taken to the operating room for endoscopic removal of the hairpin under endotracheal general anesthesia. During a flexible esophagoscopy, after unsuccessful attempts to grasp the hairpin by an alligator grasper, it was encircled using the polypectomy snare (Figure 2) and pulled up to the hypopharynx, where it suddenly became stuck. It could not be removed either by the gentle left–right movements of the scope or by shifting the patient from the prone to the left and right lateral positions. Finally, the anesthesiologist grasped and pulled the seven-centimeter-long pin out using Magill forceps under the control of a laryngoscope. Second-look esophagoscopy revealed mucosal erythema and a few erosions in the middle third of the esophagus. The post-procedural course was uneventful.

DISCUSSION

Foreign bodies in the esophagus can cause a variety of complications, which can be divided into acute (erosions, deep laceration, ulcer, per-

Received • Примљено:
October 11, 2017**Accepted • Прихваћено:**
April 4, 2018**Online first:** April 13, 2018**Correspondence to:**Zlatko DJURIĆ
Department of Gastroenterology
Children's Hospital
18000 Niš, Serbia
zldjuric@yahoo.com

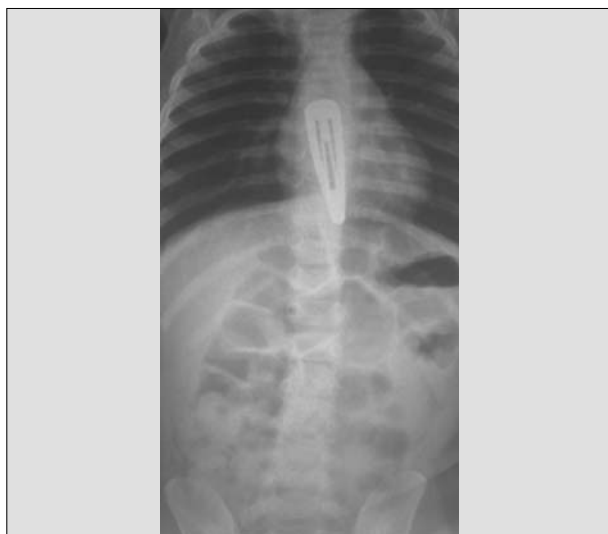

Figure 1. Anteroposterior X-ray – a long hairpin retained in the esophagus

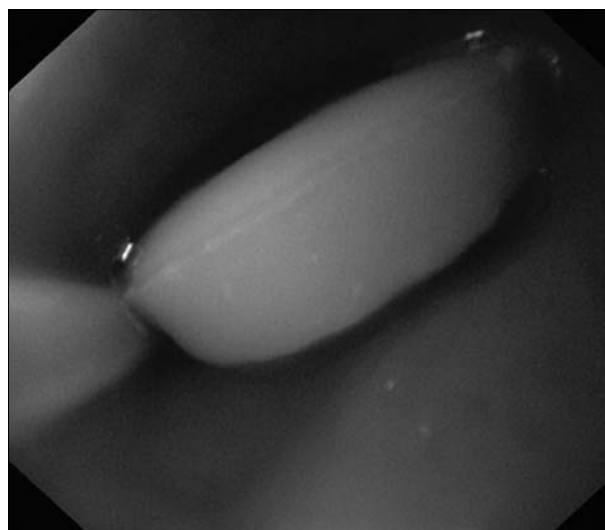


Figure 2. The hairpin encircled with polypectomy snare during endoscopic removal

foration, respiratory distress, and even death) and delayed (stricture, esophago-tracheal and esophago-aortic fistulas) complications [4–7]. The rate of complications is directly proportional to the foreign body sharpness and impaction time [8]. Early recognition and endoscopic intervention is of paramount importance in order to prevent a wide array of potential complications.

A variety of therapeutic procedures to remove esophageal foreign bodies has been described. These include flexible and rigid endoscopy, Foley catheter extraction, bougienage, and the use of Magill forceps [9, 10, 11]. Flexible endoscopy under general anesthesia is the therapeutic procedure of choice because the foreign body can be directly removed and the esophagus can be examined for potential complications and other pathology [1]. Endoscopists should be familiar with different tools for removing foreign bodies, such as various types of graspers (rat-tooth, alligator), retrieval net, polypectomy snare, and biopsy forceps. Rigid endoscopy may be a viable alternative, especially in cases with sharp foreign bodies located in the hypopharynx and the proximal esophagus.

According to the North American Society for Pediatric Gastroenterology, Hepatology and Nutrition Endoscopy Committee's recently revised guidelines for the management of ingested foreign bodies in children, the timing of the esophageal foreign body removal depends on the foreign body type, the presence of symptoms, and the time of the patient's last oral intake and can either be emergent (< 2 hours from the presentation, regardless of the *nil per*

os (NPO) status) or urgent (< 24 hours from the presentation, following the usual NPO guidelines) [1]. In cases of long esophageal foreign bodies, like the one presented in this article, endoscopic intervention should be done urgently in case of both asymptomatic and symptomatic patients. When the patient is symptomatic, surgical consultation before endoscopy is mandatory, as the impacted foreign body may have perforated the esophageal wall.

Magill forceps can also be used for fast and safe removal of foreign bodies from the pharynx and the proximal esophagus. Successful and complication-free removal of coins by the use of this technique has been reported by Janik and Janik [12] in the case of 36 children, and by Mahafza [13] in the case of 71 children. Arana et al. [14] have reported foreign body extraction by Magill forceps in 28 children with foreign bodies in the oropharynx. Of the 28 patients, 22 had ingested fish or poultry bones, and the rest had ingested glass or metal objects. In a recently published article, Turkish authors reported very good clinical experience in removal of different foreign bodies from proximal esophagus by Magill forceps in almost all of the 88 pediatric patients [11].

In conclusion, if a long foreign body is retained in the esophagus, an urgent endoscopic removal is absolutely necessary. The Magill forceps can be a very useful tool if the foreign body is stuck in the hypopharynx during an endoscopic removal and should be readily available in any setting where this kind of endoscopic procedure is being performed.

REFERENCES

1. Kramer RE, Lerner DG, Lin T, Manfredi M, Shah M, Stephen TC, et al. Management of ingested foreign bodies in children: a clinical report of the NASPGHAN Endoscopy Committee. *J Pediatr Gastroenterol Nutr.* 2015; 60(4):562–74.
2. Louie MC, Bradin S. Foreign body ingestion and aspiration. *Pediatr Rev.* 2009; 30(8):295–301.
3. Antoniou D, Christopoulos-Geroulanos G. Management of foreign body ingestion and food bolus impaction in children: a retrospective analysis of 675 cases. *Turk J Pediatr.* 2011; 53(4):381–7.
4. Peters NJ, Mahajan JK, Bawa M, Chhabra A, Garg R, Rao KL. Esophageal perforations due to foreign body impaction in children. *J Pediatr Surg.* 2015; 50(8):1260–3.

5. Lu YP, Yao M, Zhou XY, Huang B, Qi WB, Chen ZH, et al. False esophageal hiatus hernia caused by a foreign body: A fatal event. *World J Gastroenterol.* 2014; 20(39):14510–4.
6. Zhang YB, Gao ZG, Xiong QX, Zhang LF, Cai DT, Cai JB. Clinical experience in the treatment of children who swallowed multiple magnetic foreign bodies. A report of five cases. *World J Pediatr.* 2017; 13(3):274–7.
7. Si X, Du B, Huang L. Multiple magnetic foreign bodies causing severe digestive tract injuries in a child. *Case Rep Gastroenterol.* 2016; 10(3):720–7.
8. Hong KH, Kim YJ, Kim JH, Chun SW, Kim HK, Cho JH. Risk factors for complications associated with upper gastrointestinal foreign bodies. *World J Gastroenterol.* 2015; 21(26):8125–31.
9. Bao WK. Study of foreign-body extraction from the upper third of the esophagus in children. *Iran J Pediatr.* 2014; 24(2):214–8.
10. Waltzman M. Management of esophageal coins. *Pediatr Emerg Care.* 2006; 22(5):367–70.
11. Oncel M, Sunam GS, Elsurer C, Yildiran H. Use of Magill forceps to remove foreign bodies in children. *Surg J (NY).* 2017; 3(2):e91–5.
12. Janik JE, Janik JS. Magill forceps extraction of upper esophageal coins. *J Pediatr Surg.* 2003; 38(2):227–9.
13. Mahafza TM. Extracting coins from the upper end of the esophagus using a Magill forceps technique. *Int J Pediatr Otorhinolaryngol.* 2002; 62(1):37–9.
14. Arana A, Hauser B, Hachimi-Idrissi S, Vandenplas Y. Management of ingested foreign bodies in childhood and review of the literature. *Eur J Pediatr.* 2001; 160(8):468–72.

Компликација током ендоскопског вађења дугачког страног тела из једњака код девојчице узраста осам месеци

Златко Ђурић, Драгољуб Живановић

Универзитет у Нишу, Медицински факултет, Клиника за дечје интерне болести, Гастроентеролошки одсек, Ниш, Србија;
Универзитет у Нишу, Медицински факултет, Клиника за дечју хирургију и ортопедију, Ниш, Србија

САЖЕТАК

Увод Страна тела у једњаку могу проузроковати велики број акутних и одложених компликација.

Циљ овог рада је био да прикажемо компликацију у току одстрањивања дугог страног тела из једњака.

Приказ болесника Девојчица узраста осам месеци примљена је у болницу због акутне дисфагије, хиперсаливације и повраћања. На нативној графији у антеропостериорном положају нађена је дугачка шнала, која се задржала у једњаку. Током ендоскопског вађења уз примену омче за полипек-

томију шнала се заглавила у хипофарингсу. Није могла бити извађена покретима ендоскопа и постављањем болесника у различите положаје. Коначно, шнала је извађена уз примену Магиловог форцепса под контролом ларингоскопа.

Закључак Магилов форцепс може бити веома корисно оруђе ако се страно тело заглави у хипофарингсу током ендоскопског вађења и требало би да буде доступан у свим приликама када се обавља ова врста ендоскопске процедуре.

Кључне речи: компликација; страно тело; ендоскопија; вађење; Магилов форцепс