



CASE REPORT / ПРИКАЗ БОЛЕСНИКА

HeartMate 3 fully magnetically levitated left ventricular assist device for advanced heart failure – initial Serbian experience

Emilija Nestorović¹, Duško Terzić¹, Svetozar Putnik¹, Arsen Ristić², Miljko Ristić¹

¹Clinical Center of Serbia, Clinic for Cardiac Surgery, Department for Heart Transplant, Belgrade, Serbia;

²Clinical Center of Serbia, Cardiology Clinic, Belgrade, Serbia

SUMMARY

Introduction As the waiting time for heart transplantation continues to increase due to shortage in organ donation, supporting patients with advanced heart failure with left ventricular assist device (LVAD) increases as well. The latest generation of LVAD, left ventricular assist system (LVAS) started to expand worldwide due to more promising outcomes.

The aim of this article was to present the case of treating advanced heart failure in a patient who underwent implantation of HeartMate 3 LVAS as the bridge to transplantation.

Case outline The patient was a 59-year-old man with advanced heart failure requiring inotropic drug support, with ischemic cardiomyopathy as the underlying cause of heart failure. Therefore, in the absence of an adequate donor, it was decided to incorporate the LVAS as a bridge to transplantation. Functional capacity, cardiac, renal, and liver functions improved in the patient.

Conclusion The use of the HeartMate 3 in an advanced heart failure patient results in improvements in functional capacity, cardiac, renal and liver function. Further studies should be performed in order to identify whether improved outcomes are sustained with a longer follow-up period.

Keywords: LVAD; heart failure; heart transplantation

INTRODUCTION

Patients with advanced heart failure (HF) have quite limited possibilities for therapy, so the morbidity and mortality in connection to the disease are unacceptably high. In light of the insufficient availability of donor hearts and a growing number of heart transplantation (HT) ineligible patients, left ventricular assist devices (LVAD) are often used to support patients with advanced HF awaiting HT or as destination therapy (DT) [1]. In order to improve clinical outcomes of LVAD therapy, technological advances have been made through different types of LVAD pumps over the past 30 years, from pulsatile to continuous flow (CF) and now back to artificial pulsatility. Compared to the pulsatile flow HeartMate (HM) XVE, the newer generation of LVAD and CF-LVAD is considerably smaller, with significantly lower incidence of adverse events and has become the standard of care as a bridge to transplantation (BTT) [1]. HM II (Abbott Corporation, Chicago, IL, USA) is an axial pump that provides CF, which requires a tissue pocket and a larger body surface of the patient, while other intrapericardial CF pumps, like HeartWare (HeartWare Inc., Framingham, MA, USA), utilize a magnetically levitating rotor system to decrease mechanical wear in order to reduce hemolysis and the incidence of pump thrombosis. Also, due to smaller size, it is suitable

for patients with smaller body surface area [2]. Despite the fact that with the newer generation of LVAD survival rate is much better, the overall adverse events are still significantly high [3]. Therefore, technology enhancements of LVAD have become increasingly important in order to improve post-LVAD outcomes and to reduce the rate of adverse events. The latest generation pump, HM 3 (Abbott Corporation) is intrapericardial fully magnetically levitated CF-LVAD with artificial pulsatility with large, consistent pump gaps designed to reduce blood trauma and minimize stasis of blood.

The aim of this article was to present a case of treating the end-stage of HF in a patient in whom the latest generation of LVAD, left ventricular assist system (LVAS), HM 3, was implanted.

CASE REPORT

The patient was a 59-year-old man with advanced HF, with ischemic cardiomyopathy as the underlying cause. Ten months prior to hospitalization at our institution, the patient suffered from acute heart infarction of the anterior wall as the first manifestation of coronary disease. Since the patient was admitted to a local hospital after 24 hours had passed, neither percutaneous coronary intervention nor fibrinolysis was applied. At the local hospital, the

Received • Примљено:

July 19, 2017

Revised • Ревизија:

November 16, 2017

Accepted • Прихваћено:

November 22, 2017

Online first: December 8, 2017

Correspondence to:

Emilija NESTOROVIĆ
Clinic for Cardiac Surgery, Clinical
Center of Serbia
Koste Todorovica 8
11000 Belgrade, Serbia
emanestor@gmail.com




Figure 1. Left ventricular assist system, HeartMate 3 implantation: a) left ventricle open at the top; b) sewn ring at the left ventricle; c) preparation of the pump; d) connecting the pump to the ring; e) connected pump in the pericardial cavity; f) outflow graft sewn to the aorta

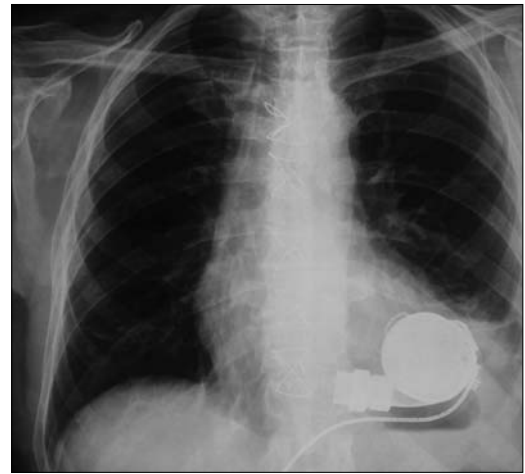


Figure 2. Radiographic finding after implanted HeartMate 3 left ventricular assist system

patient underwent coronary angiography that showed an occlusion of the left anterior descending coronary artery and stenosis of the proximal circumflex coronary artery and he was treated with medicaments. After the acute ischemic phase, the hospital treatment was hindered by the development of left ventricular (LV) aneurysm and the appearing symptoms of HF. He complained of fatigue while at rest, of choking, chest pain, and swelling in the legs. Ten months after the myocardial infarction, he came to our institution due to symptoms of advanced HF and required inotrope support drugs. Both two-dimensional transthoracic echocardiography (TTE) and transesophageal echocardiography (TEE) were performed in the standard manner using Vivid E 9 (GE Medical Systems, Milwaukee, WI, USA) and showed a volume overload of LV (EDV 257 ml), increased LV end-diastolic (LVEDD) and end-systolic diameters (LVESD), 7.4 cm and 6.3 cm, respectively, and significantly decreased ejection fraction of LV (LVEF) to 18% calculated by the Biplane method. There were akinesis in the LV septum, apex, apical part of anterolateral and inferior walls, apical and medial part of the anterior wall with LV apex aneurysm without visible thrombotic masses. Severe mitral regurgitation (MR 3+) was present. The right ventricle had regular dimensions (2.6 cm) with good systolic and longitudinal functions (global fractional area change of 27%, tricuspid annular plane systolic excursion of 21 mm, and right ventricular systolic excursion velocity of 18 cm/s). There was severe functional tricuspid regurgitation (TR 3+) with high right ventricle systolic pressure (RVSP 77 mmHg). Single-photon emission computed tomography showed the absence of viable myocardium of the septum, anterior and lateral wall of the LV. Preoperative hemodynamic data showed pulmonary capillary wedge pressure (PCWP) of 27 mmHg, central venous pressure (CVP) of 11 mmHg, cardiac index (CI) of 1.9 L/min./m². In order to assess the possibility of LVAS implantation, the nature of the LV apex aneurysm was estimated by performing magnetic resonance imaging of the heart. At the part of LV apex aneurysm, the myocardial wall thickness was 3–5 mm with aneurysmal

extension, which was a borderline finding for pump implantation. Based on all the performed tests, it was concluded that the patient was in the end-stage of HF (New York Heart Association (NYHA) IV, Interagency Registry for Mechanically Assisted Circulatory Support 3), with significantly impaired LV function requiring continuous inotropic support; therefore, it was decided in the absence of an adequate donor to incorporate the LVAS as a BTT.

The patient underwent surgery under general anesthesia. The surgery included the implantation of LVAS, HM 3. After median sternotomy, in conditions of extracorporeal circulation without aortic clamping and stopping of the heart, the LV was opened at the top, the ring was sewn, and after preparation, the pump was connected to the ring. The driveline was placed through the skin in the form of double tunneling and connected to the pump controller and the energy source. Finally, a graft was sewn to the aorta (Figure 1). Unlike the LVAD HM 2 device, where it is necessary to form a tissue pocket to place the device, LVAS HM 3 was applied fully intrapericardially. The intervention was without complications.

The postoperative recovery was uneventful. After the LVAS implantation, a standardized anticoagulation regimen was used with initiation of infusion of heparin, followed by the transition to warfarin and aspirin. Anticoagulation therapy was included in order to maintain the international normalized ratio between 2.0 and 3.0. There was normal flow through both the pump's inflow and outflow cannula. The pump speed was set at 4,900 rpm, with pump flow being 3.4 L/min. and pump power 3.2 w. There were stable LVAS parameters and data on the pump controller. The radiographic finding was regular (Figure 2). Postoperative hemodynamic data showed PCWP of 10 mmHg, CVP of 7 mmHg, CI of 3.2 L/min./m². Functional cardiac (TTE and brain-type natriuretic peptide – BNP), renal and liver function assessments were done before the LVAD implantation, at discharge from the hospital and at 12 months. The TTE examination at discharge showed improvement in the LVEDD and the LVESD from baseline values of 7.4 and 6.3 to 5.5 and 4.5, respectively. This

improvement was sustained over the time of the follow-up. For LVEF and BNP (pg/ml), the baseline values of 18% and 670 improved to 39% and 173, respectively, and continued to improve during the period of 12 months to 50% and 120, respectively. The dimension of the right ventricle was sustained in the normal range (2.6 cm) with a good systolic function. At discharge, NYHA functional classification improved from IV at baseline to II and continued to improve to I during the period of 12 months. There were improvements in renal function from baseline-estimated glomerular filtration rate (ml/min./1.73 m²) and serum creatinine (nmol/L) of 40 and 155 to 57 and 114, respectively, and there was no change over the entire follow-up period. With regard to hepatic function, total bilirubin (μmol/L) showed a reduction at the discharge point (25.8 vs. 12.4), with no further change afterwards. There were no significant changes of aspartate transaminase (IU/L), and alanine transaminase (IU/L) values during the entire follow-up period.

DISCUSSION

HT remains the treatment of choice in cardiac replacement therapy for patients with end-stage HF. As the waiting time for HT continues to increase, supporting patients with LVAD increases as well. LVAD support enables an improved quality of life and survival compared to medical therapy [4]. However, despite all of these benefits of new technology of LVAD, there is still significant incidence of device-related complications that may have lessened enthusiasm for investigating LVAD therapy in less sick patients [5].

REFERENCES

1. Kirklin JK, Naftel DC, Kormos RL, Stevenson LW, Pagani FD, Miller MA, et al. The Fourth INTERMACS Annual Report: 4,000 implants and counting. *J Heart Lung Transplant.* 2012; 31(2):117–26.
2. Sajgalik P, Grupper A, Edwards BS, Kushwaha SS, Stulak JM, Joyce DL, et al. Current Status of Left Ventricular Assist Device Therapy. *Mayo Clin Proc.* 2016; 91(7):927–40.
3. Kirklin JK, Naftel DC, Pagani FD, Kormos RL, Stevenson LW, Blume ED, et al. Seventh INTERMACS annual report: 15,000 patients and counting. *J Heart Lung Transplant.* 2015; 34(12):1495–504.
4. Estep JD, Starling RC, Horstmanshof DA, Milano CA, Selzman CH, Shah KB, et al. Risk Assessment and Comparative Effectiveness of Left Ventricular Assist Device and Medical Management in Ambulatory Heart Failure Patients: Results From the ROADMAP Study. *J Am Coll Cardiol.* 2015; 66(16):1747–61.
5. Grimm JC, Magruder JT, Kemp CD, Shah AS. Late Complications Following Continuous-Flow Left Ventricular Assist Device Implantation. *Front Surg.* 2015; 2:42.
6. Netuka I, Sood P, Pya Y, Zimpfer D, Krabatsch T, Garbade J, et al. Fully Magnetically Levitated Left Ventricular Assist System for Treating Advanced HF: A Multicenter Study. *J Am Coll Cardiol.* 2015; 66(23):2579–89.

HeartMate 3 систем за асистирану потпору левој комори са потпуно магнетним левитирајућим мотором за узрапредовалу срчану слабост – прва искуства у Србији

Емилија Несторовић¹, Душко Терзић¹, Светозар Путник¹, Арсен Ристић², Миљко Ристић¹

¹Клинички центар Србије, Клиника за кардиохирургију, Одељење за трансплантацију срца, Београд, Србија;

²Клинички центар Србије, Клиника за кардиологију, Београд, Србија

САЖЕТАК

Увод Услед недостака донорских органа, време чекања на трансплантацију срца све је дуже и све је већи број болесника у узрапредовалој срчаној слабости који су лечени уређајима за асистирану циркулацију левог срца. Због добрих резултата, широм света је започела примена најновије генерације уређаја за асистирану циркулацију левог срца, система за асистирану потпору леве коморе.

Циљ овог рада је био да прикаже лечење болесника у узрапредовалој фази срчане слабости имплантацијом система за асистирану потпору леве коморе – *HeartMate 3*, као премошћавање периода до трансплантације срца.

Приказ болесника Приказујемо мушкараца старог 59 година на инотропној потпори лековима, у узрапредовалој

фази срчане слабости и исхемијском кардиомиопатијом као њеним основним узроком. У одсуству донора, болеснику је уграђен систем за асистирану потпору леве коморе за премошћавање периода до трансплантације срца. Код болесника је дошло до побољшања функционалног капацитета, срчане, реналне и хепатичке функције.

Закључак Употреба *HeartMate 3* код болесника у узрапредовалој срчаној слабости доводи до побољшања функционалног капацитета, срчане, реналне и хепатичке функције. Даља истраживања треба спровести у циљу откривања дали се са временом праћења побољшани исходи одржавају.

Кључне речи: уређаји за асистирану циркулацију; срчана слабост; трансплантација срца