

CASE REPORT / ПРИКАЗ БОЛЕСНИКА

Laparoscopic sleeve gastrectomy in a superobese patient with restenosis of the trachea

Miroslav Ilić^{1,2}, Srđan S. Putnik³¹Institute for Pulmonary Diseases of Vojvodina, Clinic for Thoracic Surgery, Sremska Kamenica, Serbia²University of Novi Sad, Faculty of Medicine, Novi Sad, Serbia;³Vršac General Hospital, Department of General Surgery, Vršac, Serbia**SUMMARY**

Introduction Superobese group of patients with body mass index (BMI) ≥ 50 kg/m² have higher technical intraoperative problems, higher morbidity, and mortality. Indications for the metabolic procedure are widening and minimally invasive operation dictates that both patients and surgeons face previously assumed “general contraindication” for a surgical bariatric/metabolic procedure.

Case outline We present a superobese patient with restenosis of the trachea, chronic obstructive pulmonary disease, sleep apnea, and cardiomyopathy with panniculus grade IV, in whom, as a multidisciplinary team, we simultaneously performed permanent tracheostomy, laparoscopic sleeve gastrectomy, and panniculectomy.

Conclusion Quality of life after the bariatric operation must be a leading factor in regard to the approach to a difficult patient, with the operation adaptable enough to fit all demands.

Keywords: superobese; laparoscopic sleeve gastrectomy; bariatric surgery

INTRODUCTION

In recent decades, obesity has become a significant health and surgical problem worldwide [1]. The superobese group of patients with body mass index (BMI) ≥ 50 kg/m² have more pronounced technical intraoperative problems, more postoperative complications, and higher mortality [2, 3]. Indications for metabolic operation are widening and successful management of comorbidities after minimally invasive operation dictates that both patients and surgeons face previously assumed “general contraindication” for a surgical bariatric/metabolic procedure. Is elective surgery justified in a selected group of patients who experience dysfunction of several vital organs?

We present a high-risk superobese patient with chronic respiratory failure, cardiomyopathy, and restenosis of previously resected trachea, who came to the surgeon for removing panniculus (grade IV), refused for surgery in non-referral surgical centers [4]. We performed a successful laparoscopic sleeve gastrectomy after re-tracheostomy with a synchronous panniculectomy.

CASE REPORT

The patient was a male Caucasian, 54 years old, weighing 160 kg, 175 cm tall, BMI of 52.3 kg/m² (Figure 1A). His neck's circumference was 49.5 cm. He complained of large panniculus and inspiratory stridor. In a tertiary institution, he was refused for panniculectomy operation due

to restenosis of the upper trachea, respiratory chronic failure, and chronic cardiomyopathy with 10 years' medically history of hypertension with arrhythmia. Previously (11 years prior), he had a surgical repair of the stenotic trachea after a prolonged intubation due to the attempt of suicide with local pesticide poison containing parathion during a psychical paranoid episode (Figure 2). After his recovery, he started to gain weight. At his admittance to the Clinic, the patient was an active smoker and consumed 15 cigarettes per day during the previous 25 years.

At the University Clinic for Thoracic Surgery, Department for Esophageal and Laparoscopic Surgery, Sremska Kamenica, Serbia, we performed multi-slice computed tomography (MSCT) of the neck and thorax and tracheo-bronchoscopy. Preoperative MSCT showed restenosis of the trachea 12 mm beyond the glottis. Endoscopic findings suggested restenosis immediately beneath the vocal cords, which appeared immobilized and showed disarrangement of the whole larynx. Respiratory function showed global respiratory insufficiency due to alveolar hypoventilation and chronic obstructive pulmonary disease. Cardiac function was estimated with echocardiogram (ejection fraction of 65%) and dilatation of the left atrium and hypertension were noted. Sleep apnea study was not done due to restenosis of the trachea, but the patient was previously treated with ventilator support during the night. The patient lived without suicidal thoughts for the previous 10 years, living in a stable social relationship with his wife, working as an agricultural laborer. After the multidisciplinary

Received • Примљено:

April 11, 2018

Accepted • Прихваћено:

July 20, 2018

Online first: August 7, 2018**Correspondence to:**Srđan S. PUTNIK
Vršac General Hospital
Department of General Surgery
Abraševićeva bb
26300 Vršac, Serbia
putniksrđjan@outlook.com

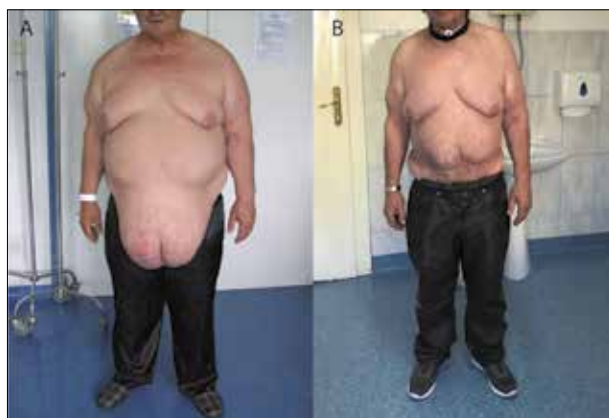

Figure 1. The superobese 54-year-old patient before the operation (A) and one year later (B)

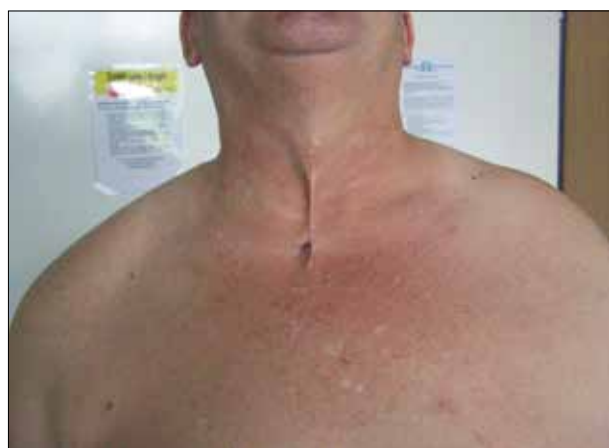

Figure 2. The scar from the previous tracheal operation

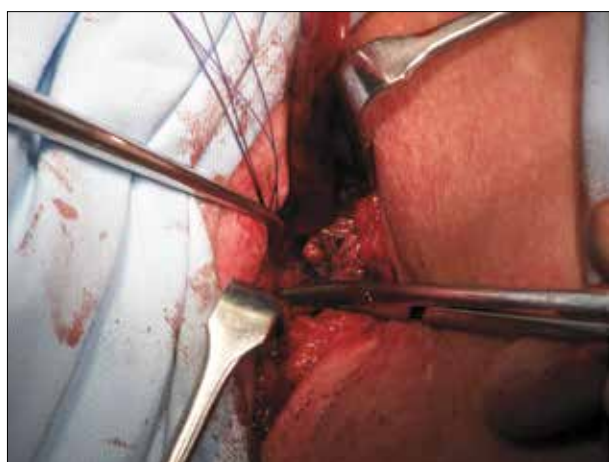


Figure 3. Re-tracheostomy

surgical and the otorhinolaryngology team provided explanations, the patient accepted the reasonable risk and the operation.

The operation begins with intraoperative direct and rigid laryngoscopy and temporary intubation with tracheal tube No. 6. Excision of the scar tissue was done after identification of the tracheal restenosis *in loco* of the subglottic-tracheal junction (Figure 3). Re-tracheostomy was performed and cannula No. 9 was placed and fixed for further airway support for the procedure. The patient was placed in the French position and laparoscopic sleeve

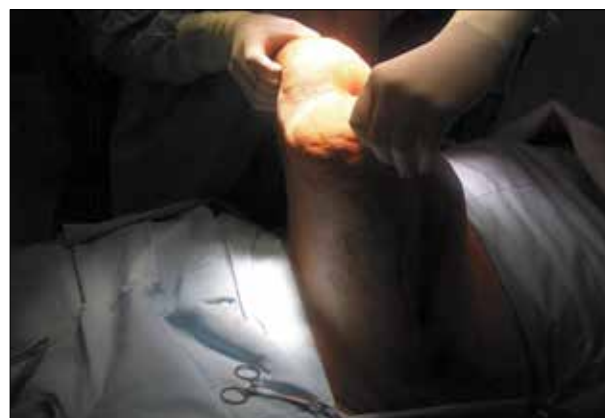

Figure 4. Preparation for panniculectomy

gastrostomy was done with the four-trocar technique. After completing the laparoscopic procedure, panniculectomy was done in the standard fashion (Figure 4). Postoperative period was uneventful and the patient spent 14 days in the hospital.

After 12 months, the patient's body weight was 93 kg, BMI of 30.4 kg/m², percentage of excess weight loss of 71.4 (Figure 1b). The patient adapted to the permanent metal tracheal cannula and spoke routinely by closing the cannula opening. He was very satisfied with his quality of life.

DISCUSSION

Superobese patients with BMI ≥ 50 kg/m² and neck circumference > 42 cm are considered to be 50 times more likely to experience difficulties in intubation [5]. In our patient, restenosis of the previously resected trachea was a factor for refusing anesthesia and any elective surgery in non-experienced centers. This patient's only hope was an experienced center specialized in tracheal surgery and obesity surgery. His primary health demand was the removal of panniculus, but the explanation of the multidisciplinary team resulted in the acceptance of simultaneous surgical tracheal, metabolic, and plastic intervention. At every step, as a team, we considered discontinuing the intervention in case of any complications.

Difficult intubation during operation for morbid obesity is a relatively uncommon situation, which requires emergency tracheostomy in very few cases [6]. However, a very difficult situation arises with stenosis of the trachea, as was the case in our patient. This poses a problem not the only to the anesthesiologist, but also to the patient, as unsolved restenosis of the trachea permanently damages the patient's health. This is why an otorhinolaryngologist was included in solving the problem with permanent tracheostomy.

The question of the patient's psychological status is also important for the success of the entire postoperative period. Our patient was cooperative, with social, family life, and able to work. He reasonably inquired not only about panniculectomy but also about the reduction of weight. The question was what operation to choose. We decided to perform a simple but effective operation, with possible

eventful recovery, which would not dependent on continuous therapy of supplementation. Simultaneously, we did panniculectomy since it was the patient's primary demand. Several authors suggest that panniculectomy should be performed after patients stabilize body weight, but there are some exceptions, as in cases with panniculus grade IV and V [4, 7]. Perhaps there is a special indication in patients with tracheostomy and difficult approach to airways. The cosmetic result in our patient supports this thesis.

The result regarding sleeve gastrectomy and weight loss is good after one year. The patient was on surgical

check-ups at regular intervals and his attitude regarding the quality of life was superior.

In the era of the modern, team approach, morbidly obese patients could be treated successfully even with serious comorbidities nondependent on obesity. The quality of life after the bariatric operation is a factor which must be a leading one in the concern as to how to approach a difficult patient, with operation adaptable enough to fit all demands.

Conflict of interest: None declared.

REFERENCES

- Engin A. The Definition and Prevalence of Obesity and Metabolic Syndrome. *Adv Exp Med Biol.* 2017; 960:1–17.
- Parikh MS, Shen R, Weiner M, Siegel N, Ren CJ. Laparoscopic bariatric surgery in super-obese patients (BMI>50) is safe and effective: a review of 332 patients. *Obes Surg.* 2005; 15(6):858–63.
- Darrat I, Yaremchuk K. Early mortality rate of morbidly obese patients after tracheotomy. *Laryngoscope.* 2008; 118(12):2125–8.
- Igwe D Jr, Stanczyk M, Lee H, Felahy B, Tambi J, Fobi MA. Panniculectomy adjuvant to obesity surgery. *Obes Surg.* 2000; 10(6):530–9.
- Riad W, Vaez MN, Raveendran R, Tam AD, Quereshy FA, Chung F, et al. Neck circumference as a predictor of difficult intubation and difficult mask ventilation in morbidly obese patients: A prospective observational study. *Eur J Anaesthesiol.* 2016; 33(4):244–9.
- Baltasar A, Bou R, Bengochea M, Serra C, Pérez N. Emergency Tracheotomy in Morbid Obesity. *Austin Surg Case Rep.* 2017; 2(2):1018.
- Gurunluoglu R. Insurance coverage criteria for panniculectomy and redundant skin surgery after bariatric surgery: why and when to discuss. *Obes Surg.* 2009; 19(4):517–20.

Лапароскопска рукавна гастректомија код супергојазног болесника са рестенозом трахеје

Мирослав Илић^{1,2}, Срђан С. Путник³

¹Институт за плућне болести Војводине, Клиника за грудну хирургију, Сремска Каменица, Србија;

²Универзитет у Новом Саду, Медицински факултет, Нови Сад, Србија;

³Општа болница „Вршац“, Служба опште хирургије, Вршац, Србија

САЖЕТАК

Увод Супергојазна група болесника са индексом телесне масе $\geq 50 \text{ kg/m}^2$ има веће техничке и интраоперативне проблеме, већи морбидитет и морталитет. Индикације за метаболичке процедуре се повећавају и минимално инвазивне операције захтевају како од болесника тако и од хирурга да се суоче са претходно подразумеваним „општим контраиндикацијама“ за хируршку баријатријску/метаболичку процедуру.

Приказ болесника Представљамо супергојазног болесника са рестенозом трахеје, хроничном опструктивном болешћу

плућа, опструктивним апнеја синдромом и кардиомиопатијом и паникулусом четвртог степена, ког кога је мултидисциплинарни тим урадио истовремено трајну трахеостомију, лапароскопску рукавну гастректомију и паникулектомију.

Закључак Квалитет живота после баријатријске операције мора бити водећи фактор у начину приступања тешком болеснику, са операцијом прилагођеном свим захтевима.

Кључне речи: супергојазни, лапароскопска рукавна гастректомија, баријатријска хирургија