

## CASE REPORT / ПРИКАЗ БОЛЕСНИКА

# Isolated dislocation of the pisiform bone in a 10-year-old boy

Siniša Dučić<sup>1,2</sup>, Nikola Bojović<sup>3</sup>, Vladimir Radlović<sup>1</sup>, Goran Đuričić<sup>1</sup>, Bojan Bukva<sup>1</sup><sup>1</sup>University Children's Hospital, Belgrade, Serbia;<sup>2</sup>University of Belgrade, Faculty of Medicine, Belgrade, Serbia;<sup>3</sup>Niš Clinical Center, Pediatric Surgery and Orthopedics Clinic, Niš, Serbia**SUMMARY**

**Introduction** Isolated dislocation of the pisiform bone is a very rare condition due to robust ligamentous attachments that stabilize the pisiform to the carpus. This type of injury is usually a result of direct trauma to the ulnar and volar aspect of the wrist.

**Case outline** We present an isolated dislocation of the pisiform, with no other carpal bone injuries, treated successfully with closed reduction. Diagnosis was based on clinical findings, plain radiographs, and computer tomography examination of the wrist. Elongation and partial rupture of the pisometacarpal ligament was found on magnetic resonance imaging.

**Conclusion** Fracture and dislocation of the pisiform is an extremely rare injury in children, which could be easily neglected or misdiagnosed. Closed reduction with plaster cast immobilization should always be considered as the first method of treatment in the pediatric population, since the conservative approach provides excellent results.

**Keywords:** dislocation; pisiform; children

**INTRODUCTION**

Pisiform bone dislocation is a rare injury reported mostly in young male adults and literature is void of reports on this type of injury in children [1]. Isolated dislocation of carpal bones is rare, except for the lunate and the perilunate bone. Dislocation of the pisiform bone is particularly rare because of the sturdiness of the ligamentous complex which stabilizes the pisiform to the carpus [2, 3, 4]. In this paper, we present a case of isolated pisiform dislocation in a young boy, successfully treated by closed reduction.

**CASE REPORT**

A 10-year-old boy injured his left wrist in a fall and was admitted to hospital due to a suspected fracture of the pisiform bone. Clinical examination revealed swelling around the ulnar aspect of the left wrist joint, with local tenderness and painful restriction of all wrist movements. The neurovascular examination of ulnar artery and nerve was normal. The radiographs (anteroposterior and lateral view) of the left wrist showed an isolated dislocation of the pisiform bone (Figure 1) on the lateral radiographs. Further diagnostic tests followed. Computed tomography showed isolated anteroradial displacement of the pisiform of 7 mm. There were no other injuries of bones, soft tissues, or blood vessels (Figure 2). Additionally, a magnetic resonance imaging scan confirmed the 7 mm anteroradial dislocation of the pisiform bone but also

revealed an elongation and partial rupture of the pisometacarpal ligament (Figure 3). Closed reduction of the pisiform was performed under an X-ray image intensifier, direct pressure was applied to relocate the bone with a slightly dorsiflexed position and a stable reduction was achieved. The wrist was immobilized with a long arm plaster cast in dorsiflexion for four weeks. Four weeks after the procedure, the cast was removed and radiographs revealed correct position of the pisiform bone. At the 12-month follow-up, the patient was clinically well, without any pain or limitation of motion, and X-ray imaging showed normal results (Figure 4).

**DISCUSSION**

We searched the literature in English on PubMed for terms 'pisiform,' 'fracture,' 'dislocation,' and 'children,' and, to the best of our knowledge, three pisiform dislocations associated with type I and II Salter–Harris fracture of the distal radius fracture in children have been reported [1, 5, 6]. As of yet, no isolated fracture and dislocation of the pisiform bone in children has been reported.

The pisiform bone lies in the proximal row of the carpal bones and forms a synovial joint by articulating with the triquetrum. Its stability is ensured by a complex structure composed of 10 soft tissue attachments [7]. This may be the reason why injuries of the pisiform are generally rare. When pisiform dislocations occur, it is usually due to direct trauma to the ulnar and

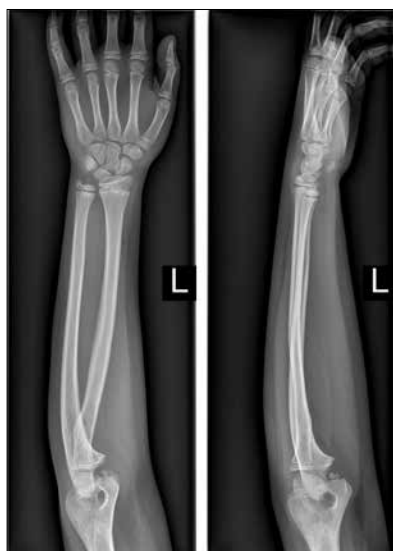**Received • Примљено:**  
June 11, 2018

**Accepted • Прихваћено:**  
August 14, 2018

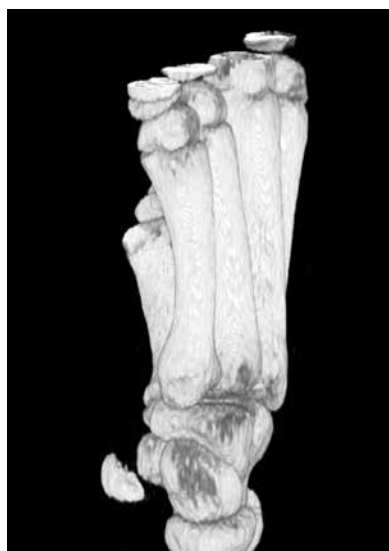**Online first:** October 5, 2018

**Correspondence to:**

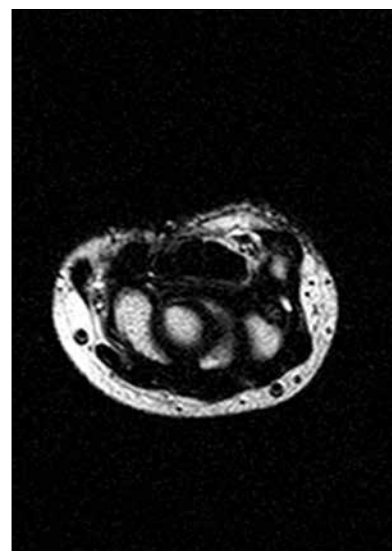
Siniša DUČIĆ  
University Children's Hospital  
Tiršova 10  
11000 Belgrade, Serbia  
[sinisaducic@gmail.com](mailto:sinisaducic@gmail.com)



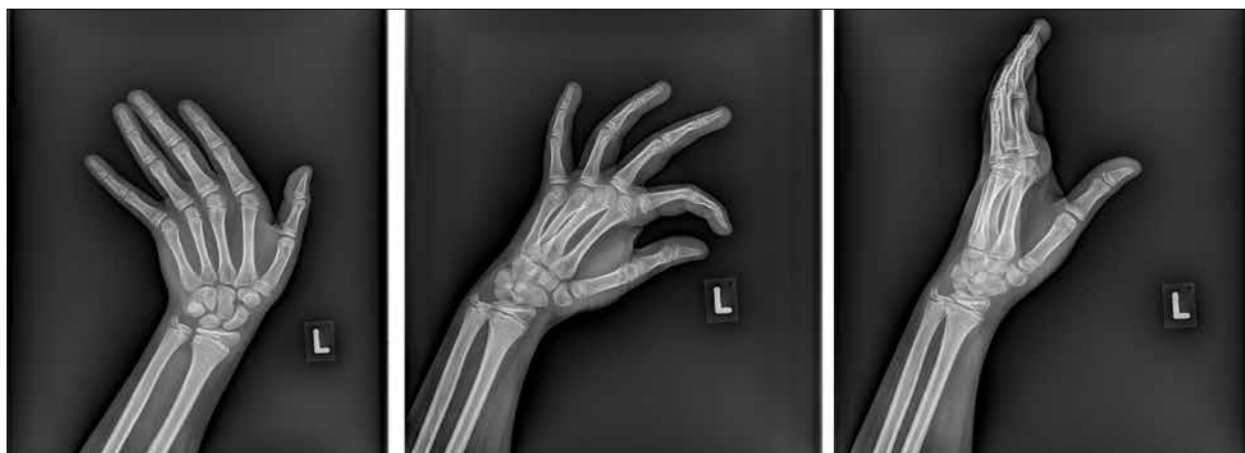**Figure 1.** Initial radiographic presentation: X-ray clearly shows the pisiform bone dislocation



**Figure 2.** Three-dimensional volume rendering of spiral computed tomography scan shows dislocation of the pisiform bone



**Figure 3.** Transversal plane T2-weighted magnetic resonance imaging; the pisometacarpal ligament is elongated and heterointense, with partial interstitial rupture



**Figure 4.** X-ray at the one-year follow-up: correct position of the pisiform bone

volar aspect of the wrist or as a consequence of an indirect force such as a forceful muscular contraction in a minority of cases [4]. As the center of ossification of the pisiform bone appears between 7.5 and 10 years of age and the pisiform is not always clearly visualized, diagnosing pisiform fracture and dislocation in children could be very challenging [6].

Different modalities of treatment in adults have been reported in literature, such as closed reduction and immobilization, open reduction with internal fixation and excision of the pisiform [5, 6, 8]. In regard to pediatric population, all reported pisiform dislocations have been managed conservatively. Mancini et al. [5] performed closed reduction of the pisiform in both of their cases. Hurni et al. [1] and Ashkan et al. [5] also reported a closed reduction with immobilization as the method of choice in a pediatric patient. They suggest that this type of injury in children should be primarily treated with closed reduction and immobilization, and a more aggressive approach, such as pisiform bone resection, should be used in case the conservative treatment fails [1]. Furthermore, Sharma and Massraf [4] and Kwon et

al. [8] also support conservative treatment unless recurrent dislocations occur or the disability remains after conservative treatment, in which case resection of the pisiform is recommended. Sharma and Massraf [4] reported an ulnar nerve compression as a consequence of isolated pisiform dislocation in an adult male. No ulnar injuries have been reported in children with pisiform dislocations. In such a case, emergency reduction of the pisiform is required.

Taking everything into consideration, fracture and dislocation of the pisiform is an extremely rare injury in children, which could be easily neglected or misdiagnosed, firstly because physicians usually do not consider this condition, and secondly due to unspecific clinical signs and challenging interpretation of radiographs. Closed reduction with plaster cast immobilization should always be considered as the first method of treatment, as it is a conservative approach that provides excellent result in the pediatric population.

**Conflict of interest:** None declared.

## REFERENCES

- Hurni Y, Fusetti C, de Rosa V. Fracture dislocation of the pisiform bone in children: a case report and review of the literature. *J Pediatr Orthop B*. 2015; 24(6):556–60.
- Minami M, Yamazaki J, Ishii S. Isolated dislocation of the pisiform: a case report and review of the literature. *J Hand Surg Am*. 1984; 9A(1):125–7.
- Sharara KH, Farrar M. Isolated dislocation of the pisiform bone. *J Hand Surg Br*. 1993; 18(2):195–6.
- Sharma S, Massraf A. Ulnar nerve compression as a consequence of isolated pisiform dislocation. *Inj Extra*. 2005; 36:79–81.
- Ashkan K, O'Connor D, Lambert S. Dislocation of the pisiform in a 9-year-old child. *J Hand Surg Br*. 1998; 23(2):269–70.
- Mancini F, De Maio F, Ippolito E. Pisiform bone fracture-dislocation and distal radius physeal fracture in two children. *J Pediatr Orthop B*. 2005; 14(4):303–6.
- Pevny T, Rayan GM, Egle D. Ligamentous and tendinous support of the pisiform, anatomic and biomechanical study. *J Hand Surg Am*. 1995; 20(2):299–304.
- Kwon OS, Choi SP, Won HY. Acute Isolated pisiform dislocation: a case report. *J Korean Orthop Assoc*. 2007; 42(5):688–91.

## Изолована дислокација писиформне кости код дечака узраста 10 година

Синиша Дучић<sup>1,2</sup>, Никола Бојовић<sup>3</sup>, Владимир Радловић<sup>1</sup>, Горан Ђуричић<sup>1</sup>, Бојан Буква<sup>1</sup>

<sup>1</sup>Универзитетска дечја клиника, Београд, Србија;

<sup>2</sup>Универзитет у Београду, Медицински факултет, Београд, Србија;

<sup>3</sup>Клинички центар Ниш, Клиника за дечју хирургију и ортопедију, Ниш, Србија

### САЖЕТАК

**Увод** Изолована дислокација писиформне кости је изузетно ретка имајући у виду робусност лигаментарног апарата који је стабилизује у ручју. Обично је овај тип повреде резултат директне трауме на улнарну и воларну страну ручја.

**Приказ болесника** Представљамо изоловану дислокацију писиформне кости, без повреда осталих костију ручја, која је успешно лечена затвореном репозицијом. Дијагноза је потврђена клиничким прегледом, радиографијом и налазом компјутеризоване томографије ручја. Елонгација и парцијал-

на руптура писометакарпалног лигамента су утврђене помоћу магнетне резонанце.

**Закључак** Прелом и дислокација писиформне кости је изузетно ретка повреда код деце, која се лако може превидети или дијагностички лоше протумачити. Затворену репозицију са гипсаном имобилизацијом треба увек сматрати методом избора у лечењу овог типа повреда код деце, имајући у виду да конзервативни третман даје одличне резултате.

**Кључне речи:** дислокација; писиформна кост; деца