



CASE REPORT / ПРИКАЗ БОЛЕСНИКА

The treatment of hemangioma of the larynx in children is still a dilemma

Anđelka Stojković^{1,2}, Dragan Milovanović^{1,3}, Stevan Stojanović^{1,4}, Katerina Dajić¹, Zlatan Elek⁵, Maja Vulović⁶, Aleksandra Simović^{1,2}

¹University of Kragujevac, Faculty of Medicine, Department of Pediatrics, Kragujevac, Serbia;

²Clinical Centre of Kragujevac, Clinic of Pediatrics, Kragujevac, Serbia;

³Clinical Centre of Kragujevac, Department of Clinical Pharmacology, Kragujevac, Serbia;

⁴Clinical Centre of Kragujevac, Clinic for Otorhinolaryngology, Kragujevac, Serbia;

⁵Clinical Hospital Center, Department of Child Surgery, Kosovska Mitrovica, Serbia;

⁶University of Kragujevac, Faculty of Medicine, Department of Anatomy, Kragujevac, Serbia

SUMMARY

Introduction The laryngeal hemangioma in children is a benign vascular neoplasm but it could become malignant after localization.

Case outline After two weeks of corticosteroid treatment in a 15-month-old boy, there were no desired results. This case report is a small contribution to the research of targeted Propranolol treatment in infantile laryngeal hemangioma and the role of Epinephrine in the initial treatment in life-threatening conditions.

Conclusion When laryngeal hemangioma has "bad" localization and any surgical treatment is denied in spite of the vital risk, the choices of treatment are epinephrine (as the first choice) and propranolol.

Keywords: laryngeal disease; neoplasm; vascular tissue; child

INTRODUCTION

The hemangioma of the larynx in children is rare benign vascular neoplasm, which by its localization may have malign clinical course. Last year the American Academy of Pediatrics (AAP) made recommendations for the treatment of infantile hemangioma while calling for additional research of the treatment of hemangioma in the airways of young children [1].

CASE REPORT

We rarely encounter a larynx hemangioma, especially if there is no accompanying hemangioma of the skin [2]. However, we report a case of a male child aged 15 months with the diagnosis of larynx hemangioma. We were even more confused by the normal findings of fiberoptic laryngoscopy. However, the pediatricians had to treat the child until fiber-bronchoscopy was performed. The question is which drug to use? Which drug may contribute to a successful differential diagnosis of the mentioned condition in a primary health care, before fiber-bronchoscopy is done? Are the AAP recommendations absolutely relevant [1]?

A brief description of the clinical course of hemangioma of the larynx in a boy will be the basis for monitoring the treatment course and making conclusions. Before admission to the Pediatric Clinic, the 15-month-old boy had a cough, breathing difficulty and a fever of 38.6°C, which was treated by nebulized bron-

chodilator with fenoterol and ipratropium Bromide (FIB) and a steroid therapy (Table 1). On admission, the boy had signs of respiratory insufficiency. The majority of biochemical, hematological and microbiological analyses (Table 2) were within border references for his age [3]. At back-front chest X-ray in the projection of the larynx a hyperdense zone could be seen (Figure 1), asymmetrical, with successive extensions first to the left, then to the right, followed with air bronchogram and the strip-blotchy shadows in the lung parenchyma on both sides. The X-ray of the trachea in two directions and a contrast X-ray of the esophagus did not present any abnormal findings.

After three days of therapy (Table 1), a pediatrician considered that the child's condition was improving and did not need further epinephrine inhalation. However, about eight hours after epinephrine was excluded, his condition deteriorated. Since the finding of fiberoptic laryngoscopy to the borders of the larynx were a normal, fiberoptic bronchoscopy was performed (Table 1) as multidetector computed tomography (MDCT) (Figure 2). MDCT at the level of cervical vertebral body 2–3, on the left airway wall, discovered a thickening and hypodense, polypoid change, which asymmetrically narrowed the lumen of the border between the larynx and the trachea to a minimum diameter of under 2 mm. After that, Propranolol was introduced to the therapy, and after four days, oxygen therapy was no longer needed. After ten days of propranolol treatment, fiberoptic bronchoscopy was

Received • Примљено:
February 9, 2018

Revised • Ревизија:
August 20, 2018

Accepted • Прихваћено:
September 21, 2018

Online first: October 11, 2018

Correspondence to:

Anđelka STOJKOVIĆ
University of Kragujevac
Faculty of Medicine
Svetozara Markovića 69
34000 Kragujevac, Serbia
andja410@mts.rs

Table 1. The clinical course and treatment of hemangioma of the larynx in a boy with body weight of 9.5 kg

Level of health care	Primary care				Pediatric Clinic						Institute for Mother and Child Healthcare							
	1	2	3	4	5	6	7	8	9	10	11	12	13	14	15	16	17 con	
Day of treatment																		
Some clinical features and additional diagnostic findings per days	Day 1: cough, breathing difficulty, fever 38.6°C Day 2-3: cough, breathing difficulty Day 4: more powerful cough, hoarse, fever 38.8°C				Day 5: cough, dyspnoea, inspiratory stridor, pallor of skin and visible mucous membranes, fluttering nostrils, SaO ₂ 89-96% (according to the phase of the respiratory cycle and waking/sleeping child), RR 36/min, and HR 150/min. Apart from hyperglycemia (8.1 mmol/l), other biochemical, hematological and microbiological analyses were within border references for the child's age [3]. Back-front chest X-ray: in the projection of the larynx, a hyperdense zone could be seen, asymmetrical, with successive extensions first to the left then to the right, followed with air bronchogram and the strip-blotchy shadows in the lung parenchyma on both sides. Day 8: Improvement, then 8h after epinephrine was excluded there was deterioration: hard wheezing, alertness of the child, RR 56/min, SaO ₂ < 91% (irrespective of the phase of the respiratory cycle). Day 9: biphasic stridor, SaO ₂ < 89%, RR 28/min, HR 90/min. X-ray of the trachea in two directions and contrast x-ray of the esophagus did not present abnormal findings.						Day 12: Respiratory failure and inspiratory stridor continued to worsen; Fiberoptic bronchoscopy revealed a cystic tumor covered with normal mucous membrane color, capillary with a strong drawing, located under false vocal cords on both sides predominantly to the right, where it occupied the entire space between the anterior and posterior commissure, and left behind the last commissure with a tumor on the right almost completely obstructing aditus of larynx, leaving a breathing crack in the back commissure, which corresponds to the findings of hemangioma of the larynx. MDCT scanners neck and chest (native and with i.v. application of contrast medium); precisely determined the level of localization of lesions in C2-3 vertebral body, on the left wall, in the form of thickening and polypoid hypodense change which narrowed asymmetrically the lumen of the larynx to the smallest diameter of about 2 mm. Day 17: discharged home							
Drugs:																		
Oxygen	continuously																	
FIB, sol. (ml), nebulized	0.2/12h						0.2/6h		0.2/6h		0.2/6h		0.2/6h					
Salbutamol, sir.(ml), p.o	2.5/8h		2.5/8h						0.1/4h		0.1/4h							
Epinephrine 1:10000 (+ panthenol + saline) (mg/kg/dosis) nebulized					0.1/4h		0.1/4h											
Aminophylline, i.v. (mg/kg/8h)	3																	
Salbutamol, sol. (mg) nebulized	0.2/4h																	
Ipratropium bromide, sol. for inhalation (µg/kg)	5/4h																	
Magnesium sulfate, i.v. (mg/kg)	50/6h																	
Budesonide (µ/12h), nebulized	250	250	250	250	500	500	250	500	500	500	500	500	500	500	500	500	500	
Dexamethasone i.v. (mg/dosis/d divided in two doses)	8		8						3		3		3		3		3	
Methylprednisolone i.v. (mg/kg/d divided in three doses)	Azithromycin, p.o																	
Antibiotics	Clarithromycin, p.o																	
	Ceftriaxone, i.v.																	
Propranolol (mg/kg/d) divided in 2 doses, p.o.							2		2		2		2		2		2	2 con

FIB – fenoterol and ipratropium bromide; p.o. – orally; SaO₂ – percutaneous oxygen saturation; RR – respiratory rate; HR – heart rate; MDCT – multiple detector computed tomography; C – cervical; i.v. – intravenous; con – continued; ■ – interrupted

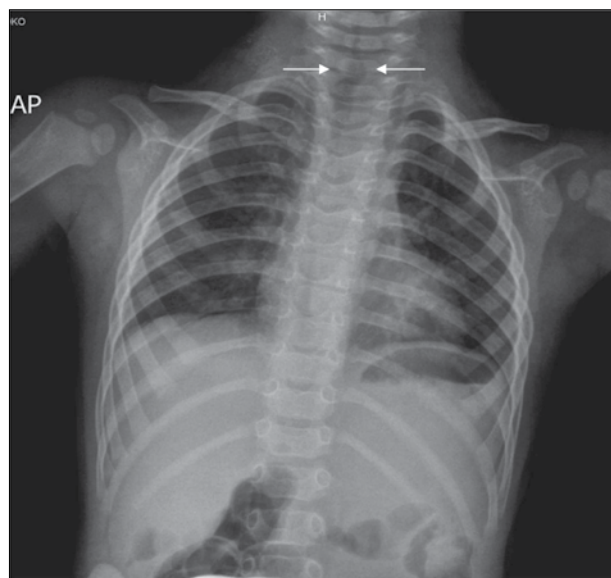


Figure 1. The chest X ray in the posterior anterior position of the 15-month-old boy (on admission)

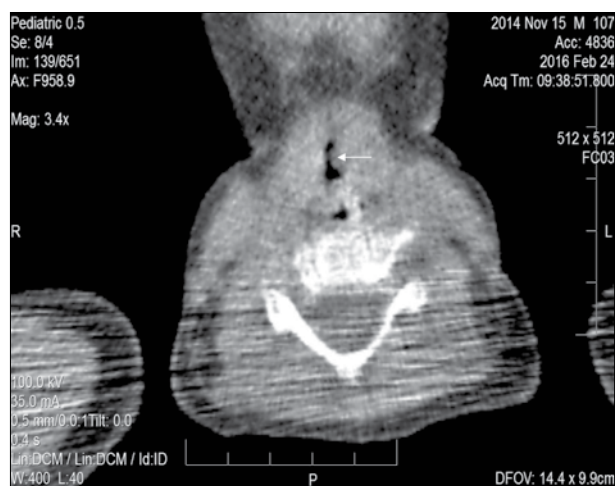


Figure 2. The multidetector computed tomography at the level of C2–3 vertebral body of the 15-month-old boy (4th hospitalization day) – on the left airway wall (arrow) discovered thickening/hypodense/polypoid change which narrowed asymmetrically the lumen of the border larynx/trachea to the smallest diameter of 2 mm

repeated revealing a significant reduction in tumor tissue and the reappearance of sufficient breathing space (Table 1). The child was discharged home with the same dose of Propranolol (for the total of six weeks), which resulted in recovery.

DISCUSSION

In a 15-month-old boy with hemangioma of the larynx, there was a good therapeutic response after administration of epinephrine and propranolol. There was no improvement of respiratory failure after the administration of corticosteroids (systemic not inhaled), which is recommended in many textbooks of pediatrics and is placed as the first therapeutic option for laryngeal hemangioma [2]. There was no desired therapeutic response after the administra-

Table 2. The 15-month-old boy's laboratory findings on admission to the Pediatric Clinic [2]

Gas analysis by Astrup from venous blood: pH 7.34, pO ₂ 5.7 kPa, pCO ₂ 5.9 kPa, sodium ionized 138 mmol/l, potassium ionized 4.3 mmol/l, calcium ionized 1.14 mmol/l, bicarbonate 24 mmol/l, base excess -2 mmol/l
Sedimentation rate 10, C-reactive protein 9.9 mg/l Complete blood count: WBC 5.1x10 ⁹ /l, neutrophils 0.53, lymphocyte 0.43, monocytes 0.05, PLT 267x10 ⁹ /l, RBC 4.64x10 ¹² /l, Hb 117 g/l, Hct 36%
Urinalysis – normal
Glycemia 8.1 mmol/l, magnesium 1 mmol/l, aspartate aminotransferase 42 U/l, alanine aminotransferase 17 U/l, urea nitrogen 4.6 mmol/l, creatinine enzymatic 46 μmol/l
Immunoglobulin (Ig) E 5.2 kIU/l, Vitamin D 25 ng/ml
Smear pharynx and nose, and aspirate – normal flora; IgM-mycoplasma pneumoniae – negative titer

WBC – white blood cells; RBC – red blood cells; PLT – thrombocytes

tion of a bronchodilator (beta-2-agonists, theophylline), or a broad-spectrum antibiotics (Cephalosporins 3rd generation, Macrolides). Epinephrine treatment in inhalation for three days resulted in clinical improvement. Epinephrine therapy was discontinued because no therapeutic protocol in pediatrics recommends the use of a multi-day inhalation of this drug [2].

Epinephrine causes vasoconstriction of arterioles and the dilatation of airway smooth muscle that in a short period of a few hours can impose beneficial effects on blood vessels in the hemangioma, and the dilatation of the larynx. However, systemic and daily use of epinephrine for seven days causes ischemic effect on the soft tissues, which is a powerful stimulus for neovascularization [4, 5]. This effect is not desirable in the treatment of hemangioma of the larynx, which leads us to think that epinephrine should be administered for a very short period, i.e. until the clinical improvement of respiratory insufficiency becomes definite. At the same time, the speed of therapeutic response to epinephrine helped us in the differential diagnosis of inspiratory stridor and a hoarse cough. The duration of epinephrine administration is not defined in the recommendations of the AAP, so future research is needed [1].

The peripheral effects of propranolol are used to “shrink” a hemangioma and to prevent the differentiation of infantile hemangioma stem cells to endothelial cells and pericytes [1, 6]. The recommendation is that the initial dose of propranolol *per os* for the larynx hemangioma would be the same like for skin hemangioma: 1–3.4 mg/kg/d with a gradual reduction in dose during 3–12 months, until the child reaches the age (8–12 months of age) when a spontaneous resolution of infantile hemangioma occurs [1, 2]. However, we have applied a dose of propranolol 2 mg/kg/d, continuously to the patient for six weeks only and achieved a complete resolution of hemangioma of the larynx without any side effects like drowsiness or hypoglycemia.

Despite the official recommendations concerning the effective application of steroids in the treatment of infantile hemangioma of the larynx, our experience was not positive [1, 2] (Table 1). Only after adding propranolol for four days, the need for oxygen was eliminated and the child

clinically recovered. During the six weeks of treatment, systemic steroid was not administered simultaneously with Propranolol, which is contrary to the recommendations, but it turned out to be the right and successful therapeutic approach [1, 2]. In life-threatening situations, with progressive deterioration of respiratory insufficiency of the child, parents and pediatricians do not have the patience to wait for prolonged effect of corticosteroids, which is achieved in the course of 4–12 weeks, but insist on a swift and targeted therapy of laryngeal hemangioma that is achieved by propranolol [1, 2]. Bearing in mind the so-called “bad” localization of hemangioma in the larynx, the classic surgical removal of hemangioma and/or the epinephrine application locally were not possible in this infant.

We wish to note outlooks of other pediatric institutions. The recommendation of one colleague from the Children's Hospital of Philadelphia does not include epinephrine, but has based his opinion exclusively on the effects of propranolol, corticosteroids (Intralesional), microdebrider excision, laser, and surgical therapy, all of which implies certain risks of such therapy [7]. American authors published a recommendation related to the therapeutic options

for infantile hemangioma, with the exception of the above noted, and the Interferon alfa-2band, a biologic immune response modifier, but not epinephrine [8]. French authors put propranolol as the first choice in the treatment of infantile laryngotracheal hemangioma, still suspecting in conclusion, about the unsuccessful treatment of this type of hemangioma with propranolol [9].

After two years of treatment of hemangioma of the larynx, a boy, now four years old, does not exhibit a stridor, but only wheezing as part of the clinical picture of asthma in a child under the age of five years. We shall continue to follow this child.

To conclude, we suggest epinephrine as the first choice in the therapy course for hemangioma of the larynx in children. The current pediatric recommendations suggest that the larynx hemangioma treatment of choice is propranolol, as this therapy lasts much shorter. Epinephrine and propranolol may be the treatment of choice when the surgical treatment is not indicated because of the life-threatening localization of hemangioma.

Conflict of interest: None declared.

REFERENCES

- Darrow DH, Greene AK, Mancini AJ, Nopper AJ. Diagnosis and Management of Infantile Hemangioma. *Pediatrics*. 2015; 136(4):e1060–104.
- Schroeder JW, Holinger LD. Congenital Anomalies of the Larynx, Trachea, and Bronchi. In: Kliegman MR, Stanton FB, St GemeWJ, Schor FN, Behrman ER. *Nelson textbook of pediatrics*. 20th ed. Elsevier; 2016; p. 2036–9.e3.
- Stanley LF. Reference intervals for laboratory tests and procedures. In: Kliegman MR, Stanton FB, St GemeWJ, Schor FN, Behrman ER. *Nelson textbook of pediatrics*, 20th ed. Elsevier; 2016. p. 3464–73.
- Karacaoğlu E, Çermik H, Yurdun T, Zienowicz RJ. Effect of long-term application of epinephrine on rat skin vasculature: experimental study. *Microsurgery*. 2002; 22(7):288–94.
- Masiha H, Nikpour HA, Hasani ME, Emami A, Jafari M, Manafi A. The synergistic effect of bleomycin, triamcinolone and epinephrine in treatment of hemangioma and arteriovenous malformations. *World J Plast Surg*. 2012; 1(2):83–90.
- Pan WK, Li P, Guo ZT, Huang Q, Gao Y. Propranolol induces regression of hemangioma cells via the down-regulation of the PI3K/Akt/eNOS/VEGF pathway. *Pediatr Blood Cancer*. 2015; 62(8):1414–20.
- Jacobs NI, Javia RL, Sobol ES, Zur BK. Subglottic Hemangiomas. 2018 The Children's Hospital of Philadelphia. Center for pediatric airway disorders. Buerger center for advanced pediatric care. Available at <http://www.chop.edu/conditions-diseases/subglottic-hemangiomas>
- Antaya JR, James DW, Wells JM, Perry V, Ortonne JP. Infantile Hemangioma Medication. *Medscape Medical News*. Available at <http://www.emedicine.medscape.com/article/1083849-medication#showall> Updated: Oct 02, 2017.
- Masiha H, Leboulanger N, Enjolras O, Harris R, Roger G, Garabedian EN. Role of Propranolol in the therapeutic strategy of infantile laryngotracheal hemangioma. *Int J Pediatr Otorhinolaryngol*. 2009; 73(8):1168–7.

Лечење хемангиома ларингса код деце је још увек дилема

Анђелка Стојковић^{1,2}, Драган Миловановић^{1,3}, Стеван Стојановић^{1,4}, Катерина Дајић¹, Златан Елек⁵, Маја Вуловић⁶, Александра Симовић^{1,2}

¹Универзитет у Крагујевцу, Факултет медицинских наука, Катедра за педијатрију, Крагујевац, Србија;

²Клинички центар Крагујевац, Клиника за педијатрију, Крагујевац, Србија;

³Клинички центар Крагујевац, Служба за клиничку фармакологију, Крагујевац, Србија;

⁴Клинички центар Крагујевац, Клиника за оториноларингологију, Крагујевац, Србија;

⁵Здравствени центар, Одељење дечје хирургије, Косовска Митровица, Србија;

⁶Универзитет у Крагујевцу, Факултет медицинских наука, Катедра за анатомију, Крагујевац, Србија

САЖЕТАК

Увод Хемангиом ларингса код деце је бенигна васкуларна неоплазма, али по локализацији може постати малигна.

Приказ болесника У току две недеље кортикостероидне терапије није било жељеног ефекта код дечака старог 15 месеци. Овај приказ болесника је мали допринос истраживању о хемангиому код деце и циљаној терапији пропранололом. Поред овога, расветлили смо улогу епинефрина

у иницијалној терапији хемангиома ларингса код животно угрожене деце.

Закључак Када хемангиом има „лошу“ локализацију и није индиковано хируршко лечење упркос виталном ризику, терапија избора су епинефрин (први избор) и пропранолол.

Кључне речи: обољење гркљана; неоплазма; васкуларно ткиво; дете