

ORIGINAL ARTICLE / ОРИГИНАЛНИ РАД

The influence of endothelial hyperplasia on pseudoprogression development in patients with glioblastoma

Marko Petrović¹, Rosanda Ilić², Mihailo Milićević², Miodrag Peulić¹, Danica Grujičić²¹Clinical Center Kragujevac, Center for Neurosurgery, Kragujevac, Serbia;²Clinical Center of Serbia, Neurosurgery Clinic, Belgrade, Serbia

SUMMARY

Introduction/Objective Pseudoprogression represents an enlarging contrast-enhancing lesion that occurs after chemoradiation and stabilizes with time without any changes in the therapeutic procedure. This phenomenon is highly significant, because it can have influence on further therapeutic procedures; however, precise criteria for pseudoprogression diagnosis have not yet been defined. The main goal of this study is to examine the endothelial hyperplasia influence on pseudoprogression.

Methods We analyzed a group of 106 patients with glioblastoma who had undergone surgical treatment from 2010–2012, at the Clinic of Neurosurgery, Clinical Center of Serbia, who received Stupp protocol. Pre- and post-treatment imaging was evaluated using RANO criteria. Lesions that improved or stabilized were defined as pseudoprogression, and lesions that progressed were defined as true progression. Endothelial hyperplasia was identified based on the hematoxylin and eosin pathohistological examination.

Results Thirty-two (30.2%) of the patients were diagnosed with pseudoprogression. Endothelial hyperplasia was observed in 51 (48.1%) of glioblastoma tissue samples, and 28 (87.5%) of all the patients with pseudoprogression were found to have endothelial hyperplasia. The group of 51 (68.9%) patients without pseudoprogression did not show the presence of endothelial hyperplasia. Statistical analysis showed significantly higher incidence of pseudoprogression in patients with endothelial hyperplasia. ($\chi^2 = 26.269$, $p < 0.01$)

Conclusion Taking into account that there are no precise diagnostic methods that could determine the presence of endothelial hyperplasia with certainty, it could be an indicator, as a pathohistological entity, of a higher likelihood of pseudoprogression, which could be used in everyday clinical practice. In order to reach definite conclusions, we believe it is necessary to conduct prospective controlled studies with larger sample sizes.

Keywords: glioblastoma; endothelial hyperplasia; pseudoprogression

INTRODUCTION

Pseudoprogression represents new or enlarging contrast enhancing lesion after chemotherapy within the radiation field that stabilizes with time without any changes in the therapeutic procedure [1]. This phenomenon is highly significant, because it mimics true tumor progression and, if it is misinterpreted as such, it can have a negative influence on the further therapeutic procedures. Pseudoprogression is commonly seen in asymptomatic patients. However, some patients present with clinical deterioration. These complications can include worsening of pre-existing symptoms, transient cognitive decline, subacute rhombencephalitis, or somnolence syndrome [2].

The pathophysiological basis of pseudoprogression remains poorly understood. There are certain indications that it is part of the spectrum of radiation-induced changes ranging from subacute radiation-induced changes to late radiation necrosis [3]. It is assumed that there are two components of pseudoprogression: vascular injuries and treatment-related

cell toxicity [4]. It is thought that transient breakdown of the blood brain barrier can cause the edema and contrast enhancement seen on the magnetic resonance imaging (MRI) [5]. The cells most sensitive to radiation are oligodendrocytes, endothelial cells, and neural precursors. Cellular damage can lead to cell death including p53 and p53-independent mechanisms of apoptosis.

Pathohistological examination of patients operated because of pseudoprogression showed distinct characteristics. On the microscopic level, tumor recurrence is usually characterized by microvascular proliferation and highly cellular tumor tissue. This is contradictory to the histological characteristics of the contrast enhancing tissue of pseudoprogression that usually has a low cellularity. Typically, pleomorphic tumor cells can also be found in these lesions with the low mitotic index. In addition, elements of coagulative necrosis can be found, and it appears eosinophilic on light microscopy. Hyalinization of the wall of blood vessels and fibrinoid necrosis is frequent. Telangiectatic blood vessels may be seen, though they are less specific. Fibrillary

Received • Примљено:

August 1, 2018

Revised • Ревизија:

January 15, 2019

Accepted • Прихваћено:

March 5, 2019

Online first: March 21, 2019

Correspondence to:

Marko PETROVIĆ
Kapetana Lukića 18
34000 Kragujevac, Serbia
markopetrovickg@yahoo.com

and gemistocytic astrocytes may be observed as well. Scattered pleomorphic astrocytes are mostly associated with the tumor exposed to radiation and are often present in the tissue obtained from pseudoprogression [6].

The accurate diagnosis of pseudoprogression from the true tumor progression is of great significance in planning of further treatment [7]. Modern techniques and MR sequences are developed with the goal of differentiating pseudoprogression and true tumor progression. Diffusion-Weighted Imaging, Diffusion-Tensor Imaging, Perfusion-Weighted Imaging and MR spectroscopy can be helpful, but are not conclusive. Positron Emission Tomography combined with other specific biomarkers is also used along with MRI. However, neither one of the abovementioned methods can be used for diagnosing any pseudoprogression-related changes with certainty.

In this paper, we have examined if endothelial hyperplasia, being one of pathohistological features of glioblastoma, affects the development of pseudoprogression in patients with glioblastoma.

METHODS

We used a retrospective analysis of prospectively collected data in order to analyze the patients with glioblastoma who had undergone surgical treatment during the three-year period (2010–2012), at the Clinic of Neurosurgery, Clinical Center, Serbia and who received Stupp protocol after the surgery. The patients were monitored by a series of MRI scans. While making the final diagnosis, we used the RANO criteria, taking into consideration the fact, established after the numerous literature data, that pseudoprogression may even occur 12 weeks after the chemoradiation has been completed.

Statistical methods

IBM SPSS Statistics, Version 20.0 (IBM Corp., Armonk, NY, USA) was used for all calculations in the study. Specific measures of central tendency and variability measures were found for continual variability whereas the frequency of the separate categories was specified for the categorical variables. A chi-square test was used for examining the factors that have an influence on pseudoprogression development. The maximum level of acceptability of the null hypothesis probability used in our study is 0.05. The conducted study was approved by the Ethics Committee of the Clinical Centre of Serbia.

RESULTS

A total of 106 patients with glioblastoma who underwent surgery in the period from January 1, 2010 to December 31, 2012 and who underwent Stupp protocol were included in this study. Thirty-two (30.2%) patients were diagnosed with pseudoprogression, whereas 74 (69.8%) of the patients showed no signs of pseudoprogression. On average, pseudoprogression was observed after 4.64 months.

In the group of the patients with pseudoprogression, 59.4% of them were men and 40.6% were women, whereas in the group of the patients with no pseudoprogression, 54.1% of them were men and 45.9% were women. In the group of the patients with pseudoprogression, the average age of patients was 53.03 ± 10.14 years, while in the group of the patients with no signs of pseudoprogression the average age was 53.99 ± 12.53 years. The highest number of patients with developed pseudoprogression was found in the age group ranging from 51–60 years (53.1%), whereas the least number was found in the age group ranging from 71–80 years (3.1%). The greatest number of patients had a radical operation: 74 (70.2%), and out of them 19 patients (17.2%) had subtotal resection, 12 (11.5%) patients had the tumor reduction, whereas there was only one biopsy and that patient was excluded from further analysis (1.1%). Pseudoprogression occurred in 15 (46.7%) of the patients who had received the radical surgery, it occurred in 11 cases (33.3%) of the patients who had had subtotal tumor resection, whereas six (20%) of the patients with pseudoprogression had the tumor reduction. The influence of a degree of tumor resection on the incidence of pseudoprogression was not significant ($\chi^2 = 5.493$, $p = 0.139$).

Endothelial hyperplasia was observed in 51 (48.1%) of glioblastoma tissue samples. Twenty-eight (87.5%) of all patients with pseudoprogression were found to have endothelial hyperplasia, whereas four patients (12.5%) were without it. Fifty-one (68.9%) patients who were not diagnosed with pseudoprogression did not show the presence of endothelial hyperplasia either, whereas it was shown that 23 (31.1%) of the patients who were not diagnosed with pseudoprogression had endothelial hyperplasia. In the group of patients who developed pseudoprogression, the number of patients who had endothelial hyperplasia described in their pathohistological findings was statistically significantly higher, whereas there were more patients who were not diagnosed with pseudoprogression and who did not have endothelial hyperplasia. ($\chi^2 = 26.269$, $p < 0.01$)

DISCUSSION

Pseudoprogression occurred in 32 patients (30.2%). When we compared our results with the literature data, we found the heterogeneity in the data related to the incidence of pseudoprogression [8, 9, 10]. The study undertaken in 2017, which included the papers written in the period from 2005 to October 8, 2014 due to the meta-analysis, published that pseudoprogression was present in 36% of patients [11]. The reason for this may be found in various criteria for its defining along with the fact that the results of a specific number of papers were based on small sample sizes. In our study, we used the RANO criteria for defining the pseudoprogression (Figure 1). However, we carefully approached one specific piece of information related to the incidence of pseudoprogression occurring even within 12 weeks after completing chemo-irradiation, because of various literature data claiming that pseudoprogression can be observed much later and that it can be observed

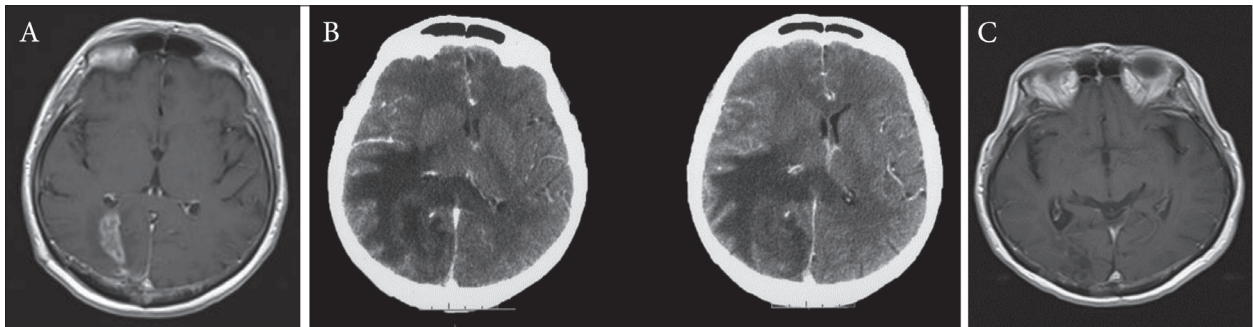


Figure 1. A – The first endocranial magnetic resonance imaging after treatment, radiological progression without clinical deterioration; B – endocranial computed tomography scan after two months, extensive edema followed by clinical deterioration; C – complete regression after corticosteroid therapy and continuing with chemotherapy

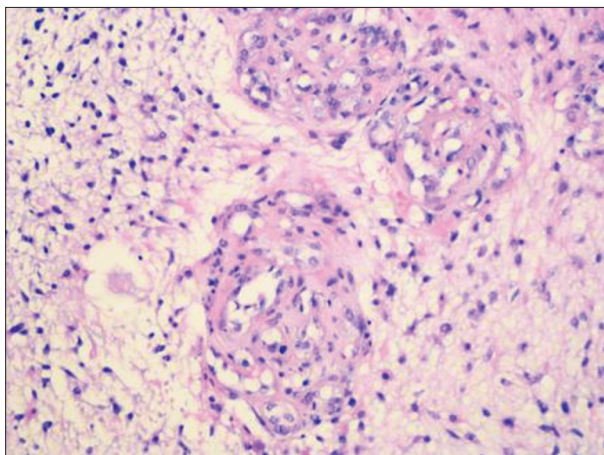


Figure 2. Endothelial hyperplasia, formation of glomeruloid structures

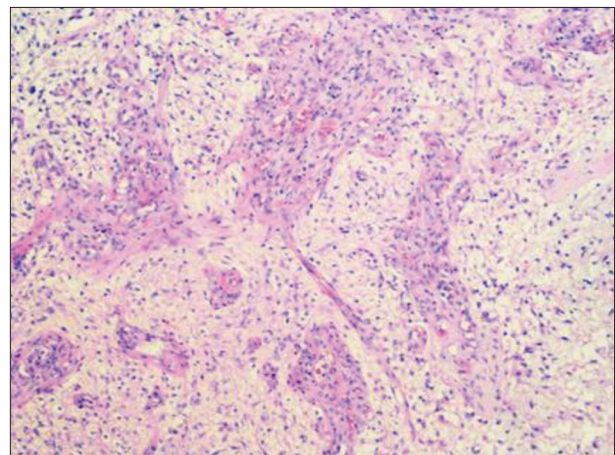


Figure 3. Endothelial hyperplasia and necrosis

even later than 40 weeks and more [12, 8]. Our research demonstrated that pseudoprogression occurred on an average of 4.64 months. The highest number of patients with pseudoprogression was found in the age group ranging from 51–60 years, and then in the age group ranging from 61–70 years. In a study published by Chu et al. [13], the average age of the patients with pseudoprogression was 46.66 ± 15.34 years, which is similar to the results obtained in our study. Endothelial hyperplasia, commonly characterized by the formation of glomeruloid structures, represents one of the main characteristics of glioblastoma (Figure 2). It is usually located in the vicinity of necrosis and appears directionally oriented to it (Figure 3). After the analysis of all the scientific papers published so far, we have not been able to find the results dealing with the influence of endothelial hyperplasia on pseudoprogression development. The results obtained in our study demonstrated that pathohistological characteristics such as endothelial hyperplasia, are statistically significantly higher in the patients developing pseudoprogression. This phenomenon could be primarily explained in terms of disturbing the integrity and normal functions of the blood-brain barrier (BBB). Namely, one of the pathophysiological mechanisms explaining the incidence of pseudoprogression is increased permeability of the BBB [5]. The BBB is an extremely important structure that maintains the balance of the central nervous system (CNS) microenvironment and maintains the normal functioning of the brain. The BBB

is constituted of endothelial cells, astrocytes, peripheral cells, macrophage, fibroblasts, neuronal cells, basement membranes, microglia, and other cell types. There are many transporters on the BBB, including P-glycoprotein (P-gp). Astrocytes are involved in nerve signal transmission, nutrient transport, maintaining the balance of brain microenvironment and extracellular matrix ion balance buffering. Peripheral cells are multifunctional cells, with immune function in the CNS neurovascular unit. Peripheral cells surround the endothelial cells and play an important role in the BBB microenvironment and in maintaining the BBB function by secreting growth factors and extracellular matrix. Microglia are a kind of long-standing immune cell in the human brain. They can stimulate the opening of BBB, leukocyte extravasation, and angiogenesis. Fibroblasts, when co-cultured with glioblastoma cells, can induce production and activation of matrix metalloproteinase MMP2, and its activators membrane type 1 metalloproteinase (MT1-MMP) and MT2-MMP, which affect the growth progression of gliomas. Other cells, like endothelial cells, in the BBB microenvironment maintain the normal function and integrity of the BBB by forming tight junctions that limit transcytosis. CNS neurons bind chemicals and convey electrical signals. They can regulate the ionic microenvironment of the synaptic and axonal regions of the nerve cell, which are essential to the nerve signal transduction. The basement membrane is attached as a support tissue to the neurovascular unit cells. The

endothelial cell is the most important structural component of the BBB. Changes in the phosphorylation state of the tight junction protein (ZO-1 or occluding) are critical to the control of BBB vascular permeability. In areas of tumor environment, the endothelial cells connection is very loose and almost lacks integrity [14]. Endothelial hyperplasia is a frequent finding in glioblastoma and it is connected with an increase in nonselective transport through the BBB [15]. The major changes reflect in an increased number of endothelial cells, endothelial hyperplasia leading to function loss and volume reduction in the endothelial cells, cell form changes, tight junction damage, an increased number of vesicles, caveolae and fenestrations, the basement membrane thickening, perivascular space expansion, and the necrosis of capillary endothelial cells [16–19]. All the above-mentioned changes lead to BBB degradation. A significant degradation of the integrity and an increase in the BBB permeability in patients with endothelial hyperplasia may be the cause of contrast leaking the blood vessels, which may eventually induce radiology changes described under the notion of pseudoprogession.

REFERENCES

- Gahramanov S, Raslan AM, Muldoon LL, Hamilton BE, Rooney WD, Varallyay, et al. Potential for differentiation of pseudoprogession from true tumor progession with dynamic susceptibility-weighted contrast-enhanced magnetic resonance imaging using ferumoxytol versus gadoteridol: a pilot study. *Int J Radiat Oncol Biol Phys.* 2011; 79(2):514–23.
- Fink J, Born D, Chamberlain MC. Radiation necrosis: Relevance with respect to treatment of primary and secondary brain tumors. *Curr Neurol Neurosci Rep.* 2012; 12(3):276–85.
- Huang RY, Neagu MR, Reardon DA, Wen PY. Pitfalls in the neuroimaging of glioblastoma in the era of antiangiogenic and immuno/targeted therapy - detecting illusive disease, defining response. *Front Neurol.* 2015; 6:1–16.
- Herbert B. Newton. *Handbook of Neuro-oncology Neuroimaging.* 2nd ed. USA: Academic Press; 2016.
- Yaman E, Buyukberber S, Benekli M, Oner Y, Coskun U, Akmansu M, et al. Radiation induced early necrosis in patients with malignant gliomas receiving temozolomide. *Clin Neurol Neurosurg.* 2010; 112(8):662–7.
- Woodworth GF, Garzon-Muvdi T, Ye X, Blakeley JO, Weingart JD, Burger PC. Histopathological correlates with survival in reoperated glioblastomas. *J Neurooncol.* 2013; 113(3):485–93.
- Young RJ, Gupta A, Shah AD, Graber JJ, Chan TA, Zhang Z, et al. MRI perfusion in determining pseudoprogession in patients with glioblastoma. *Clin Imaging.* 2013; 37(1):41–9.
- Stuplich M, Hadizadeh DR, Kuchelmeister K, Scorzin J, Filss C, Langen KJ, et al. Late and prolonged pseudoprogession in glioblastoma after treatment with lomustine and temozolomide. *J Clin Oncol.* 2012; 30(21):180–3.
- Linhares P, Carvalho B, Figueiredo R, Reis RM, Vaz R. Early Pseudoprogession following Chemoradiotherapy in Glioblastoma Patients: The Value of RANO Evaluation. *J Oncol.* 2013; 5:690585
- Brandes AA, Franceschi E, Tosoni A, Blatt V, Pession A, Tallini G, et al. MGMT promoter methylation status can predict the incidence and outcome of pseudoprogession after concomitant radiochemotherapy in newly diagnosed glioblastoma patients. *J Clin Oncol.* 2008; 26(13):2192–7.
- Abbasi AW, Westerlaan HE, Holtman GA, Aden KM, van Laar PJ, van der Hoorn A. Incidence of Tumour Progession and Pseudoprogession in High-Grade Gliomas: a Systematic Review and Meta-Analysis. *Clin Neuroradiol.* 28(3):401–11.
- Chaskis C, Neyns B, Michotte A, De Ridder M, Everaert H. Pseudoprogession after radiotherapy with concurrent temozolomide for high-grade glioma: clinical observations and working recommendations. *Surg Neurol.* 2009; 72(4):423–8.
- Chu HH, Choi SH, Ryoo I, Kim SC, Yeom JA, Shin H, et al. Differentiation of True Progession from Pseudoprogession in Glioblastoma Treated with Radiation Therapy and Concomitant Temozolomide: Comparison Study of Standard and High-*b*-Value Diffusion-weighted Imaging. *Radiology.* 2013; 269(3):831–40.
- Zhao X, Chen R, Liu M, Feng J, Chen J, Hu K. Remodeling the blood-brain barrier microenvironment by natural products for brain tumor therapy. *Acta Pharm Sin B.* 2017; 7(5):541–53.
- Vajkoczy P, Menger MD. Vascular microenvironment in gliomas. *J Neurooncol.* 2000; 50(1–2):99–108.
- Hellinger É, Veszelka S, Tóth AE, Walter F, Kittel Á, Bakk ML, et al. Comparison of brain capillary endothelial cell-based and epithelial (MDCK-MDR1, Caco-2, and VB-Caco-2) cell-based surrogate blood-brain barrier penetration models. *Eur J Pharm Biopharm.* 2012; 82(2):340–51.
- Veszelka S, Tóth AE, Walter FR, Datki Z, Mózes E, Fülöp L, et al. Docosahexaenoic acid reduces amyloid- β induced toxicity in cells of the neurovascular unit. *J Alzheimer's Dis.* 2013; 36(3):487–501.
- Jähne EA, Eigenmann DE, Culot M, Cecchelli R, Walter FR, Deli MA, et al. Development and validation of a LC-MS/MS method for assessment of an anti-inflammatory indolinone derivative by in vitro blood-brain barrier models. *J Pharm Biomed Anal.* 2014; 98:235–46.
- Tóth AE, Walter FR, Bocsik A, Sántha P, Veszelka S, Nagy L, et al. Edaravone protects against methylglyoxal-induced barrier damage in human brain endothelial cells. *PLoS One.* 2014; 9(7):1–14.

CONCLUSION

Pseudoprogession is a phenomenon of great clinical significance. Distinguishing pseudoprogession from true tumor progession has significant influence on further treatment of patients with glioblastoma. Considering the fact that no accurate diagnostic method has been found so far due to which it would be possible to undoubtedly confirm the presence of pseudoprogession, the presence of endothelial hyperplasia as a pathohistological entity could be an indicator of a higher likelihood of pseudoprogession, which could be used in everyday clinical practice. Nevertheless, in order to reach definite conclusions, we believe it is necessary to conduct prospective controlled studies with larger sample sizes.

NOTE

This paper is based on Dr. Marko Petrović's PhD thesis.

Conflict of interest: None declared.

Утицај ендотелијалне хиперплазије на појаву псеудопрогресије код болесника са глиобластомом

Марко Петровић¹, Росанда Илић², Михаило Милићевић², Миодраг Пеулић¹, Даница Грујичић²

¹Клинички центар Крагујевац, Центар за неурохирургију, Крагујевац, Србија;

²Клинички центар Србије, Клиника за неурохирургију, Београд, Србија

САЖЕТАК

Увод/Циљ Псеудопрогресија представља појаву лезије која се пребојава контрастом после хемоирадијације и која не прогредира или се повлачи без промене терапије. Сам феномен има изразит клинички значај зато што у великој мери утиче на даље терапијске поступке, али критеријуми за њено дијагностиковање још увек нису јасно дефинисани. Циљ овог истраживања је испитивање утицаја ендотелијалне хиперплазије на настанак псеудопрогресије.

Методe Испитивано је 106 болесника који су оперисани због глиобластома у Клиничком центру Србије у периоду од 2010. до 2012. године, и који су после тога лечени Ступовим протоколом. Снимање пре и после лечења је утврђено критеријумом *RANO*. Промене које су биле стабилне или су се повукле дефинисане су као псеудопрогресија, док су лезије које су прогредирале окарактерисане као праве прогресије. Ендотелијална хиперплазија је утврђена после патохистолошког прегледа хематоксилином и еозином.

Резултати Псеудопрогресија је регистрована код 32 (30,2%) болесника. Код 51 (48,1%) узорка ткива глиобластома уочена

је ендотелијална хиперплазија. Од свих болесника код којих је регистрована псеудопрогресија, њих 28 (87,5%) имало је ендотелијалну хиперплазију. Код болесника који нису имали псеудопрогресију, њих 51 (68,9%) није имало ни ендотелијалну хиперплазију. Код болесника који су испољили псеудопрогресију било је значајно више болесника који су у патохистолошком налазу имали описану и ендотелијалну хиперплазију, док код болесника без псеудопрогресије има више случајева без ендотелијалне хиперплазије ($\chi^2 = 26,269$, $p < 0,01$).

Закључак С обзиром на то да за сада не постоји прецизна дијагностичка метода која би са сигурношћу утврдила да ли се ради о псеудопрогресији, присуство ендотелијалне хиперплазије би могло да укаже на већу вероватноћу појаве псеудопрогресије, што би се могло користи у свакодневном клиничком раду. Ипак, ради доношења дефинитивних закључака, сматрамо да је неопходно спровести проспективне контролисане студије на већем узорку.

Кључне речи: глиобластом; ендотелијална хиперплазија; псеудопрогресија