

## ORIGINAL ARTICLE / ОРИГИНАЛНИ РАД

# Treatment of slipped capital femoral epiphysis – a comparative study during a twelve-year period

Bojan Bukva<sup>1</sup>, Siniša Dučić<sup>1</sup>, Vladimir Radlović<sup>1</sup>, Goran Vrgoč<sup>2</sup>, Branislav Krivokapić<sup>3</sup>, Igor Jelaska<sup>4</sup>, Petra Mandić-Jelaska<sup>4</sup>

<sup>1</sup>University Children's Hospital, Department of Pediatric Orthopaedic Surgery, Belgrade, Serbia;

<sup>2</sup>Sveti Duh University Hospital, Department of Orthopaedic Surgery, Zagreb, Croatia;

<sup>3</sup>Banjica Institute for Orthopaedic Surgery, Belgrade, Serbia;

<sup>4</sup>University of Split, Faculty of Kinesiology, Split, Croatia



## SUMMARY

**Introduction/Objective** The purpose of this study was to compare two methods of treatment and to evaluate the advantages in the final outcome of transcervical fixation of the femoral head using one cannulated screw in the treatment of slipped capital femoral epiphysis.

**Methods** This study included 65 pediatric patients (35 boys and 30 girls), aged 6–16 years (average 11.86), during a 12-year period (2000–2012). We compared the slipping degree before and after the treatment (Southwick angle), the range of motion before and after treatment, and complication occurrence between two groups of children. The first group of children (26 patients) underwent closed reduction and cast immobilization (Group I). The other group (39 patients) was treated with transcervical fixation using one cannulated screw (Group II).

**Results** Comparing preoperative and postoperative Southwick angle, we found much better improvement in Group II, but without statistical significance between the two groups of patients ( $p = 0.09$ ). Observing the range of motion of the hips before and after treatment, we found improvement in both groups of patients, especially in patients treated using transcervical fixation with cannulated screw (Group II). In complication occurrence, the patients in Group II had less complication occurrence compared to Group I ( $p = 0.02$ ).

**Conclusion** The transcervical fixation using one cannulated screw has better clinical outcome and lower complication rate in relation to closed reduction and cast immobilization in the treatment of slipped capital femoral epiphysis.

**Keywords:** transcervical fixation; cannulated screw; closed reduction

## INTRODUCTION

Slipped capital femoral epiphysis (SCFE) is the most common hip disorder in adolescence, especially in obese adolescents. It occurs in 0.2–10 per 100,000 children [1]. Also, it could be connected to endocrinological disorders, especially hypothyroidism and hyperparathyroidism [2, 3]. Etiology of SCFE is still unknown, but it is obvious that mechanical, endocrinological, and genetic factors during adolescence cause SCFE [4–11]. It has been classified according to symptom duration, weight ability, and radiographic degree of slip. SCFE can be bilateral in approximately in 20–25% of cases [12, 13].

Complications of SCFE can be early and late. Early complications are rare. Avascular necrosis (AVN) and chondrolysis are the most serious and most common late complications of SCFE. AVN is related to insufficient blood supply to the femoral neck and head after the proximal femoral epiphysis slips [4]. Epiphyseal slip severity correlates directly to late complications' occurrence [4, 7, 13].

Various procedures have been described in the treatment of SCFE: closed reduction (CR)

and cast immobilization, minimal invasive surgery and percutaneous fixation or femoral osteotomies and osteosynthesis.

Prophylactic stabilization of the contralateral hip is still controversial [14, 15, 16].

The aim of this study was to compare two methods of treatment of SCFE and to evaluate the advantages of transcervical fixation of the femoral head using one cannulated screw in the final outcome.

## METHODS

This retrospective study included 65 pediatric patients (35 boys and 30 girls), aged 6–16 years (average 11.86), over a 12-year period (2000–2012). Observation period was in the range of six months to 12 years (average 6.83 years). We compared the slipping degree angle before and after treatment (Southwick angle), range of motion (ROM) of the hip before and after treatment, and complications' occurrence between two groups of children [15, 16]. The first group underwent CR and cast immobilization (Group I). Group I included 26 patients (12 boys and 14 girls). The other group (Group II) was treated

**Received • Примљено:**

May 21, 2018

**Revised • Ревизија:**

January 22, 2019

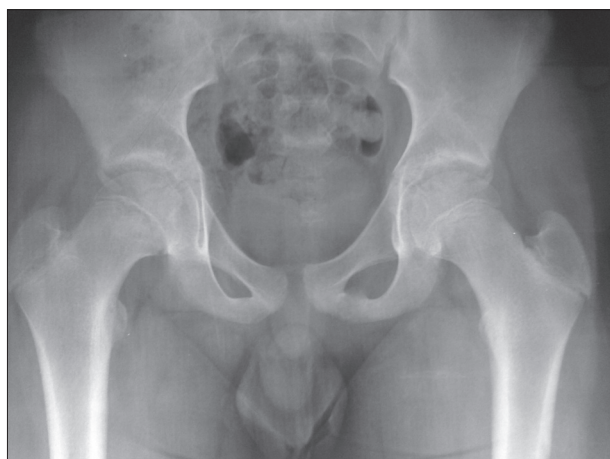**Accepted • Прихваћено:**

January 22, 2019

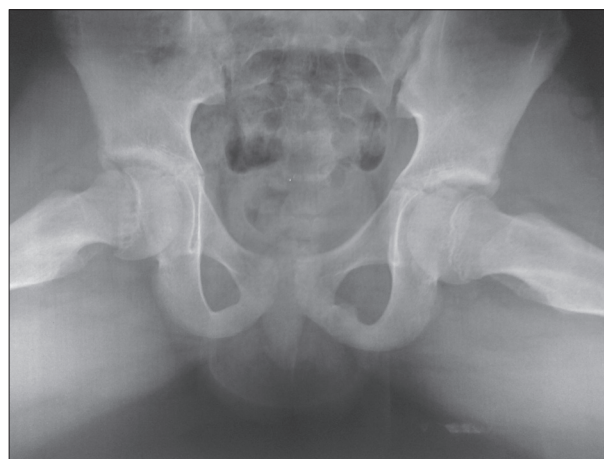**Online first:** February 5, 2019

**Correspondence to:**

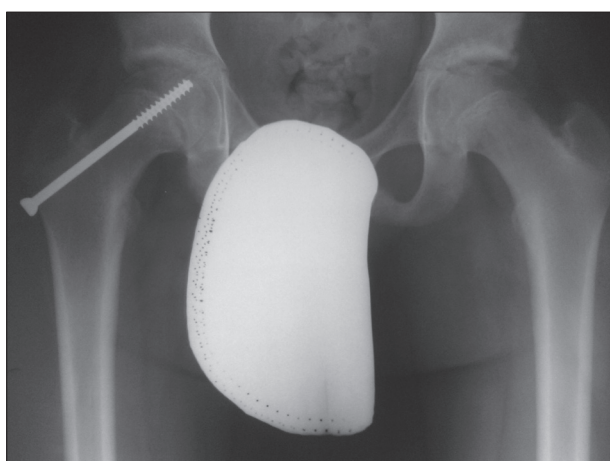
Bojan BUKVA  
University Children's Hospital  
10 Tiršova Str.  
Belgrade 11000, Serbia  
[bojanbukva@yahoo.com](mailto:bojanbukva@yahoo.com)



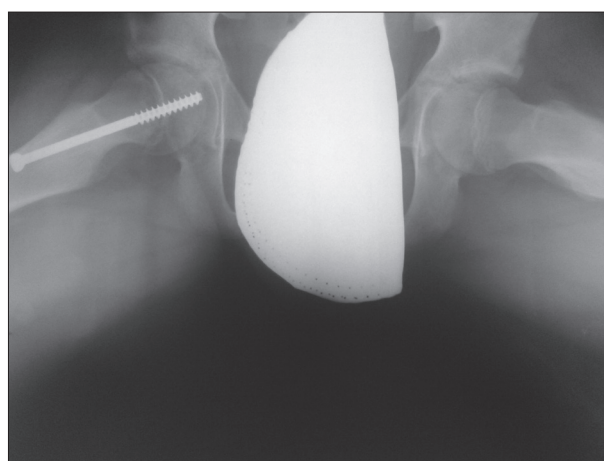
**Figure 1.** Anteroposterior view of slipped capital femoral epiphysis (right hip affected) before treatment



**Figure 2.** “Frog leg” view of slipped capital femoral epiphysis (right hip affected) before treatment



**Figure 3.** Anteroposterior view of slipped capital femoral epiphysis after treatment with transcervical fixation using one cannulated screw (4 mm diameter)



**Figure 4.** “Frog leg” view of slipped capital femoral epiphysis after treatment with transcervical fixation using one cannulated screw (4 mm diameter)

with percutaneous pinning using one cannulated screw. This group included 39 patients (23 boys and 16 girls). We observed various types of SCFE according to slip duration, slipping degree, and slip instability. According to SCFE types, in our study, acute slips (less than three weeks' duration) were present in 6/26 (23.08%) patients in Group I, and in 11/39 (28.21%) patients in Group II. According to weight ability, stable slips dominated in both groups – in Group I in 20/26 (76.92%) and in Group II in 33/30 (81.54%) patients. Stable slips include slips where patients can walk (with or without crutches), in contrast to unstable ones, where patients experience pain severe enough to prevent walking even with crutches. Five patients had an endocrinological contribution in SCFE – 3/26 (11.54%) in Group I and 2/39 (5.13%) in Group II. Bilateral involvement was found in 7/65 patients (10.77%).

We observed radiological and clinical outcome in patients with SCFE. The Southwick angle is the radiological parameter in SCFE we observed. It is measured bilaterally in anteroposterior and “frog leg” view, by drawing a line perpendicular to the epiphyseal line (connecting the points at anterior and posterior tips of the epiphysis) and the femoral shaft angle. The final result of the slip is ob-

tained by subtraction from the angle of the unaffected side and is expressed in angle degrees. The clinical outcome we observed was the ROM of the hip before and after the treatment: flexion, abduction, external and internal rotation. For evaluation we used goniometer; the results are expressed in angle degrees. Also, we evaluated the complication occurrence in the observed patients. They can be early (pain, infection, malfixation) or late (avascular necrosis, chondrolysis, re-slip).

The exclusion criteria in this study were metabolic and blood vessel diseases, patients on chemo- or radiotherapy, and patients with bone dysplasia or bone tumors of the proximal femur.

Reference data was selected according to history data, clinical findings, and radiography of hips in anteroposterior and “frog leg” position.

The study was done in accord with standards of the institutional committee on ethics.

#### **Treatment procedure and postoperative treatment**

Both groups were initially treated with percutaneous traction over a period of two weeks. The traction was

applied progressively in abduction and internal rotation (with 10% of the patient's total weight on each leg). After percutaneous traction period, Group I was treated with CR and cast immobilization using maneuver according to Whitman, which means fixed position of the contralateral hip in maximal abduction (about 70°) and progressive increase of abduction (about 60°) and internal rotation (about 20°) of the affected hip and immobilization in hip spica cast [2, 4]. The cast was removed after six weeks, which was followed by physical therapy (kinesiotherapy), with progressive weight bearing (up to full-weight bearing three months after the cast removal).

The other group of patients (Group II) was treated using transcervical fixation with one cannulated screw. The patients were in the supinated position with leg in slight extension, abduction, and internal rotation. Under the C-arm fluoroscopy control, two Kirschner wires (K-wires) were inserted starting from the base of the neck to epiphysis of the proximal femur. The K-wires were used as "guides" for the cannulated screw. Before cannulated screw insertion, we performed a small 2-cm skin incision and drilling over the K-wires. After the cannulated screw was inserted, the K-wires were extracted and fluoroscopy control was done in the anteroposterior and "frog leg" position. Average cannulated screw diameter was 4 or 4.5 mm (according to the patient's age). Physical therapy started two days after the surgery, with progressive weight bearing.

Radiography was done immediately after treatment (for Group I before cast removal), three months after the treatment, and in six-month intervals up to two years after treatment. After two years, radiographic control was done annually.

### Statistical interpretation

In statistical interpretation we used descriptive and analytic methods of statistical analysis. For the estimation of statistical differences between evaluated groups we used Pearson's  $\chi^2$  test, Fisher's exact test, Wilcoxon rank-sum test with continuity correction, and Mann-Whitney U test. Statistical significance was set at  $p \leq 0.05$ .

## RESULTS

This retrospective study included 65 pediatric patients divided into two groups, depending on the method of treatment: CR and cast immobilization (Group I) or transcervical fixation using one cannulated screw (Group II). We found statistically significant differences between Group I and Group II concerning the age and body weight ( $p < 0.05$ ) of participants, as Table 1 indicates.

Average symptom duration period for Group I was 61.77 days (range 2–180), while it was 50.72 days (range 3–180) for Group II. We found no statistical significance in symptom duration period between the two groups of patients ( $p = 0.316$ ). Also, we found no statistical significance in side affection ( $p = 0.0655$ ).

**Table 1.** Patient analysis according to sex, age, and body mass depending on the method of treatment

Parameter	Group I**	Group II***	Test
<b>Sex</b>			
male	12 (46.15%)	23 (58.97%)	Pearson's $\chi^2$ test $\chi^2_1 = 1.0317$ ; $p = 0.3097$
female	14 (53.85%)	16 (41.03%)	
<b>Age (years)</b>			
average (SD*)	10.74 (4.27)	11.87 (4.49)	Wilcoxon rank sum test with continuity correction $W = 358$ ; $p = 0.0431$
median (range)	11 (4–18)	12 (3–18)	
<b>Body mass (kg)</b>			
average (SD*)	52.85 (13.94)	66.56 (16.89)	Wilcoxon rank sum test with continuity correction $W = 277$ ; $p = 0.0021$
median (range)	54 (17–78)	65 (34–100)	

\*Standard deviation;

\*\*patients treated with closed reduction and casting (Whitman method);

\*\*\*patients treated using percutaneous pinning using one cannulated screw

**Table 2.** Type of slipped capital femoral epiphysis (SCFE) related to the method of treatment

Type of SCFE	Group I*	Group II**	Total	Pearson's $\chi^2$ test
Acute SCFE	6 (23.08%)	11 (28.21%)	17 (26.15%)	$p = 0.64488$
Chronic SCFE	20 (76.92%)	28 (71.79%)	48 (73.85%)	
Total	26 (100%)	39 (100%)	65 (100%)	

\*Patients treated with closed reduction and casting (Whitman method);

\*\*patients treated with percutaneous pinning using one cannulated screw

**Table 3.** Presentation of weight ability (stable vs. unstable) in slipped capital femoral epiphysis (SCFE) depending on the method of treatment

Weight ability in SCFE	Group I*	Group II**	Total	Pearson's $\chi^2$ test
Stable	20 (76.92%)	33 (84.62%)	53 (81.54%)	$p = 0.43358$
Unstable	6 (23.08%)	6 (15.38%)	12 (18.46%)	
Total	26 (100%)	39 (100%)	65 (100%)	

\*Patients treated with closed reduction and casting (Whitman method);

\*\*patients treated with percutaneous pinning using one cannulated screw

**Table 4.** Southwick angle distinction (before and after treatment) depending on the method of treatment

Treatment method	Average (SD)* distinction	Median*	Range*	Wilcoxon rank-sum test with continuity correction
Group I**	13.08 (7.63)	10	5–30	$W = 629$ $p = 0.09974$
Group II***	11.31 (12.4)	10	5–50	

SD – standard deviation;

\*expressed in angle degrees;

\*\*patients treated with closed reduction and casting (Whitman method);

\*\*\*patients treated with percutaneous pinning using one cannulated screw

Acute and stable slips dominated in both groups of patients, but we found no statistical significance between the observed groups, as it is presented in Tables 2 and 3. Endocrinological disorders in contribution to SCFE presented no statistical significance between the two groups of patients ( $p = 0.3815$ ).

Observing preoperative and postoperative Southwick angle, we found a better improvement in Group II, but we found no statistical significance between the two groups of patients, as Table 4 presents.



**Table 5.** Range of motion analysis before and after treatment of SCFE, depending of the method of treatment

Treatment method	Movement type	Before physiotherapy MV ± SD*	After physiotherapy MV ± SD*	Mann-Whitney U test (p-value)
Group I**	External rotation	38.46 ± 5.62	39.23 ± 4.84	0.696
	Internal rotation	23.46 ± 4.85	32.69 ± 3.8	< 0.001
	Flexion	106.73 ± 11.91	114.23 ± 6.43	0.036
	Abduction	29.81 ± 7	40.77 ± 3.66	< 0.001
Group II***	External rotation	37.69 ± 6.57	41.28 ± 4.25	0.018
	Internal rotation	23.33 ± 3.31	37.56 ± 3.01	< 0.001
	Flexion	107.82 ± 11.91	118.59 ± 2.8	< 0.001
	Abduction	28.72 ± 5.82	42.69 ± 2.53	< 0.001

\*Mean value ± standard deviation (expressed in angle degrees);

\*\*patients treated with closed reduction and casting (Whitman method);

\*\*\*patients treated with percutaneous pinning using one cannulated screw

**Table 6.** Complications ratio depending on the method of treatment

Complications	Group I*	Group II**	Total	Fisher exact test
No complications	22 (84.62%)	38 (97.44%)	60 (92.31%)	p = 0.02208
With complications	4 (15.38%)	1 (2.56%)	5 (7.69%)	
Total	26 (100%)	39 (100%)	65 (100%)	

\*Patients treated with closed reduction and casting (Whitman method)

\*\*patients treated with percutaneous pinning using one cannulated screw

**Table 7.** Complication analysis depending on the method of treatment

Complication type	Group I* (%)	Group II** (%)	Total (%)	Fisher exact test
No complications	22 (84.62%)	38 (97.44%)	60 (92.31%)	p = 0.2208
Acute complications AVN	0 (0%) 4 (15.38%)	1 (2.56%) 0 (0%)	1 (1.54%) 4 (6.15%)	
Total	26 (100%)	39 (100%)	65 (100%)	

AVN – avascular necrosis;

\*patients treated with closed reduction and casting (Whitman method);

\*\*patients treated using percutaneous pinning using one cannulated screw

In statistical analysis of the ROM in affected hips before and after the treatment, we found an improvement in both groups of patients, but no statistical significance was found between the two groups of patients, as it is presented in Table 5.

Observing the complications' occurrence, we found significant differences in complication occurrence and severity between the two groups of patients ( $p = 0.022$ ) (Table 6). In Group I we found AVN of the femoral head and neck in 4/26 patients (15.38%), and in Group II we found no AVN, but we found a re-slip in one patient (2.5%) (Table 7). In our study we found no chondrolysis among complications.

## DISCUSSION

The goal in treating SCFE is early diagnosis and early treatment. We combined preoperative tractions with two methods of treatment: CR and cast immobilization and transcervical fixation using the cannulated screw.

Betz et al. [17] observed the complication occurrence (AVN and chondrolysis) in patients treated with preopera-

tive extension, CR, and cast immobilization. The study included 32 patients (37 SCFE) over a 11-year period. They concluded that 19% of patients had chondrolysis, 3% had re-slipping of the capital femoral epiphysis, and there was no AVN recurrence. Also, Hurley et al. [18] compared re-slipping occurrence between patients treated with CR and cast immobilization and patients treated with femoral osteotomy. They concluded that 7% of patients treated with CR and cast immobilization had re-slipping versus 36% of re-slipping in patients treated with femoral osteotomy. Our study included 26 patients treated with CR and cast immobilization. The complication occurrence in our study was 15.38% (4/26 patients), presented as AVN. All of our patients affected with AVN had an unstable form with slipping of over 30°. According to our observations, we recommend an aggressive approach to unstable and severe forms of SCFE.

One of the largest comparative studies concerning treatment of SCFE was published by Kitano et al. [19]. They observed 222 patients (average age 11.8 years) with the average follow-up of 11.2 years. Preoperative slip value (according to Southwick angle) measured using X-ray films in anteroposterior and "frog like" position was 38.8° on average. They compared the treatment outcome of SCFE between patients treated with CR and cast immobilization (65 patients) and patients treated with percutaneous transcervical fixation using one cannulated screw (157 patients). Both groups of patients were treated preoperatively with percutaneous traction over a period of two weeks. According to Southwick, the most slips (43%) were below 30°, 42% of all slips were 31–60°, and 15% of the slips were over 61°. The treatment results were compared according to the Oxford score, postoperative slips and AVN occurrence. Finally, the study confirmed that unstable and acute forms of SCFE had a high risk for AVN occurrence (unstable forms 30%, acute forms 26%). Patients treated with transcervical fixation using one cannulated screw had AVN occurrence of 6%. Comparing results of this study to the results of our study, our patients had a lower preoperative slip value (23.85° for patients treated with CR and cast immobilization and 23.87° for patients treated with transcervical fixation using one cannulated screw). Also, in our study, occurrence of the mildest forms of SCFE was much higher. We found that 76.92% of the patients had a Southwick angle below 30°, compared to 43% in the study

by Kitano et al. [19]. Weight ability forms of SCFE was similar – it was 81.54% in our study, compared to 84.2% in the study by Kitano et al [19]. AVN occurrence in our study was 15.38% for patients treated with CR and cast immobilization, which is similar to the results found by Kitano et al. [19]. Concerning clinical outcome (expressed in physical findings as the ROM) before and after treatment, we found significant improvement in the ROM in both groups of patients. We prefer preoperative treatment using percutaneous traction as an important factor in clinical outcome. According to our results and the results found by Kitano et al. [19], treatment of SCFE with percutaneous traction, CR, and cast immobilization have unfavorable outcome in slips of over 30° in acute and unstable forms of slipping. Treatment of SCFE using percutaneous transcervical stabilization using one cannulated screw provides a good outcome and stability in slips below 35°. In severe slips, transcervical fixation using cannulated screw isn't

as stable and becomes more vulnerable to complication occurrence.

Prophylactic stabilization of the contralateral hip is still controversial. We use it only to treat SCFE in children younger than 10 years with endocrinological diseases.

## CONCLUSION

According to our study of 65 patients with SCFE, the transcervical fixation using one cannulated screw has multiple advantages in relation to closed reduction and cast immobilization. The major effect of this method of treatment is better clinical and radiological outcome. Also, this method of treatment decreases the complication occurrence.

**Conflict of interest:** None declared.

## REFERENCES

1. Aronsson DD, Loder RT, Breur GJ, Weinstein SL. Slipped capital femoral epiphysis: current concepts. *J Am Acad Orthop Surg.* 2006; 14(2):666–79.
2. Loder RT, Wittenberg B, DeSilva G. Slipped capital femoral epiphysis associated with endocrine disorders. *J Pediatr Orthop* 1996; 15(3):349–56.
3. Paley D. *Growth Plate Considerations.* Berlin: Springer-Verlag; 2002. p. 695–716.
4. Slavkovic N, Vuksinovic Z, Slavkovic S. Factors influencing the development of avascular necrosis in non-operative treatment of the acute slipped capital femoral epiphysis. *Srp Arh Celok Lek.* 2007; 135(1–2):54–60.
5. Cohen MS, Gelberman RH, Griffin PP, Kasser JR, Emans JB, Millis MB. Slipped capital femoral epiphysis: Assessment of epiphyseal displacement and angulation. *J Pediatr Orthop.* 1986; 6(3):259–64.
6. Gelberman RH, Cohen MS, Shaw BA, Kasser JR, Griffin PP, Wilkinson RH. The association of femoral retroversion with slipped capital femoral epiphysis. *J Bone Joint Surg Am.* 1986; 68(7):1000–7.
7. Vukasinovic Z, Slavkovic N, Slavkovic S. Complications of slipped capital femoral epiphysis. *Srp Arh Celok Lek.* 2007; 135(1–2):105–10.
8. Slavkovic N, Vukasinovic Z. Slipped capital femoral epiphysis: a modern treatment protocol. *Srp Arh Celok Lek.* 2009; 137(9–10):562–6.
9. Blethen SL, Rundle AC. Slipped capital femoral epiphysis in children treated with growth hormone. A summary of the National Cooperative Growth Study experience. *Horm Res.* 1996; 46(3):113–6.
10. Allen CP, Calvert PT. Simultaneous slipped upper femoral epiphysis in identical twins. *J Bone Joint Surg Br.* 1990; 72(5):928–9.
11. Peck D. Slipped capital femoral epiphysis: diagnosis and management. *Am Fam Physician.* 2010; 82(3):258–62.
12. Häggglund G, Hansson LI, Ordeberg G. Epidemiology of slipped capital femoral epiphysis in southern Sweden. *Clin Orthop Relat Res.* 1984; 191:82–94.
13. Hansson G, Jerre R, Sanders SM, Wallin J. Radiographic assessment of coxarthrosis following slipped capital femoral epiphysis: A 32-year follow-up study of 151 hips. *Acta Radiol.* 1993; 34(2):117–23.
14. Seller K, Raab P, Wild A, Krauspe R. Risk-benefit analysis of prophylactic pinning in slipped capital femoral epiphysis. *J Pediatr Orthop B.* 2001; 10(3):192–6.
15. Jerre R, Billing L, Hansson G, Karlsson J, Wallin J. Bilaterality in slipped capital femoral epiphysis: Importance of a reliable radiographic method. *J Pediatr Orthop B.* 1996; 5(2):80–4.
16. Seller K, Wild A, Westhoff B, Raab P, Krauspe R. Radiological evaluation of unstable (acute) slipped capital femoral epiphysis treated by pinning with Kirschner wires. *J Pediatr Orthop B.* 2006; 15(5):328–34.
17. Betz RR, Steel HH, Emper WD, Huss GK, Clancy M. Treatment of slipped capital femoral epiphysis. Spica-cast immobilization. *J Bone Joint Surg Am.* 1990; 72(4):587–600.
18. Hurley JM, Betz RR, Loder RT, Davidson RS, Alburger PD, Steel HH. Slipped capital femoral epiphysis. The prevalence of late contralateral slip. *J Bone Joint Surg Am.* 1996; 78(2):226–30.
19. Kitano T, Nakagawa K, Wada M, Moriyama M. Closed reduction of slipped capital femoral epiphysis: high-risk factor for avascular necrosis. *J Pediatr Orthop B.* 2015; 24(4):281–5.

## Лечење склизнућа главице бутне кости – упоредна студија у периоду од дванаест година

Бојан Буква<sup>1</sup>, Синиша Дучић<sup>1</sup>, Владимир Радловић<sup>1</sup>, Горан Вргоч<sup>2</sup>, Бранислав Кривокапић<sup>3</sup>, Игор Јеласка<sup>4</sup>, Петра Мандић-Јеласка<sup>4</sup>

<sup>1</sup>Универзитетска дечја клиника, Одељење дечје ортопедије и трауматологије, Београд, Србија;

<sup>2</sup>Универзитетска болница „Свети дух“, Одељење ортопедске хирургије, Загреб, Хрватска;

<sup>3</sup>Институт за ортопедско-хируршке болести „Бањица“, Београд, Србија;

<sup>4</sup>Универзитет у Сплиту, Кинезиолошки факултет, Сплит, Хрватска

### САЖЕТАК

**Увод/Циљ** Циљ ове студије је поређење две методе лечења и процена предности резултата лечења трансцервикалном фиксацијом главе бутне кости употребом једног канулираног завртња у лечењу склизнућа главе бутне кости.

**Методе** У студију је укључено 65 педијатријских болесника (35 дечака и 30 девојчица), узраста од 6 до 16 година (просечна вредност 11,86), током 12-годишњег периода (од 2000. до 2012. године). Упоредили смо степен склизнућа пре и после спроведеног лечења (Саутвиков угао), обим покрета пре и после спроведеног лечења и учесталост компликација између две групе болесника. Прва група (26 болесника) лечена је затвореном репозицијом и имобилизацијом гипсаном завојем (I група), а друга група (39 болесника) била је лечена перкутаном фиксацијом једним канулираним завртњем (II група).

**Резултати** На основу поређења преоперативних и постоперативних вредности Саутвиковог угла, болесници друге групе

су имали бољи радиографски резултат у односу на болеснике из прве групе, али без статистички значајне разлике ( $p = 0,09$ ). Посматрајући обим покрета кукова пре и после интервенције, забележено је значајно побољшање у обе групе болесника, посебно код болесника лечених трансцервикалном фиксацијом једним канулираним завртњем (група II). Посматрајући учесталост компликација, болесници друге групе су имали мањи број компликација ( $p = 0,02$ ) у односу на болеснике прве групе.

**Закључак** Метода трансцервикалне фиксације главе бутне кости је дала бољи клинички резултат и мањи број компликација у односу на методу ортопедске репозиције и имобилизације гипсаном завојем у лечењу болесника са склизнућом главе бутне кости.

**Кључне речи:** трансцервикална фиксација; канулирани завртањ; затворена репозиција