

## CASE REPORT / ПРИКАЗ БОЛЕСНИКА

# Calcification of a cervical intervertebral disc in a child – a case report and review of literature

Dušan Marić<sup>1,2</sup>, Vukadin Milankov<sup>1,2</sup>, Ivica Lalić<sup>2,3</sup>, Marko Bumbaširević<sup>4,5</sup>, Džihan Abazović<sup>6</sup><sup>1</sup>Institute for Children's and Youth Health Care of Vojvodina, Novi Sad, Serbia;<sup>2</sup>University of Novi Sad, Faculty of Medicine, Novi Sad, Serbia;<sup>3</sup>Clinic for Orthopaedic Surgery and Traumatology, Clinical Centre of Vojvodina, Novi Sad, Serbia;<sup>4</sup>University of Belgrade, Faculty of Medicine, Belgrade, Serbia;<sup>5</sup>Clinic for Orthopaedic Surgery and Traumatology, Clinical Centre of Serbia, Belgrade, Serbia;<sup>6</sup>Emergency Medicine Centre of Montenegro, Podgorica, Montenegro**SUMMARY**

**Introduction** We report a case of calcification of a cervical intervertebral disk in a child. This is a rare condition, and has been described in about 400 cases worldwide. Children affected by it present with the onset of pain, muscle spasm, and the presence of calcification of a intervertebral disk on radiography. Our objective was to present a case of sudden onset of pain in the neck and torticollis.

**Case outline** In our case, the condition was diagnosed after trauma, presented with neck pain and spasm of the right sternocleidomastoid. Initial neck radiography was done, and after identifying the calcification in front of C4 and C5 vertebral bodies, CT analysis was conducted. When it was concluded that there is no compression on spine nerve roots, conservative course of treatment was followed. The child had full regression of symptoms after two weeks.

**Conclusion** Emergency personnel should bear in mind that, even though radiographical finding of a calcification shadow in front of the spine may raise concern, the nature of this disorder is benign in most cases, and responds very well to conservative treatment.

**Keywords:** calcification; intervertebral disk; neck pain; torticollis

**INTRODUCTION**

Juvenile calcification of an intervertebral disc is an infrequent condition, benign and self-limiting in character, primarily affecting *nucleus pulposus*. Luschka described the first case of intervertebral disc calcification on anatomic dissection in 1858, and Beneke first demonstrated this condition radiographically in 1897 [1, 2, 3]. This disorder in children was first discovered by Baron [4] in 1924, and others found it in more than 400 cases to date.

Our objective was to present a case of a sudden onset of pain in the neck and torticollis.

**CASE REPORT**

The patient, a six-year-old girl, was brought to the clinic because of a sudden onset of pain in the neck and torticollis. After examining the patient history, we found that she fell from her bicycle two days earlier and was treated for sub-acute rhinitis for the previous two weeks.

Clinical examination revealed tilting of the head to the right side and upwards, consistent with a muscle spasm of the sternocleidomastoid muscles. There was also asymmetry of the shoulders and elevated tonus of the posterior neck and shoulder muscles. Active range of

motion for the cervical part of the spine was significantly decreased: flexion 25°, extension 0°, right and left lateral flexion 10°, 60° right rotation, 40° left rotation. Postural dysfunction and thoracolumbar scoliosis was also noted. Pain was provoked by terminal movement and palpation of the posterior side of the neck bilaterally. No motor neurological deficits were present and no sensorimotor neurological deficits were noted (tests for gross motor strength, gross motor functions, fine motor functions, and simple sensory skill were performed).

Because of positive trauma heteroanamnesis, plain radiography of the cervical spine was taken. We discovered a calcified lesion between C4 and C5 vertebrae, which we first attributed to trauma (Figure 1). On the following day, computerized tomography (CT) scan was done without the contrast (Figure 2). The results of the analysis were as follows: oval hyper dense lesion (density of calcium) in the intervertebral space at the level of C4/C5 vertebrae, centrally positioned, approximately 5.5 × 5.5 mm, with nearby punctiform calcifications. An oval lesion was situated in the intervertebral disc, its anterior aspect and punctiform calcification were in the lateral aspect of the disc. There was no penetration in the spinal canal and no signs of compression on spinal nerves were present. The cervical part of the spinal canal was con-

**Received • Примљено:**

March 23, 2018

**Revised • Ревизија:**

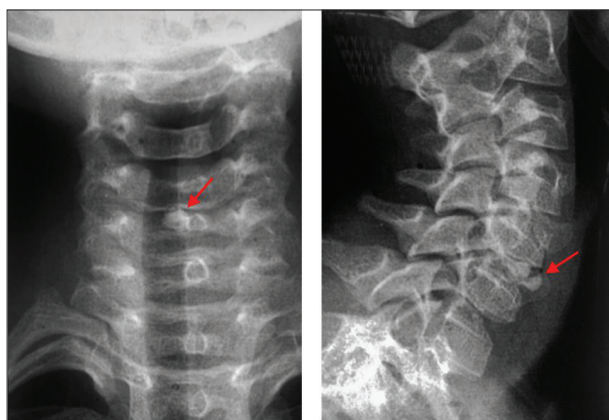
November 6, 2018

**Accepted • Прихваћено:**

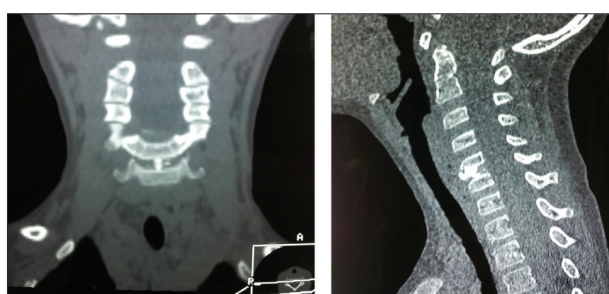January 5, 2019

**Online first:** March 14, 2019**Correspondence to:**

Dušan MARIĆ  
Institute for Children's and Youth  
Health Centre of Vojvodina  
Hajduk Veljkova 10  
21000 Novi Sad, Serbia  
[dusan.maric@mf.uns.ac.rs](mailto:dusan.maric@mf.uns.ac.rs)



**Figure 1.** Radiography of the cervical spine; calcified lesion between C4 and C5 vertebrae



**Figure 2.** Computerized tomography scan of cervical spine without contrast; calcified lesion between C4 and C5 vertebrae

sistent and with no pathological changes. There were signs of sclerosation of the inferior plateau of the C4 vertebral body and on the superior plateau of the C5 vertebral body.

Since there were no neurological symptoms and CT did not show any pathological changes related to the spinal canal, magnetic resonance imaging (MRI) was not indicated.

The patient was treated conservatively, analgesics were prescribed, soft cervical collar (Schantz) was placed for seven days, and after the initial management the patient was referred to a physiotherapist for further treatment. All symptoms were gone after two weeks.

## DISCUSSION

Juvenile calcification of an intervertebral disc is an uncommon childhood condition characterized by neck pain, torticollis, and calcification of the intervertebral disk. Most of the patients were aged between five and 12 years, predominantly male (male:female = 8:5), though some studies suggest a different ratio of male to female (1:1) [5, 6]. These results should be taken carefully, as studies were done on small series of patients [7].

Calcification could be found on any level of the spine and there may be multiple level involvements in 30–40% of cases [5, 6, 8, 9, 10]. The most affected part of the spine is the cervical one. The *nucleus pulposus* and *annulus fibrosus* can be calcified, but in the majority of the cases it is the *nucleus pulposus*. When calcifications are found in the cervical spine, its lower part is more frequently involved and

almost all patients are symptomatic [7, 11]. The onset is usually acute, and patients are often referred to emergency room for evaluation of a possibly more serious condition.

Muscle pain was the major symptom of the condition, and it is found in about 70% of patients, followed by sensorimotor disturbance (focal weakness, sensory loss, compressive myelopathy) and fever [7]. Dysphagia has been reported in a patient with an anterior disk protrusion and is attributed to the formation of a retropharyngeal edema due to tissue irritation by herniated calcium salts and macrophage-mediated inflammatory reaction, similar to calcific tendinitis [12–15]. Our patient exhibited muscle pain, right torticollis, and reactive thoracolumbar scoliosis. Fever in our patient was not detected, nor were sensorimotor disturbances.

Sonnabend et al. [13] demonstrated that disc herniation alone cannot explain the pain [16]. Some authors suggest that the clinical symptoms are related to the inflammation process within the disc [17, 18]. Muscle spasm could also be partly responsible for the pain. Immobilization using head halter traction or cervical collar probably limits the loading of the inflamed disc during the phase of acute inflammation and relieves the pain resulting from muscle spasm. The pain could be associated with a rise of intradiscal pressure, which partly explains the enlarged intervertebral space and adjacent decrease in vertebral body height, even though this was not the case with our patient [13, 16].

Half of the patients who underwent blood examination exhibited abnormal levels of inflammatory indicators. Erythrocyte sedimentation rate was the most sensitive indicator, elevated in more than 90% of patients. In contrast, white blood cell count and C-reactive protein showed positive reactions in only about one third of patients. We found only one study in which thyroid function tests, parathyroid hormone level assay, serum calcium, serum phosphate, serum alkaline phosphatase, peripheral blood film, and urine complete examination were done, and all the results were within normal limits [5].

For determining the presence of the condition and evaluating its progress, frontal and lateral radiographs are sufficient. CT can confirm dense calcification, show edema, and reveal an eventual herniation of *nucleus pulposus*, which can be found in up to 38% of patients, its migration into neural foramen, and consequences on the spinal cord [13, 19]. However, Ginalski et al. [20] considered in 1992 that CT is unnecessary irradiation and should only be indicated when disk calcifications are associated with neurological symptoms. MRI should be done to exclude root, spinal cord, or vertebral artery compression [16]. Symptoms such as a headache, syncope, vertigo, tinnitus, ataxia, dysarthria, visual disturbance, Horner's syndrome, vomiting, or dysphagia should alert the physician to the possibility of vertebral artery insufficiency, possibly due to herniation of disk through foramen transversarium – some authors recommend doing magnetic resonance angiography (MRA) [16]. Additional investigations (CT, MRI, and MRA) should be recommended only for patients with sensorimotor disturbances [8, 21].

When calcification is clearly visible on plain films, in the form of an oval, round shape that could be fragmented,

the diagnosis is straightforward. However, if calcification of the disc has not yet developed, the findings are more subtle, consisting primarily of bulging of the involved intervertebral disc into the adjacent vertebral bodies [11]. On MRI examinations in patients with disc calcification, there is a loss of signal on T1- and T2-weighted images. In some patients, the loss of signal in an adjacent vertebral body without the loss of vertebral height has been found [22, 23]. These changes could be the evidence that supports the concept of the vertebral body sustaining the initial insult and that disc involvement may be secondary [22]. In our study, CT scan showed sclerosis of adjacent vertebral bodies without the loss of height. This could be an indicator of the later stage of the mentioned process.

There are several hypotheses, some of which focus on the changes in the disc as the primary part of process, while others place focus on the vertebral body.

Signs of low-grade fever, leukocytosis, elevated erythrocyte sedimentation, mild pleocytosis and elevated protein in the cerebrospinal fluid support the theory of an inflammatory process during disc development or during the symptomatic interval of the disease [24]. Smith et al. [6], who performed anterior discectomy in a 12-year-old boy at the C4/C5 level, demonstrated an inflammatory response of severe reactive fibroblastic proliferation associated with multinucleated foreign body type giant cells and pleomorphic histiocytes in the disc material, while the herniated fragment of the nucleus pulposus appeared to be relatively normal. Contrary to these reports, Gerlach et al. [24] found neither evidence of inflammatory or reactive changes, nor neovascularization.

Swischuk et al. [11] focus on the disruption of blood supply to the intervertebral disk with resulting disk swelling and necrosis. In children, the discs are supplied by small blood vessels through the cartilaginous vertebral end plates. However, approximately at the age of eight, the vessels begin to obliterate. By 20 to 30 years of age, the blood vessels for the most part disappear. After this sequence of events, disc nutrition becomes nonvascular and *nucleus pulposus* starts getting nutrients by osmotic passage from the vertebral end plate. This way of transition occurs effortlessly and it appears that the process is relatively smooth. It's noted that during this transition, there is a tenuous vascular connection between the cartilaginous end plate of the vertebral body and the juxtaposed layer of the intervertebral disc. It is possible that in some patients during the critical period of nutrition transfer, some external factor could result in a premature interruption of blood/nutrition to the disc/vertebral body complex. It may be that the vertebral body becomes involved first, but in

most cases escapes unharmed. It could also be that vertebral body involvement could lead to the interruption of the tenuous blood/nutrition supply from the vertebral body to the disc so the disc would become relatively ischemic, swollen, and even necrotic. Later, it would calcify. Because of swelling, the disc would bulge peripherally or into the vertebral body as a Schmorl's node. If the vertebral body is "softened" because of inflammation and vasculitis, the disc could bulge in the convex direction into the vertebral body [11].

Aforementioned mechanisms could be triggered by trauma, infection, inflammation, or vasculitis. Trauma is found in 7–30% of the cases, while respiratory infection is found in 15% of patients' histories [13]. In our case, both factors were present.

Juvenile calcification of intervertebral discs is benign and self-limiting. In most cases, conservative treatment is required. It should consist of analgesics, non-steroid anti-inflammatory drugs, muscle relaxants, cervical collar, and limitation of physical activity. Patient symptoms are relieved between five days and three weeks in two thirds of patients and in six months in 95% of patients [13, 15]. Rapid improvement in symptoms is most probably related to the natural pathophysiology of juvenile intervertebral disc calcification [16]. On radiographs, the calcification disappears within a few months, although there were cases where it persists longer [24].

Surgical treatment is rarely required. There are no guidelines for it. Nerve root or spinal cord compression by the calcified disc are not considered to be absolute indications for surgical intervention [7]. Surgical decompression should be reserved only for cases with persistent neurological deficits or progressive neurological deterioration following an inadequate course of conservative treatment [16, 24]. Anterior cervical discectomy with decompression of the spinal cord is a safe procedure with good clinical results [24].

Juvenile intervertebral disk calcification is a rare disease. For emergency medicine practitioners it's important to have this disease in mind. When found, it should be regarded as benign condition with excellent outcome by means of conservative treatment. However, the patient should be checked more frequently for the progression of calcification and neurological symptoms. If there are signs of nerve root and spinal cord compression by the calcified disc, CT scan and MRI should be performed. If neurological status deteriorates further after attempted conservative treatment, surgery should be considered.

**Conflict of interest:** None declared.

## REFERENCES

1. Sandstrom C. Calcifications of the intervertebral discs and the relationship between various types of calcifications in the soft tissues of the body. *Acta Radiol.* 1951; 36(3):217–33.
2. Spapens N, Wouters C, Moens P. Thoracolumbar intervertebral disc calcifications in an 8-year-old boy: case report and review of the literature. *Eur J Pediatr.* 2010; 169:577–80.
3. Melnick J, Silverman F. Intervertebral disk calcification in childhood. *Radiology.* 1963; 80:399–408.
4. Baron A. Uber eine neue Erkrankung der Wirbelsaule. *Jahrb Kinderheilkd.* 1924; 104:357–60.
5. Dhammi IK, Arora A, Monga J. Calcified thoracic intervertebral disc at two levels as a cause of mid-back pain in a child: a case report. *J Orthop Sci.* 2002; 7(5):587–89.

6. Smith R, Vohman M, Dimon JH, Averett JE, Milsap JH. Calcified cervical intervertebral discs in children. Report of three cases. *J Neurosurg.* 1977; 46(2):233–8.
7. Tsutsumi S, Yasumoto Y, Ito M. Idiopathic intervertebral disk calcification in childhood: a case report and review of literature. *Childs Nerv Syst.* 2011; 27:1045–51.
8. Dai LY, Ye H, Qian QR. The natural history of cervical disc calcification in children. *J Bone Joint Surg.* 2004; 86(7):1467–72.
9. Girodias J, Azouz E, Marton D. Intervertebral disk space calcification: a report of 51 children with a review of the literature. *Pediatr Radiol.* 1991; 21(8):541–6.
10. Barrett M, Anderson J, Rao B, Vaslow D, Hoernschemeyer D. Multilevel pediatric cervicothoracic intervertebral disc calcifications. *Am J Orthop (Belle Mead NJ).* 2008; 37(7):E126–8.
11. Swischuk LE, Jubang M, Jadhav SP. Calcific discitis in children: vertebral body involvement (possible insight into etiology). *Emerg Radiol.* 2008; 15(6):427–30.
12. Coventry MB. Calcification in a cervical disc with anterior protrusion and dysphagia. *J Bone Joint Surg Am.* 1970; 52(7):1463–6.
13. Sonnabend DH, Taylor TK, Chapman GK. Intervertebral disc calcification syndromes in children. *J Bone Joint Surg Br.* 1982; 64(1):25–31.
14. Jawish R, Ponet M. Dysphagia disclosing a cervical disc calcification in a child: apropos of a case and review of the literature. *Chir Pediatr.* 1990; 31(2):127–30.
15. Kim H, Ha D, Lee S, Kim S, Wenokor C. Acute Symptomatic Intervertebral Disk Calcification in a Child With Retropharyngeal Edema. *J Clin Rheumatol.* 2011; 17(7):365–7.
16. Mac-Thiong JM, Leduc S, Marton D, Duhaime M, Morin B. Herniation of a Calcified Cervical Disc into the Foramen Transversarium in an 8-Year-Old Child. *Spine.* 2004; 29(16):349–52.
17. Pattekar MA, Krishnan A, Kazmierczak C. Juvenile intervertebral disk calcification: a cause of painful torticollis. *Emerg Radiol.* 2001; 8(6):338–40.
18. Bagatur AE, Zorer G, Centel T. Natural history of paediatric intervertebral disc calcification. *Arch Orthop Trauma Surg.* 2001; 121(10):601–3.
19. Lernout C, Haas H, Rubio A, Griffet J. Pediatric intervertebral disk calcification in childhood: three case reports and review of literature. *Childs Nerv Syst.* 2009; 25(8):1019–23.
20. Ginalski JM, Landry M, Gudinchet F, Schnyder P. Is tomography of intervertebral disc calcification useful in children? *Pediatr Radiol.* 1992; 22:9–61.
21. Bajard X, Renault F, Benharrats T, Mary P, Madi F, Vialle R. Intervertebral disc calcification with neurological symptoms in children: report of conservative treatment in two cases. *Childs Nerv Syst.* 2010; 26(7):973–8.
22. Swischuk L, Stansberry S. Calcific discitis: MRI changes in disks without visible calcification. *Pediatr Radiol.* 1991; 21:365–6.
23. Herring JA, Hensinger RN. Instructional case cervical disc calcification. *J Pediatr Orthop.* 1988; 8:613–6.
24. Gerlach R, Zimmermann M, Kellermann S, Lietz R, Raabe A, Seifert V. Intervertebral disc calcification in childhood—a case report and review of the literature. *Acta Neurochir Wien.* 2001; 143(1):89–93.

## Калцификација међупршљеног диска вратне кичме код детета – приказ случаја и преглед литературе

Душан Марић<sup>1,2</sup>, Вукадин Миланков<sup>1,2</sup>, Ивица Лалић<sup>2,3</sup>, Марко Бумбаширевић<sup>4,5</sup>, Џихан Абазовић<sup>6</sup>

<sup>1</sup>Институт за заштиту деце и омладине Војводине, Нови Сад, Србија;

<sup>2</sup>Универзитет у Новом Саду, Медицински факултет, Нови Сад, Србија;

<sup>3</sup>Клинички центар Војводине, Клиника за ортопедску хирургију и трауматологију, Нови Сад, Србија;

<sup>4</sup>Универзитет у Београду, Медицински факултет, Београд, Србија;

<sup>5</sup>Клинички центар Србије, Клиника за ортопедску хирургију и трауматологију, Београд, Србија;

<sup>6</sup>Завод за хитну медицинску помоћ Црне Горе, Подгорица, Црна Гора

### САЖЕТАК

**Увод** Представљамо случај калцификације интервертебралног диска вратне кичме код детета. Ово ретко обољење је описано у око 400 случајева широм света. Оболела деца долазе код лекара са тегобама у виду болова у врату, мишићним спазмом и рендгенским снимком калцификације интервертебралног диска. Наш циљ био је да прикажемо случај изненадне појаве бола у врату и тортиколиса.

**Приказ болесника** Болесница се јавила после трауме, са боловима у врату и спазмом десног стерноклеидомастоидног мишића. Иницијално је направљен рендгенски снимак,

када је откривена калцификација испред *C4* и *C5* вратног кичменог пршљена, а затим је начињен *СТ* снимак вратне кичме. Када је искључено постојање компресије коренова спиналних живаца, укључен је конзервативни третман. После две недеље дете је било без тегоба.

**Закључак** Иако постојање сенке са предње стране кичменог стуба изазива забринутост, доктори ургентне медицине треба да имају у виду да је ово обољење у већини случајева бенигне природе, те одлично реагује на конзервативно лечење.

**Кључне речи:** калцификација; интервертебрални диск; вратни бол; тортиколис