



CASE REPORT / ПРИКАЗ БОЛЕСНИКА

Successful postoperative pancreatic fistula treatment with the use of somatostatin infusion after duodenal gastrointestinal stromal tumor resection

Mariusz Chabowski^{1,2}, Wiktor Pawlowski^{1,2}, Michał Lesniak^{1,2}, Agnieszka Ziomek^{1,2}, Maciej Malinowski^{1,2}, Tadeusz Dorobisz^{2,3}, Dariusz Janczak^{1,2}

¹Wrocław Medical University, Faculty of Health Sciences, Division of Surgical Procedures, Wrocław, Poland;

²Fourth Military Teaching Hospital, Department of Surgery, Wrocław, Poland;

³Wrocław Medical University, Faculty of Vascular, General and Transplantation Surgery, Department of Postgraduate Medical Training, Wrocław, Poland

SUMMARY

Introduction According to the International Study Group on Pancreatic Fistula, a postoperative pancreatic fistula is defined as every case of fluid leak on the third (or later) postoperative day, in which the level of amylase in the collected fluid is at least three times higher than the serum amylase level. Depending on the stage and the designated management, pancreatic fistulas are divided into the following three categories: A (mild), B, and C (severe). Regardless of favorable conditions, exocrine pancreatic secretion is the key factor in fistula formation. The decrease in pancreatic secretion caused by somatostatin and its analogues combined with parenteral nutrition is a well-established treatment method in pancreatic fistula management.

Case outline The case of a 69-year-old patient who had undergone a resection of a duodenal gastrointestinal stromal tumor located directly above the major duodenal papilla is presented. Excessive drainage of amylase-rich fluid was observed in the postoperative period. Treatment comprised continuous infusion of somatostatin and parenteral nutrition. Fistula closure was accomplished on postoperative day 14, confirmed by a radical decrease in the volume of drainage and low amylase levels in the collected fluid. The patient remained in a good clinical state and was discharged from hospital on postoperative day 20.

Conclusion This is an example of the early diagnosis of a postoperative pancreatic fistula, treated conservatively with the use of somatostatin. Post-surgery clinical awareness of the importance of direct contact between the stromal tumor and pancreatic tissues, in connection with routine amylase level assessment, led to a quick diagnosis of pancreatic fistula and the therapy led to an uneventful outcome.

Keywords: pancreatic fistula; somatostatin; GIST; postoperative course

INTRODUCTION

A postoperative pancreatic fistula (POPF) is defined according to International Study Group on Pancreatic Fistula Definition as any case of fluid leak on the third (or later) postoperative day, where the level of amylase in the collected fluid is at least three times higher than the serum amylase level. Depending on the stage and therefore the designated management, pancreatic fistulas are divided into the following three categories: A (mild symptoms), B, and C (severe symptoms). Regardless of favorable conditions, the effective exocrine pancreatic secretion is the key factor in the fistula formation. A decrease in pancreatic secretion caused by somatostatin and its analogues combined with parenteral nutrition is a well-established treatment method in pancreatic fistula management, and is suitable in most cases.

POPF can either be the direct result of pancreatic surgery and its surroundings (as in our case) or of a trauma of the pancreas. POPF after a pancreatoduodenectomy remains the leading cause of morbidity and mortality after surgery. The true occurrence of POPF is difficult

to assess; depending on the literature, it ranges 6.2–75.6%. The lack of a uniform definition of a pancreatic fistula – or the exact moment of pancreatic fistula diagnosis – results in such an extreme discrepancy [1].

CASE REPORT

A 69-year-old man, without a previous history of illness, was admitted to the catheterization laboratory due to the fact that he had an inferior wall myocardial infarction with ST segment elevation. Percutaneous coronary intervention was performed with the insertion of a drug-eluting stent. Three days after the procedure, melaena with corresponding anemia was observed in laboratory tests. Upper gastrointestinal endoscopy revealed a firm ulcerative duodenal inflammatory tumor located at the Vater's papilla, narrowing the lumen of the duodenum (Figure 1).

Subsequent abdominal computed tomography scans showed a 42 × 28 × 30 mm tumor with uneven margins and possible pancreas infiltration (Figure 2).

Received • Примљено:

April 13, 2018

Revised • Ревизија:

March 20, 2019

Accepted • Прихваћено:

May 17, 2019

Online first: May 24, 2019

Correspondence to:

Mariusz CHABOWSKI
Department of Surgery
Fourth Military Teaching Hospital
5 Weigla Street
50-981 Wrocław, Poland
mariusz.chabowski@gmail.com

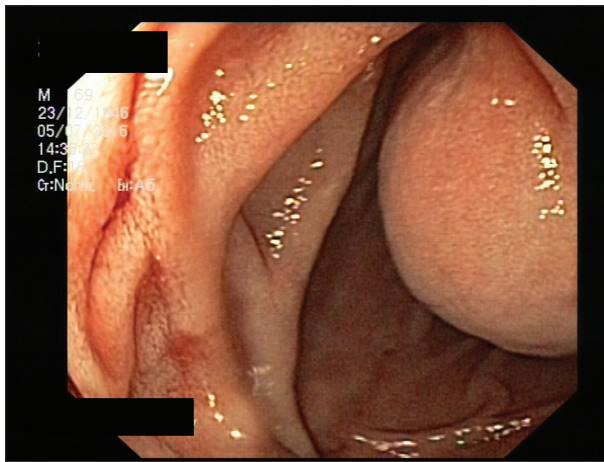


Figure 1. Upper gastrointestinal endoscopy shows the firm duodenal gastrointestinal stromal tumor-like tissue at the Vater's papilla

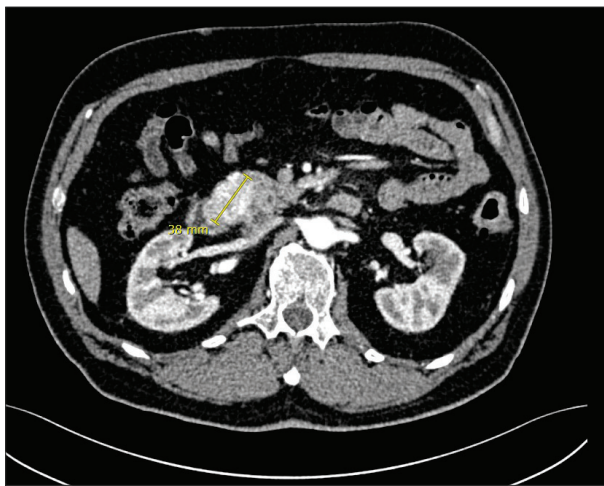

Figure 2. Abdominal computed tomography scan shows the tumor measuring 38 mm with uneven margins and possible infiltration of the pancreas

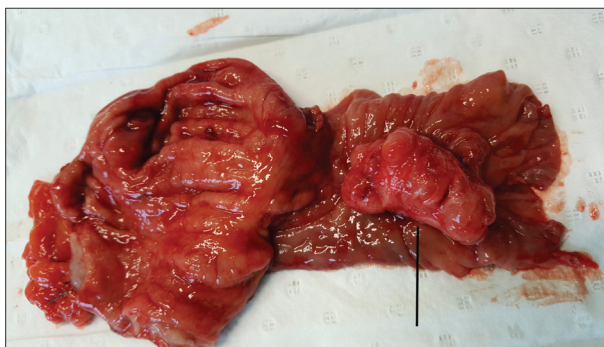

Figure 3. Postoperative view; the arrow shows the excised specimen with gastrointestinal stromal tumor

Biopsies taken during endoscopy of the tumor revealed that it was an undifferentiated inflammatory tumor. Due to the recent severe myocardial infarction, the placement of a drug-eluting stent in the coronary arteries and the necessity for anticoagulation therapy, the patient was offered the option of delaying the operation.

The patient was admitted to the surgical clinic three months later. One day before the operation, endoscopic

retrograde cholangiopancreatography was performed and a 10 French stent was inserted in the common bile duct as a precaution against preoperative bile duct injuries as a landmark. During the elective laparotomy, a firm duodenal tumor with an ulceration on top was observed above the Vater's papilla. The tumor tissues were oriented towards the head of the pancreas. The tumor was carefully dissected from the pancreas, although some preparation and resection of the pancreatic tissues was unavoidable in this case. Subsequently, the proximal part of the duodenum with the tumor (just above the Vater's papilla) and the distal third of the stomach was excised. The gastrointestinal tract was then restored with a side-to-side jejunogastric antecolic anastomosis, aided with Braun's anastomosis below. Anastomoses were performed with the use of absorbable mono-filament sutures in single or double layers. The postoperative histopathology revealed a 25 × 25 mm gastrointestinal stromal tumor of the duodenum, with clean surgical margins (Figure 3).

A few hours after surgery and on the first postoperative day, serum amylase levels were 344 U/L and 248 U/L, respectively. Drainage fluid amylase levels collected on the first, third, and later postoperative days were within the range of 1,100–3,000 U/L. Due to the findings acquired by the laboratory tests, the visual assessment of the drained abdominal fluid and intraoperative preparation of the pancreatic tissue, a pancreatic fistula was diagnosed. The conservative treatment comprised total and subsequently partial parenteral nutrition (10 days in total) together with a continuous somatostatin infusion of 6 mg / 24 hours. Laboratory indicators of fistula closure were successfully obtained on the 14th day after surgery. The somatostatin dosage was then reduced to 3 mg / 24 hours for the next 48 hours and subsequently discontinued. The patient remained in a good clinical state without any elevation of inflammatory indicators during the fistula treatment period. The man was discharged from hospital 20 days after surgery. The abdominal drains were removed four days prior to discharge.

A surprisingly high amylase level from the abdominal fluid collection was observed on the seventh day of fistula treatment (9,400 U/L). The laboratory findings were contradictory to the good overall condition of the patient. Therefore, we presumed that the drainage blockage and fluid concentration caused such laboratory test results.

DISCUSSION

In the past, the available studies defined pancreatic fistula individually, which made the comparison of treatment results difficult. In 2005, Bassi et al. [2] – International Study Group of Pancreatic Fistula (ISGPF) – developed a widely-accepted definition of a POPF. According to ISGPF, the POPF is a drain output of any measurable volume of fluid on or after postoperative day 3 with an amylase content three times higher than the serum amylase activity [3].

Successful treatment of POPF depends on early diagnosis. Regardless of the ISGPF definition, additional useful

predictors of fistula formation include: 1) serum amylase levels above 130 U/L four hours after surgery or on postoperative day 1; 2) amylase level in the drained abdominal fluid over 5,000 U/L on postoperative day 1 [4, 5].

Effective exocrine pancreatic secretion is the key factor in pancreatic fistula formation. The limitation of pancreatic secretion creates the desired conditions for fistula treatment and therefore is the key to pancreatic fistula therapy. Oral nutrition is restricted, followed by parenteral nutrition, aided with drugs like somatostatin and its analogues, reducing the exocrine secretion of the organ. The first successful use of somatostatin in the prevention of pancreatic fistulas dates back to the year 1979 [1, 6, 7].

Somatostatin is secreted in the central nervous system and the gastrointestinal tract (70%). This hormone inhibits the secretion of gastrin, secretin, vasoactive intestinal peptide and pancreatic enzymes, and reduces both peristaltic intestine activity and gastric emptying. All of the abovementioned results of somatostatin activity create a favourable environment for pancreatic fistula closure. Thanks to the inhibition of pepsin and hydrochloric acid production, somatostatin also plays a well-established role in the prevention and directed treatment of upper gastrointestinal bleeding caused by esophageal varices, gastric and duodenal ulcers. However, the most valuable effect of somatostatin infusion in these cases is the instant (a few minutes after administration) reduction of portal vein pressure and mesenteric circulation [8, 9, 10]. The recommended pancreatic fistula therapy includes a continuous intravenous somatostatin infusion of 6 mg / 24 hours until

complete fistula closure, followed by a 50% reduction in the infusion to 3 mg / 24 hours for the next 48 hours in order to avoid a rebound effect. The only proper way to administer somatostatin is continuous infusion, because of its short, three-minute half-life. Patients with advanced kidney failure require lower doses, whereas liver failure does not affect somatostatin dosage.

The latest research on somatostatin therapy confirms its positive impact on pancreatic fistula treatment and prevention after pancreatic surgery. At the same time, a similar effect with the analogue of somatostatin – octreotide – is being questioned in terms of successful fistula treatment [1]. Parenteral nutrition is also an essential part of proper initial pancreatic fistula therapy, although more detailed information on the subject is beyond the scope of this article.

The case report presented is a good example of POPF treatment with the use of somatostatin. Clinical awareness of the importance of direct contact between the stromal tumor and pancreatic tissues, in connection with routine amylase level assessment, led to a quick diagnosis of the pancreatic fistula and the therapy led to uneventful outcome.

This case report was approved by the local ethics committee, and written consent was obtained from the patient for the publication of this case report and any accompanying images. Written informed consent in Polish was obtained from the patient for the publication of this case report and any accompanying images.

Conflict of interest: None declared.

REFERENCES

1. Anderson R, Dunki-Jacobs E, Burnett N, Scoggins C, McMasters K, Martin RC. A cost analysis of somatostatin use in the prevention of pancreatic fistula after pancreatectomy. *World J Surg.* 2014; 38(8):2138–44.
2. Bassi C, Dervenis C, Butturini G, Fingerhut A, Yeo C, Izbicki J, et al. Postoperative pancreatic fistula: An international study group (ISGPF) definition. *Surgery.* 2005; 138(1):8–13.
3. Matrella E, Valatas V, Notas G, Roumpaki H, Xidakis C, Hadzidakis A, et al. Bolus somatostatin but not octreotide reduces hepatic sinusoidal pressure by a NO-independent mechanism in chronic liver disease. *Aliment Pharmacol Ther.* 2001; 15(6):857–64.
4. de Franchis R, Baveno VI Faculty. Expanding consensus in portal hypertension. Report of the Baveno VI Consensus Workshop: Stratifying risk and individualizing care for portal hypertension. *J Hepatol.* 2015; 63(3):743–52.
5. Gurusamy KS, Koti R, Fusai G, Davidson BR. Somatostatin analogues for pancreatic surgery. *Cochrane Database Syst Rev.* 2013; (4):CD008370.
6. Jin K, Zhou H, Zhang J, Wang W, Sun Y, Ruan C, et al. Systematic review and meta-analysis of somatostatin analogues in the prevention of postoperative complication after pancreaticoduodenectomy. *Dig Surg.* 2015; 32(3):196–207.
7. Palani Velu LK, Chandrabalan VV, Jabbar S, McMillan DC, McKay CJ, Carter CR, et al. Serum amylase on the night of surgery predicts clinically significant pancreatic fistula after pancreaticoduodenectomy. *HPB (Oxford).* 2014; 16(7):610–9.
8. Molinari E, Bassi C, Salvia R, Butturini G, Crippa S, Talamini G, et al. Amylase value in drains after pancreatic resection as predictive factor of postoperative pancreatic fistula. *Ann Surg.* 2007; 246(2):281–7.
9. Katsourakis A, Oikonomou L, Chatzitheoklitos E, Noutsios G, Pitiakoudis M, Polychronidis A, et al. The role of somatostatin in 67 consecutive pancreatectomies: a randomized clinical trial. *Clin Exp Gastroenterol.* 2010; 3(1):179–83.
10. Klempa I, Schwedes U, Usadel KH. [Prevention of postoperative pancreatic complications following duodenopancreatectomy using somatostatin]. *Chirurg.* 1979; 50(7):427–31.

Успешна постоперативна терапија фистуле панкреаса инфузијом соматостатина после ресекције дуоденалног гастроинтестиналног стромалног тумора

Маријуш Чабовски^{1,2}, Виктор Павловски^{1,2}, Михал Леснијак^{1,2}, Агњешка Зјомек^{1,2}, Мацеј Малиновски^{1,2}, Тадеуш Доробиш^{2,3}, Даријуш Јанчак^{1,2}

¹Медицински универзитет у Вроцлаву, Факултет здравствених наука, Катедра за хирургију, Вроцлав, Пољска;

²Четврта војнонаставна болница, Одељење хирургије, Вроцлав, Пољска;

³Медицински универзитет у Вроцлаву, Факултет постдипломских медицинских студија, Катедра за васкуларну, општу и трансплатациону хирургију, Вроцлав, Пољска

САЖЕТАК

Увод Према Међународној студијској групи за дефиницију панкреасне фистуле, постоперативна панкреасна фистула је сваки случај цурења течности трећег (или каснијег) постоперативног дана, када је ниво амилазе у испуштеној течности најмање три пута већи од нивоа амилазе у серуму. У зависности од степена и њиме условљеног третмана, панкреасне фистуле се деле у следеће три категорије: А (благи симптоми), Б и Ц (тешки симптоми). Без обзира на повољне услове, егзокрино лучење панкреаса је кључни фактор у формирању фистуле. Смањење секреције панкреаса изазване соматостатином и његовим еквивалентима у комбинацији са парентералном исхраном добро је утемељен метод у третману панкреасне фистуле.

Приказ болесника У овом раду приказан је 69-годишњи болесник који је био подвргнут ресекцији дуоденалног гастроинтестиналног стромалног тумора, који се налазио непосредно изнад велике дуоденалне папиле. У постопе-

ративном периоду је забележена прекомерна дренажа течности са високим нивоима амилазе. Конзервативни третман састојао се од континуиране инфузије соматостатина и парентералне исхране. Потпуно затварање фистуле је постигнуто 14. постоперативног дана, што је потврђено радикалним смањењем количине издрениране течности и ниским нивоом амилазе у сакупљеној течности. Болесник је остао у добром клиничком стању и отпуштен је из болнице 20. постоперативног дана.

Закључак Овај приказ представља пример рано дијагностиковане постоперативне панкреасне фистуле конзервативно лечене соматостатином. Постоперативно клиничко разумевање важности директног контакта стромалног тумора са ткивом панкреаса, у комбинацији са рутинским утврђивањем нивоа амилазе, довело је до брзе дијагнозе фистуле панкреаса, а терапија је довела до исхода без компликација.

Кључне речи: панкреасна фистула; соматостатин; гастроинтестинални стромални тумор; постоперативни ток