



## CASE REPORT / ПРИКАЗ БОЛЕСНИКА

## Human dirofilariasis

Svetlana Popović<sup>1</sup>, Vesna Begović-Kuprešanić<sup>1,2</sup>, Nataša Vešović<sup>3</sup><sup>1</sup>Military Medical Academy, Clinic for Infectious and Tropical Diseases, Belgrade, Serbia;<sup>2</sup>Military Medical Academy, Faculty of Medicine, Belgrade, Serbia;<sup>3</sup>Military Medical Academy, Clinic for Chest Surgery, Belgrade, Serbia

## SUMMARY

**Introduction** Dirofilariasis is a zoonosis caused by nematodes from the genus *Dirofilaria*, which is a parasite in dogs and other canids, and humans get infected by a mosquito bite. In Europe, the number of patients outside the endemic area is increasing. So far, more than 2,850 cases of human dirofilariasis have been reported worldwide. In the last 20 years, we have had only two confirmed cases in our institution. The disease is manifested in a cutaneous, visceral, and ocular form. From the initial infection, the first symptoms can take several years to manifest. The diagnosis can be confirmed histologically, morphologically, and/or by molecular techniques. The treatment includes surgical removal of the parasite and antiparasitic therapy.

**Case outline** The paper presents two cases of *Dirofilaria repens* infection. The first patient had a migratory nodular facial skin change for several years. After the skin induration incision in the zygomatic region, a 7-cm-long worm was extracted, later identified as *Dirofilaria repens*. The pathohistological finding of the extirpated change showed that it was a granuloma inflammation. The second case was a patient with a persistent cough and hemoptysis, with a morphologically verified nodular change in the pulmonary parenchyma. The pathohistological finding of the extirpated change showed a chronic granulomatous inflammation and the presence of parasites. The treatment of both patients resulted in a complete recovery without complications.

**Conclusion** In case of subcutaneous nodules or unclear lung changes, dirofilariasis should be considered. Video-assisted thoracoscopic surgery is the leading diagnostic surgical procedure concerning dirofilariasis, and a significant therapeutic modality.

**Keywords:** dirofilariasis; parasitosis; video-assisted thoracoscopic surgery

## INTRODUCTION

Dirofilariasis is a zoonosis caused by nematodes from the genus *Dirofilaria*. The parasite is transmitted to humans from infected animals, most often dogs, accidentally, by an infected mosquito bite. The infection includes only one worm, and it may take several decades until the first symptoms occur. The disease is benign and very rare outside the endemic area. In Europe, the number of patients has been steadily increasing for the last ten years [1]. There are three forms of the disease, subcutaneous, visceral and ocular.

By the year 2012, there were 1,782 cases of human dirofilariasis reported, out of which 1,410 in Europe, and 372 in the USA [2]. In Serbia, 37 cases were reported by 2014 [3]. The diagnosis is based on anamnestic data, clinical course, possible parasite visualization, surgical extirpation, pathohistological verification, and, rarely, serological diagnosis. The treatment can be surgical and conservative. Prophylaxis includes the treatment and prophylaxis in dogs as a reservoir, the suppression of mosquitoes as vectors, and the protection of humans by means of repellents.

Clinic for Infectious and Tropical Diseases of the Military Medical Academy in the last 20 years.

The first case was diagnosed in 1998 in a woman aged 64 from the village of Kusadak, located in the vicinity of Belgrade. She had had a migratory nodular facial skin change for several years. Since her youth, the patient had been having a dry, irritating cough, and later some problems in the form of redness and itching of the skin. Three years prior to diagnosis, some migratory tumor changes occurred on the scalp, and then she developed swelling and redness of the upper eyelid region. Further on, pain, redness and skin induration of the right zygomatic region occurred. When pressure was applied to the induration, a vital 7-cm-long parasite was extracted (Figure 1). The identification was carried out at the Institute of Medical Biochemistry of the Military Medical Academy where *D. Repens* female was confirmed. The patient's clinical findings were dominated by a zygomatic bone swelling, together with induration and hyperemia. All laboratory findings were within reference values, while serological analyses were negative. Histopathological examination of the extirpated change showed granuloma inflammation.

The second case was diagnosed in 2018 in a 72-year-old male from Belgrade. He first came to the doctor's due to persistent cough and hemoptysis. Morphological tests and multislice

## Received • Примљено:

January 21, 2019

## Revised • Ревизија:

May 22, 2019

## Accepted • Прихваћено:

July 11, 2019


Online first: August 14, 2019

## Correspondence to:

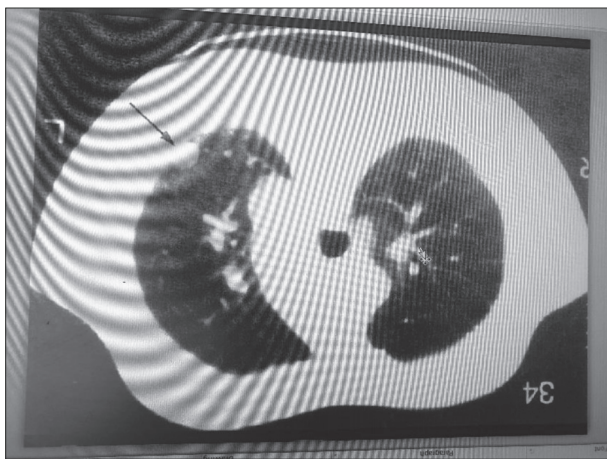
Svetlana POPOVIĆ  
Military Medical Academy  
Clinic for Infectious and Tropical  
Diseases  
17 Crnotravska Street  
Belgrade 11000, Serbia  
[cecipopovic@gmail.com](mailto:cecipopovic@gmail.com)

## CASE REPORT

This paper presents two cases of *Dirofilaria repens* infection, which were confirmed at the



**Figure 1.** Extracted vital 7-cm-long parasite



**Figure 2.** Multislice computed tomography of the thorax showed a lobulated, infiltrative change  $16 \times 16 \times 11$  mm in segment VI of the right lower lung lobe

computed tomography (MSCT) of the thorax showed a lobulated, infiltrative change  $16 \times 16 \times 11$  mm in segment VI of the right lower lung lobe, showing signs of infiltration of the surrounding parenchyma, followed by minimal pneumonitis (Figure 2). Video-assisted thoracoscopic surgery (VATS) was performed and a knot tissue sample  $27 \times 15$  mm in size was obtained. Histopathological examination showed chronic granulomatous inflammation with necrosis similar to dirofilariasis. The patient was feeling well all the time and all his laboratory parameters were within reference values. Albendazole therapy was used for 28 days. In the further course of the disease, the patient lost all subjective symptoms, while the definitive suspicion of a malignant neoplasm was removed by the control MSCT thorax examination.

## DISCUSSION

Natural hosts of *Dirofilaria* are dogs and wild canids, such as foxes, wolves, and raccoons. Humans get infected by a mosquito bite. In Serbia, every species of mosquitoes transmits the parasite [4]. The infection in humans is most commonly caused by three species: *D. immitis*, *D. repens*, and

*D. tenius*. *Dirofilaria immitis* usually causes human pulmonary dirofilariasis throughout the world, while subcutaneous dirofilariasis caused by *D. repens* is recorded in Europe [5]. These two species are able to cause both pulmonary and extrapulmonary infection. It most commonly occurs in adults between the ages of 21 and 60 years (ESDA), but the case of a 14-month-old child with *Dirofilaria* in the scrotum region has also been described, which is its most common localization in children [6]. Women are more likely to be infected than men, but without a significant statistical difference. Generally, it occurs rarely in people, has a benign character, and, in most cases, the diagnosis is made by histopathological examination, and extremely rarely, as in our first case, by the evacuation of a live parasite.

The endemic areas for dirofilariasis are Asia, Africa, the Mediterranean, but in the past decade, there has been an increasing number of cases reported outside the endemic area, i.e. in the region of northern and central Europe [1]. The highest percentage of cases was registered in Italy (66%), followed by France (22%), Greece (8%), and Spain (4%) [7]. *D. repens* spread faster than *D. immitis* from the endemic areas of southern Europe to northern Europe [8].

Risk factors and predispositions are not clear and well defined. The number of dogs in a given area, the prevalence of infection, the number of infected mosquitoes, and human exposure can contribute to the spread of the disease in certain geographical areas. It is believed that the risk of human pulmonary dirofilariasis is greater in periods of natural disasters, most likely due to the occurrence of floods, more mosquitoes, and an increase in the number of stray dogs [1]. In Serbia, during a period of 10 years, dog seroprevalence went from 7% to 26.9% (2004–2014) [9].

The anatomical localization as well as the clinical presentation of this parasite varies. Ophthalmic presentation accounts for 40% of reported cases. Nodular localization is found on the head and neck in 18.9–25.3%, in the extremities in 14.8–22.1%, in the torso in 11.4–11.8%, in male genitalia in 2.9–4.1%, in female breasts in 2.5–2.7% of the cases. Cases of unencapsulated forms in peritoneum have also been described in 0.6% of cases [10]. A large majority of patients with dirofilariasis had one painful subcutaneous nodule, without signs of infection. In the case of ocular localization, symptoms are the feeling of burning, itching, and pain in the eye. The majority of patients with pulmonary dirofilariasis are asymptomatic, while 38% have symptoms in the form of cough, fever, and hemoptysis [8].

The diagnosis of the disease is based on the possible visualization of the parasite, as well as the pathohistological verification. VATS has been proven to be the best, both diagnostic and therapeutic, method, because in this way a safe differential diagnosis is performed concerning malignant diseases, tuberculosis, pulmonary thromboembolism, and Wegener's granulomatosis [2].

There are serological tests, but they are rarely available, are not satisfactory, give cross-positive results with other filariases, most commonly with *Toxocar canis* nematode [2]. Bearing in mind all the aforementioned, we may conclude that serological tests should be used exclusively as

supplemental diagnostic procedures. Eosinophilia is present in less than 20% of cases [2]. The differential diagnosis of pulmonary forms of dirofilariasis between a malignant tumor and benign lesion is a major diagnostic challenge. Usually, lesions are detected in the lower right lung, in the form of subpleural pulmonary nodules, 1–3 cm in size. Pulmonary nodules can be individual, multiple, and bilateral. Their radiological signs are non-specific, which causes differential diagnostic problems that cannot be resolved by diagnostic procedures such as MSCT and nuclear magnetic resonance. However, VATS leads to the ultimate and definitive diagnosis, which puts this diagnostic therapeutic modality first in diagnostics, but also in the treatment of human dirofilariasis. After performing the VATS resection and diagnosis of human dirofilariasis, other therapeutic procedures are not necessary [1].

## REFERENCES

1. Grapatsas K, Kayser G, Passlick B, Wiesemann S. Pulmonary coin lesion mimicking lung cancer reveals an unexpected finding: *Dirofilaria immitis*. *J Thorac Dis*. 2018; 10(6):3879–82.
2. Diaz JH. Increasing risks of human dirofilariasis in travelers. *J Travel Med*. 2015; 22(2):116–23.
3. Tasić-Otašević AS, Trenkić-Božinović SM, Gabrielli VS, Genchi C. Canine and human *Dirofilaria* infections in the Balkan Peninsula. *Vet Parasitol*. 2015; 209(3–4):151–6.
4. SASAP – Udruženje veterinara male prakse Srbije – bolest srčanog crva – stručne smernice. 11. 10. 2016; Beograd, Srbija.
5. Ferrari PA, Grisolia A, Reale S, Liotta R, Mularoni A, Bertani A. A rare case of human pulmonary dirofilariasis with nodules mimicking malignancy: approach to diagnosis and treatment. *J Cardiothorac Surgery*. 2018; 13(1):65.
6. Tumolskaya NI, Pozio E, Rakova VM, Supriage VG, Sergiev VP, Morozov LF, et al. *Dirofilaria immitis* in a child from the Russian Federation. *Parasite*. 2016; 23:37.
7. Klochko A, Wallace MR. Dirofilariasis. Update: Jul 22, 2013. Available at [emedicine.medscape.com/article/236698](http://emedicine.medscape.com/article/236698).
8. Capelli G, Genchi C, Baneth G, Bourdeau P, Brianti E, Cardoso L, et al. Recent advances on *Dirofilaria repens* in dogs and humans in Europe. *Parasit Vectors*. 2018; 11(1):663.
9. Savić S, Vidić B, Pajković D, Spasojević-Kosić Lj, Medić S, Potkonjak A, et al. Overview of dirofilariasis in Serbia during the last the years 2004–2014 and current status of the disease. Fourth European *Dirofilaria* and *Angiostrongylus* Days, July 2–4, 2014; Budapest, Hungary.
10. ESDA. Guidelines for clinical management of human dirofilaria infections. Copyright 2017.

## Хумана диروفиларијаза

Светлана Поповић<sup>1</sup>, Весна Беговић-Купрешанин<sup>1,2</sup>, Наташа Вешовић<sup>3</sup>

<sup>1</sup>Војномедицинска академија, Клиника за инфективне и тропске болести, Београд, Србија;

<sup>2</sup>Војномедицинска академија, Медицински факултет, Београд, Србија;

<sup>3</sup>Војномедицинска академија, Клиника за грудну хирургију, Београд, Србија

### САЖЕТАК

**Увод** Диروفиларијаза је зооноза изазвана нематодом из рода *Dirofilaria*, која је паразит паса и других канида, а човек се инфицира убодом комарца. У Европи се повећава број оболелих ван ендемског подручја. До сада је у свету пријављено више од 2850 случајева хумане диروفиларијазае. У нашој установи су у последњих 20 година потврђена само два случаја хумане диروفиларијазае. Болест се манифестује као кутана, висцерална и офталмична форма. До појаве првих симптома болести може проћи и више десетина година од настанка инфекције. Дијагноза се може потврдити хистолошки или морфолошки и/или применом молекуларних техника. Лечење је хируршко уклањање паразита и примена антипаразитарне терапије.

**Приказ болесника** У раду су приказана два случаја инфекције нематодом *Dirofilaria repens*. Прва болесница је више година имала промене на кожи лица миграторног карактера са формирањем нодуларне промене. После инцизије индур-

рације на кожи зигоматичне регије извађен је црв величине 7 cm, који је идентификован као *Dirofilaria repens*. Други случај је болесник са израженим кашљем и хемоптизијама, код кога је морфолошким претрагама установљена промена нодуларног изгледа у плућном паренхиму. Патохистолошки налаз екстирпираних промена је показао хронично грануломско запаљење и присуство паразита. Патохистолошки налаз екстирпираних нодуларних промена у целисти на месту извађеног паразита је показао да се ради о грануломској инфламацији. Лечење оба болесника је завршено успешно.

**Закључак** У случају појаве поткожних нодула или нејасних промена на плућима треба мислити на диروفиларијазу. Видеоасистирана торакоскопска хирургија је хируршка процедура која заузима водеће место у процесу дијагностике диروفиларијазае, али и значајан терапијски модалитет.

**Кључне речи:** диروفиларијаза; паразитоза; видеоасистирана торакоскопска хирургија