



CASE REPORT / ПРИКАЗ БОЛЕСНИКА

Urrets-Zavalía syndrome following posterior segment surgery – case report and review of literature

Dragan R. Vuković^{1,2}, Antoaneta Adžić³, Sanja Petrović-Pajić²

¹University of Belgrade, Faculty of Medicine, Belgrade, Serbia;

²Clinical Center of Serbia, Clinic of Eye Diseases, Belgrade, Serbia;

³University of Montenegro, Faculty of Medicine, Clinical Centre of Montenegro, Clinic of Eye Diseases, Podgorica, Montenegro

SUMMARY

Introduction Urrets-Zavalía syndrome (UZS) has been defined as a fixed and dilated pupil accompanied by iris atrophy and occasionally secondary glaucoma. The precise cause of the syndrome is uncertain. Most often it has been described following anterior segment surgery.

The objective of this article is to present how to successfully handle patients with UZS after posterior segment surgery. We present all the dilemmas and difficulties we encountered during the diagnostic process.

Case outline This is a case presentation of a patient with UZS following scleral buckle procedure. To our knowledge, this is the first case of UZS following this type of posterior segment surgery. The delay in treatment was mostly due to the lack of knowledge about the linkage of this syndrome with posterior segment surgery. Once the diagnosis was confirmed, parasympathomimetic drops were administered. The patient responded well to the therapy and partial reduction of mydriasis and restoration of pupillary kinetics was observed.

Conclusion Two months after surgery, the treatment of UZS resulted in slight residual anisocoria with signs of iris atrophy. This could indicate reversible mechanism of UZS after posterior segment surgery with iris atrophy as the only permanent consequence.

Keywords: Urrets-Zavalía syndrome; retinal detachment; scleral buckling; pars plana vitrectomy

INTRODUCTION

Urrets-Zavalía syndrome (UZS) has been identified as a fixed and dilated pupil accompanied by iris atrophy and, occasionally, secondary glaucoma. It has been often described following penetrating keratoplasty for keratoconus in patients who have mydriatics in therapy [1]. The precise cause of the syndrome is uncertain. There have been several reported cases of UZS after deep anterior lamellar keratoplasty for keratoconus, Descemet's stripping endothelial keratoplasty for Fuch's endothelial dystrophy, argon laser peripheral iridoplasty, surgical trabeculectomy and phacic anterior chamber intraocular lens implantation [2–5]. The precise cause of the syndrome is uncertain.

We report a case of UZS following scleral buckling surgery, which is, to the best of our knowledge, the first such reported case in the available literature.

This case report was approved by the institutional ethics committee, and written consent was obtained from the patient for the publication of this case report and any accompanying images.

the lower nasal part of the left eye visual field three days prior to the examination. Best corrected visual acuity on the Snellen chart was 0.3 on the left eye and 0.9 on the right one. From teenage years our patient has been myopic: -3.5 Dsph on the right, and -6.5 Dsph on the left eye. Other than high blood pressure, the patient had no health issues.

The examination of the left eye showed retinal tear on the one o'clock with retinal detachment in the upper temporal quadrant. The macula was attached.

The patient was operated on the following day. We performed scleral buckling with equatorial encircling band. On the first postoperative day, the retina was reattached, there was some corneal edema and visual acuity was 3/60. The patient was discharged with standard corticosteroid and antibiotic therapy, but on the next day he returned to our emergency center with extreme pain in the operated eye. His eye lids were swollen, he had corneal edema, slightly wider left eye pupil and inflammatory reaction in the anterior chamber. Intraocular pressure was 30 mmHg and responded well to the administered local anti-glaucomatous drugs.

On the check-up two days later, intraocular pressure on the patient's left eye was 8 mmHg, there was no corneal edema or inflammatory reaction. We reduced the anti-glaucomatous therapy and 10 days later cancelled it completely because his intraocular pressure was

Received • Примљено:

February 6, 2018

Revised • Ревизија:

June 4, 2018

Accepted • Прихваћено:

January 11, 2019

Online first: March 8, 2019

Correspondence to:

Dragan R. VUKOVIĆ
Clinic of Eye Diseases
Clinical Center of Serbia
Pasterova 2
11000 Belgrade, Serbia
draganv@beotel.net

CASE REPORT

A 56-year-old male patient was referred to our clinic because he noticed a "black shadow" in

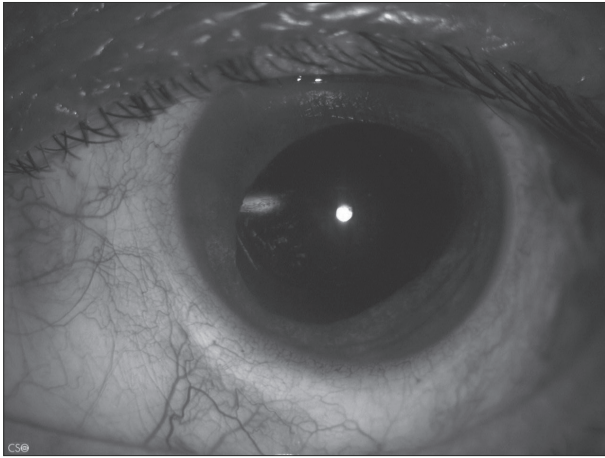


Figure 1. Dilated irregular pupil and iris subatrophy in the lower part two weeks after the operation

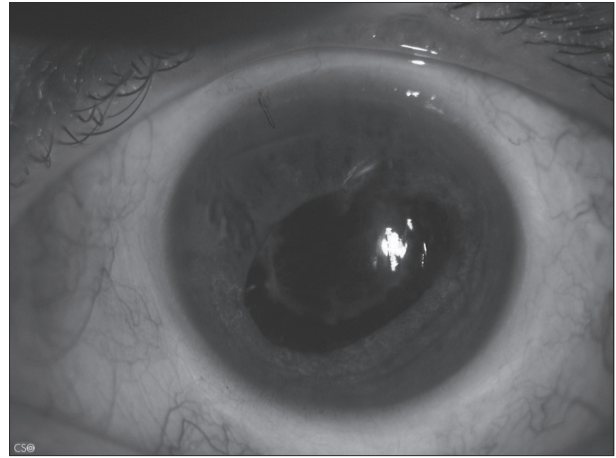


Figure 2. Significantly narrower, still irregular pupil without posterior synechiae and significant opacification of the posterior capsule four weeks after the operation

10 mmHg. The left eye pupil was dilated but we believed it was the effect of the mydriatic eye drops. We were unable to immediately identify the cause of this reaction.

According to the data provided by our patient, his visual acuity improved during the following period. However, in two months he noticed a black shadow in the nasal half of the visual field and he had retinal re-detachment temporally with proliferative vitreoretinopathy. Upon the admission we noticed that the patient's left pupil was dilated, he had posterior synechiae, iris atrophy particularly in the inferior part and incipient anterior subcapsular cataract. The left eye visual acuity was 0.1 on the Snellen chart with a shallow retinal detachment in the macular region. We operated on the patient the next day. Phacoemulsification and pars plana vitrectomy with internal silicon oil tamponade were performed. The patient was discharged on the following day with a normal intraocular pressure and best corrected visual acuity of 0.4 on the Snellen chart. On the check-up two weeks after the surgery, we noticed an even more dilated pupil with wide posterior synechiae and significant iris atrophy (Figure 1).

It was only then that we suspected Urrets-Zavalía syndrome so parasympathomimetic eye drops were introduced three times daily. Three weeks later, the patient had noticed that the left eye pupil was narrower so he reported to the clinic. We registered a significant narrowing of the left eye pupil (Figure 2). The best corrected visual acuity was 0.5 on the Snellen chart and the intraocular pressure was 12 mmHg.

DISCUSSION

To date it has been difficult to explain the UZS etiology following keratoplasty. Past studies examined a number of possible causal factors including strong mydriasis further causing peripheral anterior synechiae and glaucoma, direct iris trauma during surgery, iris ischemia following iris compression between the lens and the cornea during surgery, an abnormal immunological, neurological and iris

in keratoconic eyes, intraocular pressure (IOP) rise, preexisting anterior synechiae [2, 6–11]. Furthermore, different studies reported UZS development following complicated diffuse lamellar keratitis with intraoperative microperforation of the Descemet membrane and air bubble in the anterior chamber. It was proposed that the air bubble could cause a pupil block, raised IOP, and secondary iris ischemia with a dilated, fixed pupil [12].

Raised IOP and low ocular rigidity of the eye with keratoconus may cause occlusion of the vessels at the root of the iris within the sclera resulting in iris ischemia, while preserving ciliary body function [10]. This may also be the reason for UZS development in the presented case since scleral buckle may cause transient rise of the IOP, as well as compromise scleral rigidity.

Pathophysiological mechanism of sympathetic spasm with parasympathetic inhibition was suggested since early resolution of UZS with an association of sympatholytic and parasympathomimetic drops has been described in the literature [12].

Since the presented case was the first of its kind, it was diagnosed late so the use of parasympathomimetic drops started two months after primary surgery. We do not know what the permanent consequences of UZS following posterior segment surgery are nor do we know what the deadline for the introduction of topical therapy for avoiding more serious complications is. We started with parasympathomimetic drops two months after primary surgery. The resolution of UZS ensued after three weeks of parasympathomimetic therapy. This could indicate a reversible mechanism of UZS after posterior segment surgery with iris atrophy as the only permanent consequence. The therapeutic effects were determined according to the significant narrowing of the eye pupil and the stabilization of IOP.

What is the best time to start the therapy and how long should it be administered? These questions need answers. Hence, further investigation of this rare disease is warranted.

Conflict of interest: None declared.

REFERENCES

1. Spierer O, Lazar M. Urrets-Zavalía syndrome (fixed and dilated pupil following penetrating keratoplasty for keratoconus) and its variants. *Survey of Ophthalmology*. 2014; 59(3):304–10.
2. Maurino V, Allan BDS, Stevens JD. Fixed dilated pupil (Urrets-Zavalía syndrome) after air/gas injection after deep lamellar keratoplasty for keratoconus. *Am J Ophthalmol*. 2002; 133(2):266–8.
3. Srinivasan M, Lolly P. Fixed dilated pupil (Urrets-Zavalía Syndrome) in Corneal Dystrophies. *Cornea*. 2004; 23(1):81–3.
4. Espana E, Ioannidis A, Tello C, Liebmann JM, Foster PJ, Ritch R. Urrets-Zavalía syndrome as a complication of Argon Laser Peripheral Iridoplasty. *Br J Ophthalmol*. 2007; 91(4):427–9.
5. Yuzbasioglu E, Helvacioğlu F, Sencan S. Fixed, dilated pupil after phakic lens implantation. *J Cataract Refract Surg*. 2006; 32(1):174–6.
6. Urrets-Zavalía A. Fixed dilated pupil, iris atrophy and secondary glaucoma: a distinct clinical entity following penetrating keratoplasty for keratoconus. *Am J Ophthalmol*. 1963; 56:257–65.
7. Minasian M, Ayliffe W. Fixed dilated pupil following deep lamellar keratoplasty (Urrets-Zavalía syndrome). *Br J Ophthalmol*. 2002; 86(1):115–6.
8. Jain R, Assi A, Murdoch IE. Urrets-Zavalía syndrome following trabeculectomy. *Br J Ophthalmol*. 2000; 84(3):338–9.
9. Davies PD, Ruben M. The parietic pupil: its incidence and etiology after keratoplasty for keratoconus. *Br J Ophthalmol*. 1975; 59(4):223–8.
10. Tuft SJ, Buckley RJ. Iris ischemia following penetrating keratoplasty for keratoconus (Urrets-Zavalía syndrome). *Cornea*. 1995; 14(6):618–22.
11. Nguyen NX, Langenbucher A, Seitz B, Kuchle M. Frequency and risk factors of intraocular pressure increase after penetrating keratoplasty. *Klin Monbl Augenheilkd*. 2000; 217(2):77–81.
12. Lagoutte F, Thienpont P, Comte P. Proposed treatment of Urrets-Zavalía syndrome. A propose of one reversible case. *J Fr Ophtalmol*. 1983; 6(3):291–4.

Синдром Уретс-Завалије после хирургије задњег сегмента ока – приказ случаја и преглед литературе

Драган Р. Вуковић^{1,2}, Антоанета Аџић³, Сања Петровић-Пајић²

¹Универзитет у Београду, Медицински факултет, Београд, Србија;

²Клинички центар Србије, Клиника за очне болести, Београд, Србија;

³Универзитет Црне Горе, Медицински факултет, Клинички центар Црне Горе, Клиника за очне болести, Подгорица, Црна Гора

САЖЕТАК

Увод Синдром Уретс-Завалије (СУЗ) дефинише се као фиксирана и дилатирана пупила праћена атрофијом ириса и повремено са секундарним глаукомом. Тачан узрок овог синдрома је још увек непознат. Најчешће је описан у вези са операцијама на предњем сегменту ока.

Циљ овог рада је да представи како је могуће успешно решити случај СУЗ после хирургије на задњем сегменту ока.

Приказ случаја Ово је приказ случаја болесника са СУЗ који је настао после операције аблације ретине методом склералне копче. Приказани случај је први СУЗ после овог типа операције на задњем сегменту ока. Приказали смо све потешкоће и дилеме које смо имали у постављању ове дијаг-

нозе. Каснији почетак лечења је био због недовољног знања о овом синдрому везаног за операције на задњем сегменту ока. После постављања дијагнозе СУЗ аплицирали смо парасимпатикомиметске капи и добили делимично смањење мидријазе и опоравак пупиларне кинетике.

Закључак Два месеца после операције лечење СУЗ се завршило благом резидуалном анизокоријом са знацима атрофије ириса. Ово указује на реверзибилни механизам СУЗ после операција аблације ретине са атрофијом ириса као трајном последицом.

Кључне речи: синдром Уретс-Завалија; аблација ретине, класична операција аблације ретине; витректомија