

## CASE REPORT / ПРИКАЗ БОЛЕСНИКА

# Primary sinonasal ameloblastoma – a rare cause of unilateral nasal obstruction

Ognjen Čukić<sup>1</sup>, Aleksandar Oroz<sup>1</sup>, Nenad Miladinović<sup>2</sup><sup>1</sup>Zemun Clinical Hospital Centre, Department of Otorhinolaryngology with Maxillofacial Surgery, Belgrade, Serbia;<sup>2</sup>Zemun Clinical Hospital Centre, Department of Clinical Pathology, Belgrade, Serbia**SUMMARY**

**Introduction** Ameloblastoma is a rare, locally invasive benign jaw tumour, originating from odontogenic epithelium, and their presence in the sinonasal tract is usually due to their spread from the gnathic region of the maxilla. Primary sinonasal ameloblastoma is extremely rare, with only a handful of reported cases so far. The objective of this article was to describe a patient with a primary ameloblastoma of the right maxillary sinus and nasal cavity.

**Case outline** We report a case of a 67-year-old male patient with a year-long history of progressive unilateral nasal obstruction. Clinical and computed tomography examination revealed a mass in the right maxillary sinus and right nasal cavity. After an in-office biopsy under local anesthesia, which suggested the diagnosis of ameloblastoma, the patient underwent complete removal of the mass by a medial partial maxillectomy. Histopathologic analysis confirmed the diagnosis of ameloblastoma.

**Conclusion** Primary sinonasal ameloblastoma is clinically and radiographically similar to the more common pathology of this particular area and should be included in the differential diagnosis of the unilateral nasal obstruction. The treatment of choice is complete surgical resection. Due to the rarity of the disease, and a small number of cases described so far in the literature, there is still no consensus regarding the optimal surgical technique.

**Keywords:** ameloblastoma; sinonasal tumour; paranasal sinuses; maxillectomy

**INTRODUCTION**

Ameloblastomas are rare, locally invasive benign tumours originating from odontogenic epithelium [1]. They account about one percent of all jaw tumours, with mandible more frequently affected than maxilla [2]. Primary sinonasal ameloblastomas without involving the maxillary alveolus are extremely rare. In this article, we describe the case of sinonasal ameloblastoma located in the right maxillary sinus, and in the right nasal cavity, which was initially biopsied in ambulatory setting and subsequently treated by partial medial maxillectomy.

**CASE REPORT**

A 67-year-old male patient was admitted to our department with a year-long history of a progressive, right-sided nasal obstruction. Relevant medical history included hypertension and glaucoma, for which he was taking regular medication. There was no history of prior sinonasal disease, allergies, or tobacco use. Anterior rhinoscopy revealed a solitary polypoid lesion, originating from the middle meatus (*meatus nasi medius*) and partially involving the common nasal meatus (*meatus nasi communis*) on the right side. The surface of the lesion did not have the typical “glassy” appearance of nasal

polyp and was somewhat more firm on palpation. A computed tomography scan of the nasal cavity and paranasal sinuses demonstrated mixed-density mass, completely dimming the right maxillary sinus, with displacement and partial destruction of its medial wall and propagation in the nasal cavity (Figure 1). An in-office biopsy under local anesthesia was performed and initial histopathologic examination suggested an ameloblastoma diagnosis. The patient then underwent the right partial medial maxillectomy through the modified Weber-Ferguson incision (Figure 2). During the operation, the solid and well-defined lesion completely filling the right maxillary sinus was noted, along with its intranasal component, which was observed on initial clinical examination. The lesion was removed in *en-bloc* fashion, together with the medial wall of the maxillary sinus, including the inferior nasal concha. The structures removed resulted in the creation of wide antrostomy, which would further facilitate the postoperative examinations using the rigid Hopkins telescopes. The definitive diagnosis of ameloblastoma was confirmed by histopathology (Figure 3). The postoperative period was uneventful and the patient was discharged four days following surgery. The patient is currently on regular endoscopic follow-ups, which have shown no recurrence of the disease 10 months after surgery.

**Received • Примљено:**  
May 11, 2018

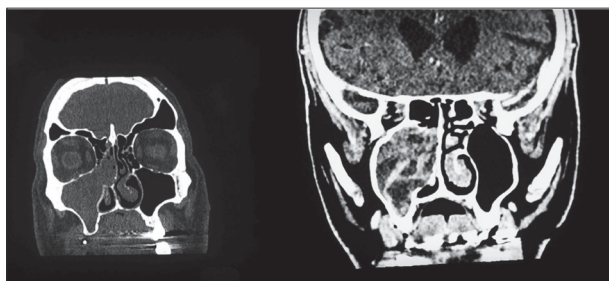
**Revised • Ревизија:**  
November 13, 2018

**Accepted • Прихваћено:**  
December 16, 2018

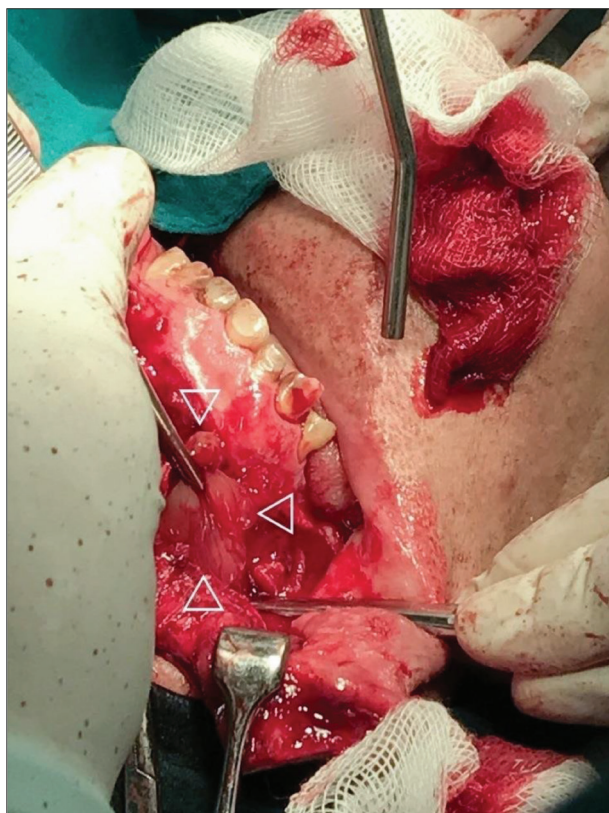
**Online first:** February 1, 2019

**Correspondence to:**

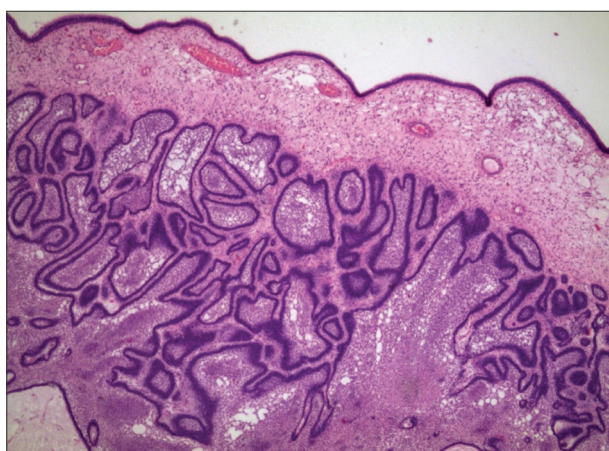
Ognjen ČUKIĆ  
Zemun Clinical Hospital Centre  
Department of  
Otorhinolaryngology with  
Maxillofacial Surgery  
Vukova 9  
11080 Belgrade, Serbia  
[ognjen.cukic.bg@gmail.com](mailto:ognjen.cukic.bg@gmail.com)



**Figure 1.** Coronal computed tomography of the nasal cavity and paranasal sinuses (bone and soft tissue windows) demonstrating a mixed density mass in the right maxillary sinus and with an extension to the right nasal cavity



**Figure 2.** The tumour (triangles) exposed through the modified Weber-Ferguson incision



**Figure 3.** The tumour consisting of loosely arranged stellate cells resembling the stellate reticulum of the tooth germ, surrounded by peripheral rim of palisading cells (hematoxylin-eosin, 25X)

## DISCUSSION

Most ameloblastomas in the sinonasal region appear secondary to an extension of a tumour of gnathic origin into this area [3]. However, primary sinonasal ameloblastomas without evident gnathic involvement, have also been described [4, 5]. Unlike their gnathic counterparts, which usually appear between the age of 35 and 45 with no distinct sex predilection, sinonasal ameloblastomas mostly affect male patients in their 60s and 70s [6]. The proximity of the odontogenic apparatus and sinonasal cavity during embryogenesis could potentially result in misplacement of odontogenic cells in the sinonasal epithelium or the abnormal differentiation of the pluripotent basal cells of the sinonasal mucosa. The possibility that it originates from the bony structures of the nasal turbinates has also been proposed [5, 6]. It is unclear whether the chronic inflammation of the sinonasal mucosa may be the triggering event in the pathogenesis of ameloblastoma, or if it is secondary due to tumour presence in the sinonasal tract [7]. Histologically, ameloblastomas are benign neoplasms with locally aggressive behaviour and marked tendency for late recurrence. Cases of malignant alteration and distant metastases, although exceptionally rare, have also been reported [8, 9]. They manifest with nonspecific nasal symptomatology, including progressive nasal obstruction, recurrent epistaxis, facial swelling or sinusitis. On examination, a soft tissue mass in the nasal cavity is usually noted. Clinically and radiologically, sinonasal ameloblastomas are indistinguishable when compared to more common nasal pathology such as polyps, chronic sinusitis, or inverted papilloma. Unilateral nasal involvement and computed tomography signs of bone affection should raise suspicion of a neoplastic process, and definitive diagnosis of ameloblastoma is only possible with a biopsy followed by histopathological analysis. A wide surgical excision is the treatment of choice [10]. The choice of operation is usually dictated by the extent of the disease. A variety of transfacial approaches, such as lateral rhinotomy, sublabial or Weber-Ferguson incisions provide good visual control and enable wide excision. Simple curettage of maxillary sinus is usually associated with recurrence. Wider excisions by means of partial or radical maxillectomy have better outcomes. Recently, endoscopic management of ameloblastomas has been described, with reportedly less perioperative morbidity and better disease control [11]. A combined transfacial and endoscopic approach was reported [12]. In the case we described, we have chosen medial maxillectomy through modified Weber-Ferguson incision, based on the involvement of both of nasal cavity and of maxillary sinus, as well as computed tomography scan evidence of bone affection of its medial wall. Currently there is no consensus regarding the choice of surgical technique, because of the small number of reported cases. In cases of infiltrative tumours where complete removal proves difficult or impossible due to its adherence to the surrounding structures, postoperative radiotherapy can be used as an adjuvant treatment [13]. In our case, the tumour was well defined and was completely removed through the selected

approach without difficulties. Radiotherapy could be used as a single therapy in the case of locally advanced disease uncontrollable by surgery alone [14].

Given the benign histologic nature of sinonasal ameloblastoma and its high potential for local recurrence, we would favor the wide surgical excision, which we achieved through transfacial approach. The definitive choice of surgical treatment for sinonasal ameloblastoma is still controversial and requires a larger series of patients. Due to

the tumour potential for late recurrence, regular periodic checkups are essential and the exact treatment outcome should only be assessed after a long-term follow-up. In our case, wide communication of the nasal cavity with the remnant of the maxillary sinus was created, thus providing relatively simple follow-up using rigid Hopkins telescopes in outpatient service.

**Conflict of interest:** None declared.

## REFERENCES

- Ledesma-Montes C, Mosqueda-Taylor A, Carlos-Bregni R, de Leon ER, Palma-Guzman JM, Paez-Valencia C, et al. Ameloblastomas: a regional Latin-American multicentric study. *Oral Dis.* 2007; 13(3):303–7.
- Kim SG, Jang HS. Ameloblastoma: a clinical, radiographic, and histopathologic analysis of 71 cases. *Oral Surg Oral Med Oral Pathol Oral Radiol Endod.* 2001; 91(6):649–53.
- Tsaknis PJ, Nelson JF. The maxillary ameloblastoma: an analysis of 24 cases. *J Oral Maxillofac Surg.* 1980; 38(5):336–42.
- Tranchina MG, Amico P, Galia A, Emmanuelle C, Saita V, Fraggetta F. Ameloblastoma of the sinonasal tract: report of a case with clinicopathologic considerations. *Case Rep Pathol.* 2012; 2012:218156.
- Leong SC, Karkos PD, Krajacevic J, Islam R, Kent SE. Ameloblastoma of the sinonasal tract: a case report. *Ear Nose Throat J.* 2010; 89(2):70–1.
- Schafer DR, Thompson LD, Smith BC, Wenig BM. Primary ameloblastoma of the sinonasal tract: a clinicopathologic study of 24 cases. *Cancer.* 1998; 82(4):667–74.
- Shahidi Sh, Broonosh P, Daneshbod Y. Follicular ameloblastoma presenting as a sinonasal tumor. *Iran Red Crescent Med J.* 2012; 14(2):113–6.
- Shaw HJ, Katsikas DK. Ameloblastoma of the maxilla: a clinical study with four cases. *J Laryngol Otol.* 1972; 87(9):873–84.
- Eliasson AH, Moser RJ, Tenholder MF. Diagnosis and treatment of metastatic ameloblastoma. *South Med J.* 1989; 82(9):1165–8.
- Mendenhall WM, Werning JW, Fernandes R, Malyapa RS, Mendenhall NP. Ameloblastoma. *Am J Clin Oncol.* 2007; 30(6):645–8.
- London SD, Schlosser RJ, Gross CW. Endoscopic management of benign sinonasal tumors: a decade of experience. *Am J Rhinol.* 2002; 16(4):221–7.
- Bray D, Michael A, Falconer DT, Kaddour HS. Ameloblastoma: a rare nasal polyp. *J Laryngol Otol.* 2007; 121(1):72–5.
- Guilemany JM, Ballesteros F, Alos L, Albid I, Prades E, Menendez LM, et al. Plexiform ameloblastoma presenting as a sinonasal tumor. *Eur Arch Otorhinolaryngol.* 2004; 261(6):304–6.
- Kennedy WR, Werning JW, Kaye FJ, Mendenhall WM. Treatment of ameloblastoma and ameloblastic carcinoma with radiotherapy. *Eur Arch Otorhinolaryngol.* 2016; 273(10):3293–7.

## Примарни синоназални амелобластом – редак узрок једностране носне опструкције

Огњен Чукић<sup>1</sup>, Александар Ороз<sup>1</sup>, Ненад Миладиновић<sup>2</sup>

<sup>1</sup>Клиничко-болнички центар „Земун“, Служба оториноларингологије са максиларно-фарингеалном хирургијом, Београд, Србија;

<sup>2</sup>Клиничко-болнички центар „Земун“, Служба за клиничку патологију, Београд, Србија

### САЖЕТАК

**Увод** Амелобластоми су ретки, локално инвазивни бенигни тумори вилица који потичу од одонтогеног епитела, а њихова појава у пределу носа и синуса је најчешће последица ширења тумора из загрижајног предела горње вилице. Примарни амелобластоми носно-синусне регије су изузетно ретки и до сада је описано свега неколико случајева.

Циљ овог чланка је био да прикажемо случај болесника са примарним амелобластомом десног максиларног синуса и носне шупљине.

**Приказ болесника** Приказујемо случај мушкарца старог 67 година са прогресивном једностраном носном опструкцијом. Клинички налаз и компјутеризована томографија су указали на експанзивну промену у десном максиларном

синусу и у десној носној шупљини. После биопсије у локалној анестезији, која је указала на амелобластом, учињене су парцијална медијална максилектомија и ресекција тумора. Хистопатолошка анализа је потврдила дијагнозу амелобластома.

**Закључак** Примарни амелобластом носно-синусне регије је клинички и радиолошки сличан чешћој патологији ове регије и требало би га укључити у диференцијалну дијагнозу једностране носне опструкције. Лечење избора је комплетна хируршка ресекција. С обзиром на реткост овог обољења, као и на мали број до сада описаних случајева, тренутно не постоји сагласност о оптималној хируршкој техници.

**Кључне речи:** амелобластом; носно-синусни тумор; параназалне шупљине; максилектомија