



## REVIEW ARTICLE / ПРЕГЛЕД ЛИТЕРАТУРЕ

# Dysfunction of the arteriovenous fistula for hemodialysis as a consequence of venous neointimal hyperplasia and treatment strategies

Radojica Stolić

University of Kragujevac, Faculty of Medical Sciences, Department of Internal Medicine, Serbia

**SUMMARY**

One of the main problems related to inadequate planning of vascular access is dysfunction during maturation. Arteriovenous fistula dysfunction is most often a consequence of neointimal hyperplasia. Important causes for initial dysfunction of the fistula include narrow lumens of the arteries and veins used for anastomosis, damage to the vascular endothelium during fistula creation, previous venipuncture, postoperative development of venous collaterals, the impact force of friction on the arteriovenous anastomosis, a genetic predisposition for development of vascular stenosis, neointimal hyperplasia and previously persistent venous neointimal hyperplasia.

Any damage to the endothelium is a stimulus for neointimal hyperplasia. During surgery for creating the fistula, endothelial cells separate on the intima, edema appears, fibrin is deposited, leukocytes and platelets infiltrate. Spotted edema and necrosis of smooth muscle cells appear in the media.

In order to determine an adequate therapeutic strategy, the pathogenesis of intimal hyperplasia has been widely considered from different aspects. It is currently based on preoperative preservation of veins and careful selection of blood vessels, percutaneous transluminal angioplasty or surgical revision. Nevertheless, no current therapeutic strategies provide appropriate recommendations to improve maturation of the arteriovenous fistula. Notwithstanding considerable knowledge about the pathogenesis of venous neointimal hyperplasia, currently no prophylactic treatments would reduce its progression.

**Keywords:** hemodialysis; arteriovenous fistula; dysfunction; pathogenesis; venous neointimal hyperplasia; therapeutic strategy

## FUNCTIONALITY OF ARTERIOVENOUS FISTULAS AND THE MOST SIGNIFICANT COMPLICATIONS

More than 940 patients per million population in Europe are affected by end-stage renal disease and live on chronic renal replacement therapy. Approximately 80% of these patients are treated chronically by hemodialysis. The total number of patients on dialysis in Europe is above 500,000, with an annual increase of 7%. Despite major advances in the treatment of hemodialysis patients, over the past three decades the Achilles' heel of this therapy is creation of the vascular access, which is often followed by significant complications, both during creation and use. Such complications in these patients are among the main causes of morbidity and hospitalization. Therefore, prevention of arteriovenous fistula dysfunction remains an open clinical challenge, with more than 90,000 annual review procedures or reoperations in Europe [1, 2].

Early arteriovenous fistula dysfunction is defined as a fistula that has never been adequately developed for use or which has thrombosed in the first three months of use [3]. Remuzzi et al. [4] have pointed out that the mean annual survival of arteriovenous fistula is 70%

(42–90%), and that the primary patency for a period of two years is less than 50%. As the main reason for the dysfunction of arteriovenous fistula is inadequate venous dilation, hemodynamically significant obstruction of the venous conduit or perianastomotic segment, as a consequence of neointimal hyperplasia [5]. Due to the extremely high rates of morbidity in these patients, it is necessary to establish the fundamental pathogenesis of intimal hyperplasia due to possible therapeutic strategies which would prevent this process. All this is associated with a significant financial cost. The cost for the treatment of patients with the end stage kidney disease amounted to \$ 24 billion in 2007 in the United States, and for creating vascular access and for resolving complications it amounts to about 1.8 billion dollars a year [6].

Twenty five to 30 years ago, only 10% of new fistulas could not be used, but subsequently this increased to 20–50%. About 28–53% of arteriovenous fistulas for hemodialysis do not achieve proper maturation, despite a waiting period of six months or more. In such cases, further therapeutic procedures involve the use of catheters or arteriovenous grafts, which raises treatment costs and significantly increases the risk of morbidity and mortality [7].

**Received • Примљено:**

April 13, 2018

**Revised • Ревизија:**

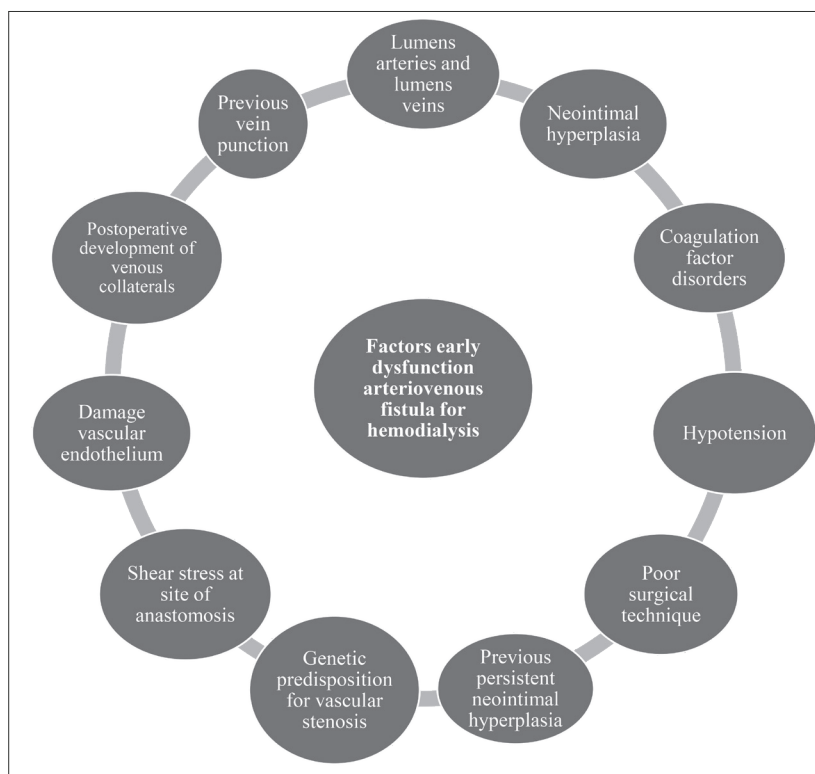
February 12, 2019

**Accepted • Прихваћено:**

February 13, 2019

**Online first:** March 18, 2019**Correspondence to:**

Radojica STOLIĆ  
Faculty of Medicine  
Svetozara Markovića 69  
34000 Kragujevac  
[radojica.stolic@med.pr.ac.rs](mailto:radojica.stolic@med.pr.ac.rs)



**Figure 1.** Parameters affecting early dysfunction of arteriovenous fistula for hemodialysis

## FACTORS OF ARTERIOVENOUS FISTULA DYSFUNCTION

Numerous studies have given defined reasons important for the initial dysfunction of an arteriovenous fistula (Figure 1). These include small lumens of the arteries and veins used for anastomosis, damage to the vascular endothelium during fistula creation, previous venipuncture, postoperative development of venous collaterals, the impact force of friction on the arteriovenous anastomosis, a genetic predisposition for development of vascular stenosis, neointimal hyperplasia and previously persistent venous neointimal hyperplasia [8]. Some clinical experience suggests that hypotension, coagulation factor disorders and poor surgical technique may affect the initial function of an arteriovenous fistula [9, 10].

## A NEW INSIGHT INTO FACTORS ASSOCIATED WITH VENOUS NEOINTIMAL HYPERPLASIA

Patients with chronic kidney disease are characterized by elevated levels of markers of oxidative stress, which implies the occurrence of endothelial dysfunction and vascular morbidity. Hemodynamic forces of friction and damaging therapeutic angioplasty procedures have led to increased synthesis of free radicals and certain bioactive substances, as well as powerful regulators of the key enzyme, matrix metalloproteinase. This degrades the extracellular matrix, facilitating migration of smooth muscle cells in the formation of neointimal hyperplasia [8]. In

clinical studies on arteriovenous fistulas with stenosis and thrombosis of the venous conduit, elevated levels of myeloperoxidase were found in the region of intimal hyperplastic stenosis of the fistula [11]. Recent investigations have shown that increased levels of C-reactive protein, high reactivity of interleukin-6 and tumor necrosis factor alpha, and inflammatory cells (macrophages and lymphocytes) may have a possible connection with the extent of neointimal hyperplasia in patients with arteriovenous fistula dysfunction. Also, it has been determined that endothelial function deteriorates in uremic syndrome, a state of permanent inflammation and oxidative stress. In this regard, the concentration of asymmetric dimethylarginine, an important parameter of endothelial dysfunction, was two to six times higher in patients with end stage kidney disease when compared to the general population [8]. All these stenosis-initiating factors result in activation of smooth-muscle cells and fibroblasts in the media, as well

as adventitia, with migration and proliferation in the intima. This excess of extracellular matrix causes expansion of intimal hyperplasia, which contributes to the formation of stenosis that almost always leads to vascular access thrombosis [12] (Table 1).

**Table 1.** Smooth muscle cell activation parameters

Development of venous neointimal hyperplasia
Free radicals
Matrix metalloproteinase
Myeloperoxidase
C-reactive protein
Interleukin-6
Tumor necrosis factor alpha
Inflammatory cells (macrophages, lymphocytes)
Asymmetric dimethylarginine

## NEOINTIMAL HYPERPLASIA FORMATION MECHANISM AND PATHOGENESIS

Any damage to the endothelium stimulates neointimal hyperplasia. During surgery to create a fistula, endothelial cells separate, edema occurs, fibrin is deposited and leukocytes and platelets infiltrate at the peeled intima surface. Endothelial cells produce paracrine factors that inhibit the proliferation of smooth muscle cells. Spotted edema and necrosis of smooth muscle cells are seen in the media. After two weeks, the endothelium covers a thickened intima, and the vein suffers arterialization. It becomes rigid, inflexible, with a damaged endothelium, containing less

endothelial relaxing factor and less fibrinolytic activity in the wall, and consequently blood flow is lower. Conditions that contribute to the formation of intimal hyperplasia are repeated puncture of the vein. The most common place to find neointimal hyperplasia is an arteriovenous anastomosis, due to the turbulent blood flow and increased mechanical stress [13].

Current understanding about the pathogenesis of venous neointimal hyperplasia of arteriovenous fistulas, distinguishes the pathophysiological mechanisms as upstream and downstream events. The proximal events characterize initial changes that are responsible for damage to the endothelium, promoting a cascade of different mediators in the distal parts, regulating oxidative stress, endothelial dysfunction and inflammation. These processes are related to:

- surgical trauma during creation of the arteriovenous fistula
- hemodynamically caused mechanical friction forces in the anastomotic region
- bioincompatibility of materials (for arteriovenous grafts)
- damage to the vascular wall (dialysis needle puncture)
- uremic environment, per se, leads to endothelial dysfunction
- repeated angioplasty procedures can cause additional damage to the endothelium [14].

Intimal hyperplasia is a product of the pathogenesis of juxta-anastomotic stenosis of the arteriovenous fistula, which in experimental models, occurs in about three weeks, while in clinical studies it develops between two and six months afterwards [15]. However, some findings indicate that intimal hyperplasia can occur much earlier [16].

Stenosis of a radio-cephalic fistula is most common in the peri-anastomotic area. Stenosis in a brachial-cephalic fistula often occurs in the first part of the juxta-anastomotic region. Lack of dilatation in the distal or proximal vein segment, may have a significant role in the size of the stenosis, particularly in the context of arteriovenous fistula non-maturation. When there is no adequate dilatation a small amount of venous neointimal hyperplasia can cause stenosis [4].

It is interesting that a large number of non-physiological factors may be responsible for initiating and supporting neointimal hyperplasia. It has been established that a sharp anastomosis angle (30°) generates better results and the appearance of less intimal hyperplasia. Not only is frictional force associated with promoting intimal hyperplasia, but also other factors identified in epidemiological studies, such as diabetes mellitus, race, age, peripheral vascular disease and female sex. Cardiovascular disease is also a risk factor for arteriovenous fistula non-maturation [4].

Precursors of myofibroblasts in adventitia of the vein record a sudden mechanical force due to the increase of vascular resistance resulting from arterial flow during the period of rapid adaptation. Other large investigations focused on the effect of surgical trauma and its possible influence on the development of neointimal hyperplasia [17].

## HEMODYNAMIC FACTORS AND VASCULAR PATHOLOGY IN ARTERIOVENOUS FISTULAS FUNCTIONING

The vascular endothelium is a dynamic cell medium that is interposed between the wall and the lumen of the blood vessel, and its main functions are maintaining vascular tone and blood flow, preventing vascular inflammation and proliferation of vascular smooth muscle cells, acting fibrinolytic, anti-atherogenic, anti-inflammatory, anticoagulant, and antiplatelet [17, 18]. After creating an arteriovenous fistula, a rapid increase in blood flow occurs as a result of passive vascular distension under the influence of nitric oxide synthase from endothelial cells and consecutive vascular relaxation of smooth-muscle cells with acute vasodilation. These changes simultaneously trigger structural remodeling of blood vessels, causing not only an increase in arterial and venous lumens, but also thickening of the vein wall. The adaptive response to raised blood flow involves increasing blood vessel lumens, in order to reduce the influence of friction to the level before fistula creation [19].

The altered hemodynamic conditions caused by an arteriovenous anastomosis utilize vascular remodeling mechanisms that contribute to the development of endothelial dysfunction. Together with increased oxidative stress, this is an important promoter of inflammation. Endothelial vasodilator activity (nitrous oxide, prostacyclin, bradykinin) is significantly reduced, while synthesis of powerful vasoconstrictors (endothelin, ACE III, free oxygen radicals) increases markedly [18–21].

Vascular calcifications in patients with chronic kidney disease, are a potential cause of vascular pathology. While calcification of the tunica intima classically associates with atherosclerosis, calcification of the tunica media occurs independently of atherosclerotic plaques and may be registered in arteries of any size. Turbulent flow through an arteriovenous fistula stimulates endothelial hyperplasia and encourages the migration and proliferation of vascular smooth muscle cells. Creation of an arteriovenous anastomosis circumvents peripheral resistance and blood flow is significantly increased, which initiates the process of vascular adaptation. On the other hand, non-uniform geometry caused by blood vessel anastomosis quickly changes the direction and strength of the blood stream. In a latero-terminal anastomosis, blood flow is directed from the artery into the vein, with retrograde flow in the distal part of the arterial conduit. In end-to-end anastomosis, the direction of blood flow from the artery into the vein is in the form of the letter “U”, which wastes energy through the entire scope of the anastomotic region. Turbulent blood flow in such conditions may, in the vicinity of the anastomosis, create conditions for neointimal hyperplasia [22].

## BLOOD FLOW ADAPTATION AFTER ARTERIOVENOUS ANASTOMOSES CREATION

In the first week, after the formation of arteriovenous fistula, comes to an increase in blood flow, an average of

539 ml/min, and almost triple increase in hemodynamical-ly-induced wall shear stress, which results in a progressive enlargement of the lumen of the vein from 2.4 mm preoperatively, to 6.6 mm 12 weeks after the creation of arteriovenous anastomoses [21]. However, since the shear stress is inversely proportional to the size of the lumen, shear stress returns after 12 weeks in the physiological range [4].

### **CURRENT THERAPEUTIC PROCEDURES TO IMPROVE THE FUNCTIONALITY OF VASCULAR ACCESS**

Notwithstanding considerable knowledge about the pathogenesis of venous neointimal hyperplasia, there are currently no prophylactic treatments that would reduce progression of neointimal hyperplasia. So far only a few different and partly effective therapeutic interventions of vascular access stenosis treatments are known, largely because of a lack of understanding of the cellular and molecular mechanisms that lead to the development of neointimal hyperplasia. Treatment of vascular access dysfunction requires a combined surgical, conservative and radiological approach. The first applied therapy was percutaneous transluminal angioplasty, as the best and simplest form of treatment for stenosis. It gives beneficial results for small, calcified arteries with functionalities of 65–96% over a period of one year. Percutaneous access to a thrombosed fistula is increasingly used as an alternative to surgical methods, while a combination of intraoperative surgical thrombectomy and balloon dilatation has recently been introduced. Surgical thrombectomy was initially the main way of treating fistula thrombosis within 24–72 hours of its occurrence and it involves use of the Fogarty catheter [23].

New alternatives in the treatment of vascular access thrombosis is so-called hydrodynamic thrombectomy, and pulse-spray thrombolysis. Thrombolytic therapy by urokinase injection is modified by placing two special catheters with multiple, side openings oriented in opposite directions in the thrombus. Urokinase is applied by pulse spray thrombolysis pharmaco-mechanically in a dose of 250,000–500,000 IU in short pulses, with active withdrawal of the catheter, back and forth [23].

Anticoagulant therapy can be used in patients with recurrent episodes of fistula thrombosis, but always after removal of the anatomical cause of thrombosis. Aspirin (acetylsalicylic acid) may be used as the sole therapy, or in combination with dipyridamole. In therapeutic doses sulfapyrazone can inhibit the proliferation of endothelial smooth muscle cells. Ticlopidine has been used as an inhibitor of platelet aggregation. There are some indications that statins and Omega-3 fatty acids may have some effect in preventing restenosis but their mechanisms of action are not sufficiently understood and there is no confirmation of the treatment results in wider studies [23, 24].

Certain observations suggest that anticoagulation protocols could be the correct strategy for inhibition of intimal hyperplasia, but finding a balance between acute thrombosis and bleeding is essential. In an experimental (murine) model of arteriovenous fistula the bleeding

incidence was 69%, when acetylsalicylic acid was given. Alternative single use of heparin is an efficient method to prevent acute thrombosis, which occurred in a murine model in 3% of cases and bleeding in 7% of cases. However, randomized studies in humans have not confirmed a significant impact of anticoagulant therapy on arteriovenous fistula maturation, although the incidence of early fistula thrombosis decreased in patients treated with clopidogrel. This significantly lowered the incidence of arteriovenous fistulas thrombosis over a period of six weeks, without reducing the time of maturation of four to five months [25].

There is some experience regarding the impact of ACE inhibitors on the incidence of intimal hyperplasia in patients with cardiovascular pathology [26]. Research on hemodialysis patients suggests that inhibiting the enzyme ACE may block proliferation of smooth-muscle cells as an important factor in the prevention of vascular access stenosis [27].

### **LOCAL THERAPEUTIC TREATMENT OF VASCULAR ACCESS STENOSIS**

Vascular accesses are ideal for the clinical application of perivascular therapy because they can be easily applied during surgery and primarily focus on “active” adventitia. When perivascular therapy is applied over the adventitia, lipophilic molecules can quickly diffuse through all layers of the vessel wall. Local therapeutic therapy of vascular access stenosis involves coating with the perivascular drug (paclitaxel), application of gel foam on endothelial cells, gene therapy with vascular endothelial growth factor, recombinant elastase PRT-201 and an Advanta catheter. Since almost all of these therapeutic procedures have been performed in animal models, or under experimental conditions, launching a research initiative (from animals to man) could lead to advances in understanding the mechanisms of neointimal hyperplasia formation and vascular stenosis, which may facilitate the development of new systemic and local therapies [8].

Systematic administration of pharmacological agents requires achievement of high drug levels in blood, in order to ensure a sufficient anti-proliferative effect on the target site. However, large randomized clinical trials are needed to assess the clinical effectiveness of these interventions in preventing thrombosis of the vascular access [15].

### **INNOVATIVE METHODS OF NEOINTIMAL HYPERPLASIA SUPPRESSION**

Modern strategy of vascular access dysfunction treatment involves timely identification of equivalent quantum neointimal hyperplasia. Some studies in animal models with cardiovascular changes examined balloon dilatation together with the application of endovascular radiation and found decreases in both neointimal hyperplasia and restenosis, after angioplasty. Newly formed blood vessels are especially sensitive to the effects of radiation. Recently published results of intra-coronary gamma radiation in

stent restenosis, showed positive findings in 42% of cases. Similar results were obtained after applying beta radiation. Gene therapy could become an effective way of locally treating neointimal hyperplasia. The most important advancement in the treatment of venous neointimal hyperplasia is a stent coated with a polymer comprising an anti-proliferative agent. Using sirolimus European multicenter studies in patients with coronary angioplasty have found almost complete absence of stent restenosis. Nevertheless, it is unknown whether the use of stents coated with anti-proliferative agents will be an efficient method for regulation of vascular access dysfunction [28].

The protocol and strategy of therapeutic procedures consists of suppressing conditions, which allow proliferation of smooth muscle cells. It was found a significant anti-proliferative effect of the methotrexate paclitaxel and sirolimus on development of venous neointimal proliferation [28, 29]. There are initial positive results in the application of infrared radiation for inhibition of intimal hyperplasia [30, 31]. There is an ongoing study that assess the impact of a sustainable strategy of adenovirus, as a mediator in the expression of  $\beta$ -adrenergic receptor kinase C [32].

Likewise, endovascular interventional techniques [8, 33] have proved successful in the treatment of stenotic lesions. There is significant success on the treatment of focal stenosis, which promotes use of percutaneous transluminal angioplasty, also called "cold embolization" [34, 35].

PRT-201 is a recombinant type I of pancreatic elastase, which in animal models, as a fragment of elastin in the blood vessels, results in permanent lumen vasodilation, but today we know that treatment with PRT-201 is not directed to treatment neointimal hyperplasia but to better help inflow dilatation of the artery [36].

The results of certain studies have found that vitamin D exerts a protective effect on the incidence of vascular calcification. Therefore, it could be concluded that percutaneous transluminal angioplasty balloon, coated with antiproliferative receptor for vitamin D, may inhibit the growth of smooth-muscle cells [37].

Nitinol U-clip (Medtronic Minneapolis, MN, USA) is designed to reduce the use of stitches, which would avoid tying knots and facilitate the creation of a circular anastomosis. Nitinol is used in the so-called U-clip, shaped like memory alloys, made of nickel and titanium. It is believed that the inert properties of the material, in combination with reduced surgical trauma, reduce the migration of activated smooth-muscle cells and depositing them in a layer of neointimal hyperplasia. Single suture technique, when creating anastomosis, reduces turbulent flow and intimal hyperplasia, and, in relation to the extension seam, allows dilatation of anastomosis in the radial direction with each systole. However, despite the obvious advantages, it has not been accepted by most vascular surgeons due to ad-

ditional time required for tying knots and certain technical problems [38].

A recent bioengineering research of human acellular vessels for vascular access for hemodialysis show that it could be "the light at the end of the tunnel." In fact, the study Lawson et al. [39] opens the door to a new way of thinking (on several fronts) in the context of bioengineering blood vessels. As with all new technologies, there must be caution, as long as data is not available through non-randomized clinical trials that are in progress [39, 40].

## CONCLUSION

Arteriovenous fistula dysfunction is defined as a fistula that has never been adequately developed for use or which has thrombosed in the first three months of use.

Any damage to the endothelium stimulates neointimal hyperplasia. Conditions that contribute to the formation of intimal hyperplasia are repeated puncture of the vein, caused by trauma, wall hypoxia and unnatural hemodynamic conditions. The most common place for neointimal hyperplasia is an arteriovenous anastomosis.

Treatment of vascular access dysfunction requires a combined surgical, conservative and radiological approach.

New alternatives in the treatment of vascular access thrombosis is hydrodynamic thrombectomy, and pulse-spray thrombolysis.

Local therapeutic therapy of vascular access stenosis involves gene therapy with vascular endothelial growth factor, recombinant elastase PRT-201 and an Adventa catheter.

Gamma and beta radiation showed positive findings, along with gene therapy could become an effective way of locally treating neointimal hyperplasia. The most important advancement in the treatment of venous neointimal hyperplasia is a stent coated with a polymer comprising an anti-proliferative agent. Positive effects were also identified using Nitinol U-clip, as well as using vitamin D.

## ACKNOWLEDGMENTS

The authors disclosed receipt of the following financial support for the research, authorship, and/or publication of this article: this research is partly supported by the Ministry of Education and Science of the Republic of Serbia, Grants III41010.

The sponsor had no role in the study design or interpretation of results.

**Conflict of interest:** None declared.

## REFERENCES

- Caroli A, Manini S, Antiga L, Passera K, Ene-Iordache B, Rota S, et al. ARCH project Consortium: Validation of a patient-specific hemodynamic computational model for surgical planning of vascular access in hemodialysis patients. *Kidney Int.* 2013; 84(6):1237–45.
- Aitken E, Jackson A, Kong C, Coats P, Kingsmore D. Renal function, uremia and early arteriovenous fistula failure. *BMC Nephrol.* 2014; 15:179.
- Roy-Chaudhury P, Arend L, Zhang J, Krishnamoorthy M, Wang Y, Banerjee R, et al. Neointimal hyperplasia in early arteriovenous fistula failure. *Am J Kidney Dis.* 2007; 50(5): 782–90.
- Remuzzi A, Ene-Iordache B. Novel paradigms for dialysis vascular access: upstream hemodynamics and vascular remodeling in dialysis access stenosis. *Clin J Am Soc Nephrol.* 2013; 8(12):2186–93.
- Monroy MA, Fang J, Li S, Ferrer L, Birkenbach MP, Lee IJ, et al. Chronic kidney disease alters vascular smooth muscle cell phenotype. *Front Biosci (Landmark Ed).* 2015; 20:784–95.
- Bonatti J, Oberhuber A, Schachner T, Zou Y, Hammerer-Lercher A, Mittermair R, et al. Neointimal hyperplasia in coronary vein grafts: pathophysiology and prevention of a significant clinical problem. *The Heart Surgery Forum.* 2004; 7(1):72–87.
- Allon M, Litovsky S, Young CJ, Deierhoi MH, Goodman J, Hanaway M, et al. Medial fibrosis, vascular calcification, intimal hyperplasia, and arteriovenous fistula maturation. *Am J Kidney Dis.* 2011; 58(3):437–43.
- Timmy Lee, Prabir Roy-Chaudhury. *Advances and New Frontiers in the Pathophysiology of Venous Neointimal Hyperplasia and Dialysis Access Stenosis.* *Adv Chronic Kidney Dis.* 2009; 16(5):329–38.
- Stolic R. Most important chronic complications of arteriovenous fistulas for hemodialysis. *Med Princ Pract.* 2013; 22(3):220–8.
- Stolic R, Trajkovic Z, Peric V, Jovanovic A, Markovic S, Sovtic S, et al. The influence of atherosclerosis and plasma D-dimer concentration in patients with a functioning arteriovenous fistula for maintenance hemodialysis. *Int Urol Nephrol.* 2008; 40(2):503–8.
- Stolic RV, Trajkovic GZ, Kostic M, Stolic DZ, Miric DJ, Kistic BM, et al. Predictive value of serum myeloperoxidase activity for thrombosis of arteriovenous fistulas. *Hemodial Int.* 2014; 18(3):680–5.
- Budu-Grajdeanu P, Schugart RC, Friedman A, Valentine C, Agarwal AK, Rovin BH. A mathematical model of venous neointimal hyperplasia formation. *Theor Biol Med Model.* 2008; 23: 5:2.
- Kokubo T, Kchida H, Choi ET. Integrin  $\alpha\beta_3$  as a target in the prevention of neointimal hyperplasia. *J Vasc Surg.* 2007; 45(6S):33–8.
- Remuzzi A, Ene-Iordache B. Novel paradigms for dialysis vascular access: upstream hemodynamics and vascular remodeling in dialysis access stenosis. *Clin J Am Soc Nephrol.* 2013; 8(12):2186–93.
- Allon M. Novel Paradigms for Dialysis Vascular Access: Introduction. *CJASN.* 2013; 8(12):2183–5.
- Stolic R, Mitrovic S, Stolic D, Mitic N. Early pathohistological changes in dysfunction of arteriovenous fistula for hemodialysis; *Vojnosanit Pregl.* 2010; 67(1):65–8. (Serbian)
- Brahmbhatt A, Nieves-Torres E, Yang B, Edwards WD, Roy Chaudhury P, Lee MK, et al. The role of I $\kappa$ B-1 in the pathogenesis of venous neointimal hyperplasia associated with hemodialysis arteriovenous fistula. *PLoS One.* 2014; 9(7):e102542.
- Stolic R, Grbic R, Odalovic D, Smilic L. Hemodynamic changes conditioned by arteriovenous fistulas for hemodialysis. *Ital J Vasc Endovasc.* 2015; 22(3):153–8.
- Widlansky M, Gokce N, Keaney J, Vita J. The clinical implications of endothelial function. *JACC.* 2003; 42:1149–60.
- Ruhul A, Kiichiro Y, Shaodong G, Virendra IP, Gautam S, Katherine CS, et al. Forkhead transcription factors inhibit vascular smooth muscle cell proliferation and neointimal hyperplasia. *J Biol Chem.* 2005; 280(33):864–73.
- Girerd X, London G, Boutouyrie P, Mourad JJ, Safar M, Laurent S. Remodeling of the radial artery in response to a chronic increase in shear stress. *Hypertension.* 1996; 27(3 Pt 2):799–803.
- Chamberlain J, Evans D, King A, Dewberry R, Dower S, Crossman D, et al. Interleukin-1 $\beta$  and signaling of interleukin-1 in vascular wall and circulating cells modulates the extent of neointima formation in mice. *Am J Pathol.* 2006; 168(4):1396–403.
- Konner K, Nonnast-Daniel B, Ritz E. Disease of the month The Arteriovenous Fistula. *J Am Soc Nephrol.* 2003; 14:1669–80.
- Koner K. The anastomosis of the arteriovenous fistula—common errors and their avoidance. *Nephrol Dial Transplant.* 2002; 17(3):376–9.
- Wong CY, de Vries MR, Wang Y, van der Vorst JR, Vahrmeijer AL, van Zonneveld AJ, et al. Vascular remodeling and intimal hyperplasia in a novel murine model of arteriovenous fistula failure. *J Vasc Surg.* 2014; 59(1):192–201.
- Osgood MJ, Harrison DG, Sexton KW, Hocking KM, Voskresensky IV, et al. Role of the Renin–Angiotensin System in the Pathogenesis of Intimal Hyperplasia: Therapeutic Potential for Prevention of Vein Graft Failure? *Ann Vasc Surg.* 2012; 26(8):1130–44.
- Sajgure A, Choudhury A, Ahmed Z, Choudhury D. Angiotensin converting enzyme inhibitors maintain polytetrafluoroethylene graft patency. *Nephrol Dial Transplant.* 2007; 22:1390–8.
- Rotmans JI, Pattinama PM, Verhagen HJ, Hino I, Velema E, Pasterkamp G, et al. Sirolimus-eluting stents to abolish intimal hyperplasia and improve flow in porcine arteriovenous grafts: a 4-week followup study. *Circulation.* 2005; 111(12):153715–42.
- Chih-Ching L, Chao-Fu C, Ming-Yu L, Tzen-Wen C, Pui-Ching L, Wu-Chang Y. Far-Infrared therapy: A novel treatment to improve access blood flow and unassisted patency of arteriovenous fistula in hemodialysis patients. *J Am Soc Nephrol.* 2007; 18(3):985–92.
- Luo Z, Akita GY, Date T, Treleaven C, Vincent KA, Woodcock D, et al. Adenovirus-mediated expression of  $\beta$ -adrenergic receptor kinase C-terminus reduces intimal hyperplasia and luminal stenosis of arteriovenous polytetrafluoroethylene grafts in pigs. *Circulation.* 2005; 111(13):1679–84.
- Roy-Chaudhury P, Melhem M, Husted T, Kelly BS. Solutions for hemodialysis vascular access dysfunction: thinking out of the box!! *J Vasc Access.* 2005; 6(1):3–8.
- Roy-Chaudhury P, Sukhatme VP, Cheung AK. Hemodialysis vascular access dysfunction: a cellular and molecular viewpoint. *J Am Soc Nephrol.* 2006; 17(4):1112–27.
- Clark TW, Cohen RA, Kwak A, Markmann JF, Stavropoulos SW, Patel AA, et al. Salvage of nonmaturing native fistulas by using angioplasty. *Radiology.* 2007; 242(1):286–92.
- Shin SW, Do YS, Choo SW, Lieu WC, Choo IW. Salvage of immature arteriovenous fistulas with percutaneous transluminal angioplasty. *Cardiovasc Intervent Radiol.* 2005; 28(4):434–8.
- Turmel-Rodrigues L, Boutin JM, Camiade C, Brillet G, Fodil-Chérif M, Mouton A. Percutaneous dilation of the radial artery in nonmaturing autogenous radial-cephalic fistulas for hemodialysis. *Nephrol Dial Transplant.* 2009; 24(12):3782–8.
- Dwivedi AJ, Roy-Chaudhury P, Peden EK, Browne BJ, Ladenheim ED, Scavo VA, et al. Application of human type I pancreatic elastase (PRT-201) to the venous anastomosis of arteriovenous grafts in patients with chronic kidney disease. *J Vasc Access.* 2014; 15(5):376–84.
- MacAskill MG, Watson DG, Ewart MA, Wadsworth R, Jackson A, Aitken E, et al. Improving arteriovenous fistula patency: Transdermal delivery of diclofenac reduces cannulation-dependent neointimal hyperplasia via AMPK activation. *Vascul Pharmacol.* 2015; 71:108–15.
- Varcoe RL, Teo AB, Pelletier MH, Yu Y, Yang JL, Crowe PJ, et al. An arteriovenous fistula model of intimal hyperplasia for evaluation of a nitinol U-Clip anastomosis. *Eur J Vasc Endovasc.* 2012; 43(2):224–31.
- Lawson JH, Glickman MH, Ilzecki M, Jakimowicz T, Jaroszynski A, Peden EK, et al. Bioengineered human acellular vessels for dialysis access in patients with end-stage renal disease: two phase 2 single-arm trials. *The Lancet.* 2016; 387(10032):2026–34.
- Roy-Chaudhury P. Bioengineered vessels for dialysis access: soon to be a reality? *Nat Rev Nephrol.* 2016; 12(9):516–7.

## Дисфункција артериовенске фистуле за хемодијализу као последица венске неоинтималне хиперплазије и стратегија лечења

Радојица Столић

Универзитет у Крагујевцу, Факултет медицинских наука, Катедра интерне медицине, Крагујевац, Србија

### САЖЕТАК

Један од главних проблема везаних за планирање васкуларног приступа је дисфункција током сазревања. Дисфункција артериовенске фистуле најчешће је последица неоинтималне хиперплазије. Важни разлози иницијалне дисфункције артериовенске фистуле укључују мање лумене артерија и вена које се користе за анастомозу, оштећење васкуларног ендотела током креирања фистуле, претходне венепункције, постоперативни развој венских колатерала, силу трења која настаје након креирања артериовенске анастомозе, генетску предиспозицију за развој васкуларне стенозе, неоинтималну хиперплазију, као и претходно већ постојећу венску неоинтималну хиперплазију.

Свако оштећење ендотела је стимуланс за неоинтималну хиперплазију. Током операције креирања фистуле настају едем ендотелних ћелија, депоновање фибрина и инфилтра-

ција леукоцита и тромбоцита. Појављују се едем и некроза глатких мишићних ћелија у медији.

Да би се одредила адекватна терапеутска стратегија, патогенеза неоинтималне хиперплазије је свеобухватно разматрана, са различитих аспеката. Терапија се тренутно заснива на преоперативном чувању вена и пажљивој селекцији крвних судова, перкутаној транслуминалној ангиопластици или хируршкој ревизији. Ипак, постојеће терапеутске стратегије не пружају одговарајућа решења за побољшање матурације артериовенске фистуле. Упркос значајним сазнањима о патогенези венске неоинтималне хиперплазије, тренутно не постоје профилактички третмани који би смањили његову прогресију.

**Кључне речи:** хемодијализа; артериовенска фистула; дисфункција; патогенеза; венска неоинтимална хиперплазија; терапеутска стратегија