



## CASE REPORT / ПРИКАЗ БОЛЕСНИКА

# Clinical applications of BioAggregate in pediatric dentistry – case reports

Secil Caliskan, Nuray Tuloglu, Sule Bayrak

University of Eskisehir Osmangazi, Faculty of Dentistry, Department of Pediatric Dentistry, Eskisehir, Turkey

## SUMMARY

**Introduction** Calcium-silicate-based, nanoparticle-sized BioAggregate is produced as an alternative version of mineral trioxide aggregate (MTA). It contains additives such as calcium phosphate and silicon dioxide but does not contain aluminium oxide and bismuth oxide. Studies have shown that BioAggregate's calcium-ion release is better than these qualities in MTA concerning fracture and acid resistance, biocompatibility and sealing ability.

**Case outline** In this paper, we examine eight case reports. These reports describe the long-term results of using BioAggregate in areas such as pulpotomy and root canal treatment in primary and permanent teeth, partial pulpotomy, artificial apical barrier construction of permanent teeth, root resorption repair, and treatment of *dens in dente*.

**Conclusion** As evidenced by the case reports examined here, BioAggregate can be used as alternative material to MTA in many dental treatments. These reports also show that the biocompatibility, antibacterial properties, hardening when moisture is present, ideal expansion percentage, impermeability, and dentine adhesion features of BioAggregate provide advantages in clinical use.

**Keywords:** pulpotomy; root canal treatment; nanoparticle-sized BioAggregate; calcium silicate

## INTRODUCTION

Ceramics are some of the oldest synthetic materials based on natural resources. Bioceramics are specially designed ceramics used in medicine, including dentistry, to repair, restructure or replace damaged or injured body organs [1, 2]. Bioceramics consist of polycrystalline ceramics (alumina and hydroxyapatite), bioactive glass, bioactive glass ceramics, or bioactive composites (polyethylene-hydroxyapatite) [3].

Bioceramics have very attractive properties for medicine and dentistry. For dental practices, they have two important advantages. First, bioceramics are biocompatible, nontoxic, shrink-proof, and chemically stable in the biological environment. For example, bioceramics do not produce inflammatory tissue responses when extruded to periodontal tissues during the root repair process. This is due to the hydroxyapatite formed during the material's dentin bonding [4]. Second, they exhibit a strong antibacterial quality given their high pH (12.9) on curing.

Mineral trioxide aggregate (MTA) was the first bioceramic material successfully used in dental endodontic practices [5]. Given its biocompatibility, superior physical and chemical properties, it has become the preferred material of choice in areas such as perforation repair, retrograde filling, vital pulp treatment, and root-canal treatment of teeth with an open apex [6]. On the other hand, MTA has limitations. These include its long setting time, manipulation difficulty, high cost and tooth discoloration. These deficiencies have prompted

the development of alternative materials for the uses described above.

Calcium-silicate-based, nanoparticle-sized BioAggregate (Innovative BioCeramix, Inc., Burnaby, Canada) is produced as an alternative version of MTA in Canada [7, 8]. It is like MTA in many respects. It contains additives such as calcium phosphate and silicon dioxide but does not contain aluminium oxide or bismuth oxide. In addition, studies have shown that its calcium-ion release, acid and fracture resistance, biocompatibility and sealing ability are better than for MTA [8–12].

Despite the positive *in vitro* results, the studies on the clinical use of BioAggregate are limited. Therefore, the aim of this paper is to show the clinical use of BioAggregate in different instances in pediatric dentistry.

## CASE REPORTS

The treatments described in the cases presented here were performed at the Faculty of Dentistry, Department of Pediatric Dentistry of the Eskisehir Osmangazi University in Turkey after written informed consent was obtained from the patients' parents. BioAggregate was used as a biomaterial in all of these cases.

### Case 1. Pulpotomy in primary teeth

A four-year-old girl who applied for a regular check-up at our clinic was found to have deep dentin caries in the mandibular left primary

Received • Примљено:  
May 9, 2019

Revised • Ревизија:  
September 10, 2019

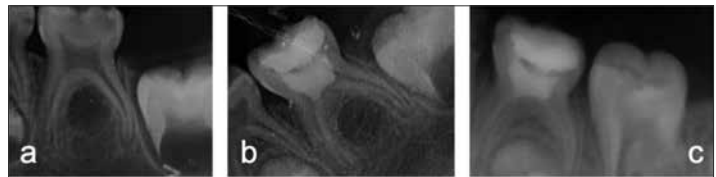
Accepted • Прихваћено:  
November 17, 2019

Online first: November 27, 2019

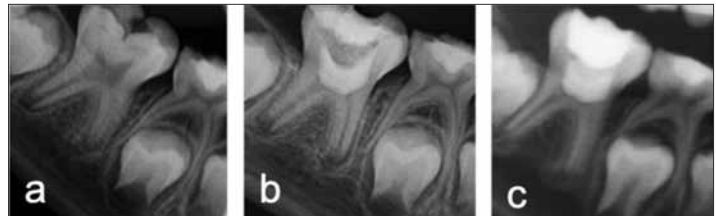
#### Correspondence to:

Nuray TULOGLU  
Department of Pediatric Dentistry,  
Faculty of Dentistry  
Eskisehir Osmangazi University  
26480 Eskisehir, Turkey  
[nuraytuloglu@yahoo.com](mailto:nuraytuloglu@yahoo.com)

second molar (Tooth 85) (Figure 1a). According to her parents, she had experienced no spontaneous tooth pain. The intraoral examination found no percussion/palpation sensitivity or mobility. The oral mucosa was normal. In addition, there was no pathology found in the tooth's periapical tissues. Nevertheless, the development of the mandibular left permanent second premolar (Tooth 45) follicle was found delayed. Due to the pulp exposure without caries during the cavity preparation and the possibility of not forming permanent premolar (Tooth 45), a pulpotomy was performed using BioAggregate (Figure 1b). During the 24-month follow-up, Tooth 85 was found to be clinically asymptomatic, and the radiographic examinations showed no periodontal/periapical pathology (Figure 1c).



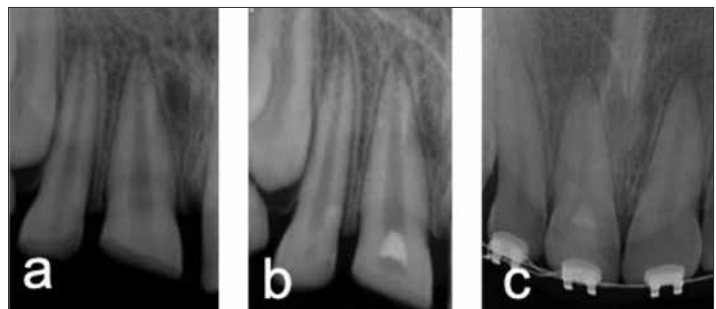
**Figure 1.** Radiographic appearance of case 1; a – preoperative; b – postoperative; c – postoperative 24-month follow-up



**Figure 2.** Radiographic appearance of case 2; a – preoperative; b – postoperative; c – postoperative 12-month follow-up

### Case 2. Pulpotomy in permanent teeth

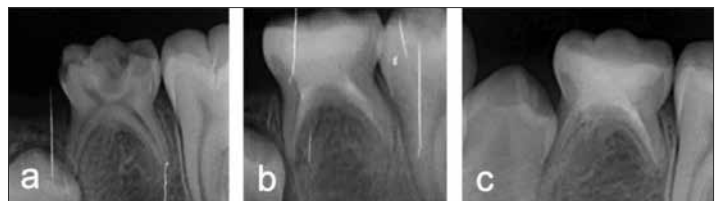An eight-year-old male patient was admitted to our clinic and it was determined to have deep dentin caries in the mandibular right permanent first molar (Tooth 46) (Figure 2a). There was no spontaneous pain, percussion/palpation sensitivity, or pathologic mobility. The oral mucosa was also normal. The radiographic examination revealed that the mandibular right first molar's root development was not complete and that there was no pathology in the periapical region. A pulpotomy procedure was performed with BioAggregate on the tooth, which had responded positively to the vitality test (Figure 2b). In the follow-up radiographic examination at 12 months, Tooth 46 was observed to be vital and showing evidence of continuing root development with no periodontal/periapical pathology (Figure 2c).



**Figure 3.** Radiographic appearance of case 3; a – preoperative; b – postoperative; c – postoperative six years follow-up

### Case 3. Partial pulpotomy

A 10-year-old girl was referred to our clinic with a complaint of a crown fracture that occurred when she fell at school. During the clinical examination, an enamel-dentin fracture with pulp exposure was observed in the maxillary right permanent central incisor (Tooth 11). Tooth 11 responded positively to the electric pulp test and exhibited sensitivity to cold and heat. Pathological mobility and percussion/palpation sensitivity were not observed. The radiographic examination found that Tooth 11 showed nearly complete apex formation and that there was no alveolar fracture or any other injury in the apical region (Figure 3a). A partial pulpotomy was performed using BioAggregate (Figure 3b). Throughout the six-year follow-up, Tooth 11 exhibited no clinical pathology or coronal discoloration, and the pulp was observed to be vital. The radiographic examinations showed a closed apex and a dent in bridge at the pulpotomy site (Figure 3c).



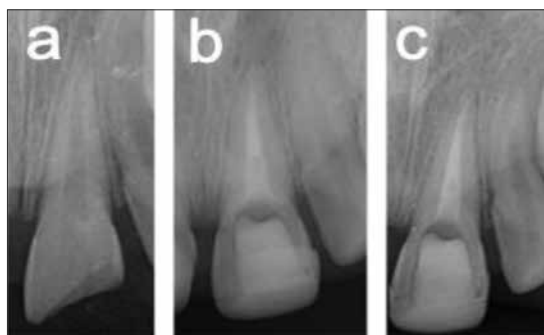**Figure 4.** Radiographic appearance of case 4; a – preoperative; b – postoperative; c – postoperative 24-month follow-up

### Case 4. Root canal treatment in primary tooth

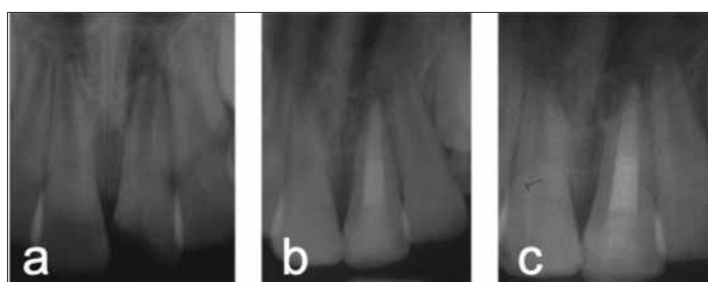
A nine-year-old male patient was admitted to our clinic with severe spontaneous pain in his mandibular left primary second molar (Tooth 75). The intraoral examination found increased percussion sensitivity and mobility. The oral mucosa was normal. The radiographic examination found that the periodontal space of the corresponding tooth was enlarged and that the permanent tooth was congenitally deficient (Figure 4a). A root canal treatment was performed on the devitalized tooth using BioAggregate (Figure 4b). During the 24-month follow-up, Tooth 75 was found to be clinically asymptomatic, and the radiographic examinations showed no periodontal/periapical pathology (Figure 4c).

### Case 5. Root canal treatment in permanent tooth

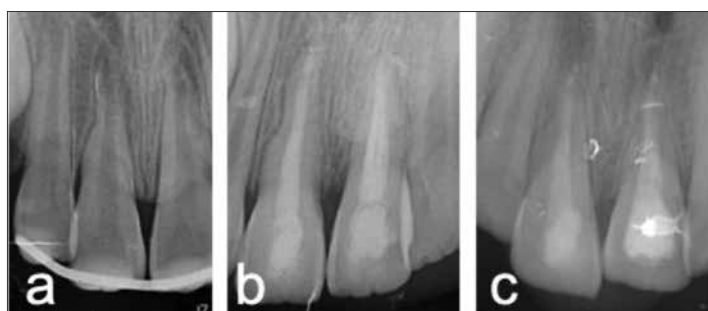
A 10-year-old female was referred to our clinic with complaints of tooth fracture and pain after falling from a bicycle.



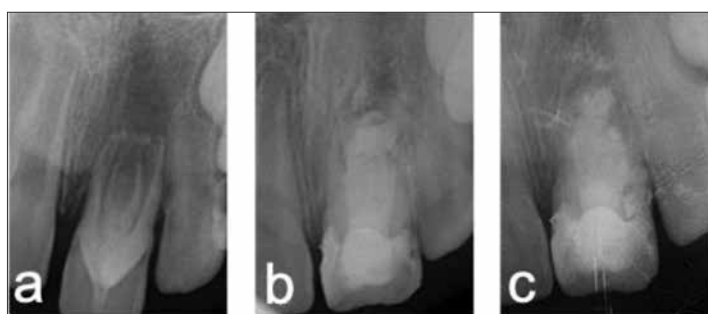
**Figure 5.** Radiographic appearance of case 5; a – preoperative; b – postoperative; c – postoperative 24-month follow-up



**Figure 6.** Radiographic appearance of case 6; a – preoperative; b – postoperative; c – postoperative 24-month follow-up



**Figure 7.** Radiographic appearance of case 7; a – preoperative; b – postoperative; c – postoperative 24-month follow-up



**Figure 8.** Radiographic appearance of case 8; a – preoperative; b – postoperative; c – postoperative 24-month follow-up

The intraoral examination found a complicated crown fracture of the maxillary right permanent central incisor (Tooth 11) that exhibited spontaneous pain, percussion/palpation sensitivity, and a negative vital response. The radiographic evaluation revealed an enlarged periodontal space and completed root development with a closed apex (Figure 5a). A root canal treatment was performed on the devitalized Tooth 11 using BioAggregate (Figure 5b).

Throughout the 24-month follow-up, Tooth 11 was found to be clinically asymptomatic and showed normal color. The radiographic examinations showed no periodontal/periapical pathology (Figure 5c).

### **Case 6. Artificial apical barrier construction in permanent teeth**

A 10-year-old male was admitted to our clinic with a complaint of a crown fracture caused by a fall. In the intake interview, it was learned that the patient was experiencing severe spontaneous pain in the maxillary left permanent central incisor (Tooth 21) that had started two days prior to the visit. The intraoral examination revealed a complicated crown fracture and increased percussion sensitivity in Tooth 21. The radiographic examination showed an enlarged periodontal space, a periapical lesion, and an incomplete root with immature apex (Figure 6a). A root canal treatment was performed to create an artificial apical barrier in Tooth 21 using BioAggregate (Figure 6b). Throughout the 24-month follow-up, the tooth showed no clinical pathology or coronal discoloration. The radiographic examinations showed no periodontal/periapical pathology (Figure 6c).

### **Case 7. Root resorption repair in permanent teeth**

An 11-year-old female was admitted to our clinic complaining of dental pain. In the patient's history, we learned that she was in a traffic accident two months prior to visit, and that a splint was performed at another health center because of the teeth mobility. The intraoral clinical examination found that the splint was still in her mouth and that a root canal treatment had been started in the maxillary permanent incisors (Teeth 11 and 21). Nevertheless, the exam found that the patient was still experiencing spontaneous dental pain and percussion sensitivity. The radiographic evaluation showed an enlarged periodontal space, external root resorption areas, and an immature apex (Figure 7a). A root canal treatment was performed using BioAggregate (Figure 7b). During the 24-month follow-up, Teeth 11 and 21 were found to be clinically asymptomatic and showed normal color. The radiographic evaluations revealed that the external root resorptions had been controlled and that no periodontal/periapical pathology had occurred (Figure 7c).

### **Case 8. Treatment of dens in dente**

A seven-year-old boy was referred to our clinic with a complaint of dental pain. The intake interview revealed that the severe dental pain had started two weeks

before the visit. The intraoral examination detected percussion/palpation sensitivity, pathologic mobility, swelling in the vestibular mucosa and a negative response to the electric pulp test in the left upper central incisor (Tooth 21). The radiographic evaluation revealed an open apex, extensive radiolucency of the periapical tissue and type 3 *dens in dente* (Figure 8a). A root canal treatment was performed using BioAggregate (Figure 8b). Throughout the 24-month follow-up, Tooth 21 was found to be clinically asymptomatic and showed normal color. The radiographic examinations showed no periodontal/periapical pathology (Figure 8c).

## DISCUSSION

The use of calcium-silicate-based bioceramics has been steadily increasing due to the negative clinical characteristics of the MTA that is used widely in biomimetic-based treatments. Bioceramics have found place as alternative materials in clinical use not only because of their ductal patency but also for they showed positive results in vital treatments such as pulpotomy and direct pulp capping, apical plugging and retrograde filling [4].

Among these materials, the calcium-silicate-based BioAggregate has specific advantages. First, it is preferred because of its strong physical properties and because it is highly biocompatible, nontoxic, shrink-proof and chemically stable within the biological environment. Second, when extruded to periodontal tissue, it does not cause inflammation, which is very important in endodontic applications [13]. It was also observed that bioceramics can be used as an alternative paste for root canal treatments of open apices or perforated teeth due to positive properties such as its biocompatibility, and its ability to increase cementoblastic and osteoblastic activity [14, 15, 16].

A further advantage of BioAggregate is that it creates a chemical bond between dentin and filler material by forming hydroxyapatite during the setting process. The resulting hydroxyapatite-like structure acts as a graft material that takes up bone. A significant component of BioAggregate's improving this adherence to the canal wall is its hydrophilic nature and low surface tension. These qualities ensure a high closure for the cover [17]. In addition, it has been shown that the presence or absence of a smear layer does not affect the adherence to the canal wall [18].

## REFERENCES

- Pasinli A. Biyomedikal Uygulamalarda Kullanılan Biyomalzemeler. Mak Tek Elek Derg. 2004; 1(4):25–34.
- Best SM, Porter AE, Thian ES, Huang J. Bioceramics: past, present and for the future. J Eur Ceram Soc. 2008; 28(7):1319–27.
- Hench LL. Bioceramics – from concept to clinic. J Am Ceram Soc. 1991; 74(7):1487–510.
- Koch K, Brave D. The increased use of bioceramics in endodontics. Dentaltown. 2009; 10:39–43.
- Jitaru S, Hodisan I, Timis L, Lucian A, Bud M. The use of bioceramics in endodontics-literature review. Clujul Med. 2016; 89(4):470–3.
- Cavda rTetik EA, Dartar Oztan M and Kiyan M. Comparison of in-vitro antimicrobial activities of bioaggregate and mineral trioxide aggregate. Mikrobiyol Bul. 2013; 47(3):523–8.
- Tuloglu N, Bayrak S. Comparative evaluation of mineral trioxide aggregate and bioaggregate as apical barrier material in traumatized nonvital, immature teeth: A clinical pilot study. Niger J Clin Pract. 2016; 19(1):52–7.
- Raghavendra SS, Jadhav GR, Gathani KM, Kotadia P. Bioceramics in endodontics – a review. J Istanbul Univ Fac Dent. 2017; 51(Suppl 1):128–37.

A significant portion of BioAggregate's composition is tantalum oxide, which is used instead of the bismuth oxide used in MTA for radiopacity [19]. BioAggregate has a 3.8 mm aluminium equivalent radiopacity, which is higher than MTA's radiopacity [17]. For this reason, it is considered an alternative material because of its advantages in the evaluation of restoration quality [20].

Bioceramic pastes such as BioAggregate exhibit biological activity that includes an alkaline pH (pH > 12), high calcium-ion release, and hydroxyapatite formation. In addition, BioAggregate's tantalum oxide content contributes to antimicrobial activity. Such activity helps prevent failures in pulpal and endodontic treatments in cases involving coronal and apical leakage of microorganisms [16].

In this manuscript, we have shown eight different uses of BioAggregate that achieved successful long-term outcomes. No apical pathology occurred because of these treatments. In addition, as reported in a study by Tuloglu et al. [21], no coronal discoloration was observed in these instances because BioAggregate, unlike MTA, does not contain metal oxides.

That being said, we note that traditional root canal disassembly techniques do not completely remove bioceramics from root canals and that this requires further dismantling of the canal filler. The need for this procedure and the additional time it requires are considered the greatest disadvantage of these materials [22]. We also note that there are limited clinical long-term studies on the performance of this newly developed repair material as an alternative to MTA. Such studies should be done to achieve a greater understanding of BioAggregate's properties and performance.

In conclusion, BioAggregate could be used as an alternative material in many clinical dental treatments. Its biocompatibility, antibacterial properties, hardening in the presence of moisture, ideal expansion percentage, impermeability and dentine adhesion features provide the described advantages in clinical uses.

## ACKNOWLEDGMENT

We thank dentists Huseyin Bicer, Tugce Kalicoglu, and Yagmur Kahraman for their contributions.

**Conflict of interest:** None declared.



9. Yan P, Yuan Z, Jiang H, Peng B, Bian Z. Effect of bioaggregate on differentiation of human periodontal ligament fibroblasts. *Int Endod J.* 2010; 43(12):1116–21.
10. Memiş Özgül B, Bezgin T, Şahin C, Sarı Ş. Resistance to leakage of various thicknesses of apical plugs of Bioaggregate using liquid filtration model. *Dent Traumatol.* 2015; 31(3):250–4.
11. Tuna EB, Dinçol ME, Gençay K, Aktören O. Fracture resistance of immature teeth filled with BioAggregate, mineral trioxide aggregate and calcium hydroxide. *Dent Traumatol.* 2011; 27(3):174–8.
12. Hashem AA, Wanees Amin SA. The effect of acidity on dislodgment resistance of mineral trioxide aggregate and bioaggregate in furcation perforations: an in-vitro comparative study. *J Endod.* 2012; 38(2):245–9.
13. Koch KA, Brave DG, Nasseh AA. Bioceramic technology: closing the endo-restorative circle, Part I. *Dent Today.* 2010; 29(2):100–5.
14. Chang SW, Lee SY, Kang SK, Kum KY, Kim EC. In-vitro biocompatibility, inflammatory response, and osteogenic potential of 4 root canal sealers: Sealapex, Sankin apatite root sealer, MTA Fillapex, and iRoot SP root canal sealer. *J Endod.* 2014; 40(10):1642–8.
15. Zhang W, Li Z, Peng B. Ex vivo cytotoxicity of a new calcium silicate-based canal filling material. *Int Endod J.* 2010; 43(9):769–74.
16. Loushine BA, Bryan TE, Looney SW, Gillen BM, Loushine RJ, Weller RN, et al. Setting properties and cytotoxicity evaluation of a premixed bioceramic root canal sealer. *J Endod.* 2011; 37(5):673–7.
17. Koch DK, Brave D, Nasseh AA. A review of bioceramic technology in endodontics. *Roots.* 2013; 1:6–13.
18. Bidar M, Sadeghalhoseini N, Forghani M, Attaran N. Effect of the smear layer on apical seals produced by two calcium silicate-based endodontic sealers. *J Oral Sci.* 2014; 56(3):215–9.
19. Park JW, Hong SH, Kim JH, Lee SJ, Shin SJ. X-Ray diffraction analysis of white ProRoot MTA and Diadent BioAggregate. *Oral Surg Oral Med Oral Pathol Oral Radiol Endod.* 2010; 109(1):155–8.
20. Candeiro GT, Correia FC, Duarte MA, Ribeiro-Siqueira DC, Gavini G. Evaluation of radiopacity, pH, release of calcium ions, and flow of a bioceramic root canal sealer. *J Endod.* 2012; 38(6):842–5.
21. Tuloglu N, Bayrak S. Partial pulpotomy with BioAggregate in complicated crown fractures: three case reports. *J Clin Pediatr Dent.* 2016; 40(1):31–5.
22. de Siqueira Zuolo A, Zuolo ML, da Silveira Bueno CE, Chu R, Cunha RS. Evaluation of the efficacy of TRUShape and Reciproc File systems in the removal of root filling material: an ex vivo micro-computed tomographic study. *J Endod.* 2016; 42(2):315–9.

## Примена клиничких биоагрегата у стоматологији – приказ болесника

Сечил Чалишкан, Нурај Тулоглу, Шуле Бајрак

Универзитет Османгази у Ескишехиру, Стоматолошки факултет, Главно одељење за дечју стоматологију, Ескишехир, Турска

### САЖЕТАК

**Увод** Биоагрегат (*BioAggregate*) на бази калцијум-силиката, величине наночестица, произведен је као алтернативна варијанта минералног триоксидног агрегата. Садржи адитиве као што су калцијум-фосфат и силицијум-диоксид, али не садржи алуминијум-оксид и бизмут-оксид. Истраживања су показала да Биоагрегат ослобађа јоне калцијума који су отпорни на ломљење и киселину, биокомпатибилни су и непропустљиви, за разлику од својстава минералног триоксидног агрегата.

**Приказ болесника** У овом чланку испитујемо осам приказа болесника. Ови случајеви објашњавају дугорочне резултате употребе Биоагрегата у подручјима као што су пулпотомија и лечење коренских канала примарних и трајних зуба, дели-

мична пулпотомија, уметна апикална баријерска структура трајних зуба, поправљање ресорпције корена и лечење *dens in dente*.

**Закључак** Као што се види из овде прегледаних случајева, Биоагрегат се може користити као алтернативни материјал минералном триоксидном агрегату у многим стоматолошким третманима. Ови извештаји такође показују да биокомпатибилност, антибактеријска својства, стврдњавање у влажном окружењу, идеалан постотак својстава експанзије, непропустивости и протетског адхезијског својства пружају предности у клиничкој примени.

**Кључне речи:** пулпотомија; лечење коренских канала; Биоагрегат величине наночестица; калцијум-силикат