

## CASE REPORT / ПРИКАЗ БОЛЕСНИКА

# Spontaneous intramural hematoma of the duodenum secondary to anticoagulant drug intoxication

Dragan Vasin<sup>1</sup>, Aleksandra Đurić-Stefanović<sup>1,2</sup><sup>1</sup>Clinical Center of Serbia, Center of Radiology and MR, Belgrade, Serbia;<sup>2</sup>University of Belgrade, Faculty of Medicine, Belgrade, Serbia

## SUMMARY

**Introduction** Duodenal hematomas are commonly traumatic, caused by blunt abdominal trauma. Non-traumatic spontaneous intramural hematomas of the duodenum are rare, and in most cases induced by anticoagulant therapy. The diagnosis is based on clinical and biochemical parameters, endoscopy, and radiological examinations. The objective of this report was to present a clinical and radiological presentation of an intramural duodenal hematoma caused by anticoagulant therapy.

**Case outline** A 43-year-old female was presented with epigastric pain, nausea, hematemesis, and melena. She had a positive medical history of deep venous thrombosis of the pelvis, which was diagnosed the previous month, for which she received oral anticoagulant therapy (coumarin). Physical examination revealed diffuse abdominal tenderness, while laboratory analyses showed markedly elevated international normalized ratio (INR) of prothrombin time (INR > 7), which indicated the anticoagulant intoxication. Computed tomography (CT) showed luminal narrowing with uniform circumferential wall thickening of the descendent and horizontal part of duodenum, which was hyper dense in the native series and slight and uniform ring-formed enhancement in post-contrast phases, a typical CT presentation of intramural duodenal hematoma. Periduodenal and right sided pararenal hematomas were also visualized. After stopping the anticoagulant therapy and performing conservative treatment (vitamin K) with good therapeutic effect being monitored by physical examination, laboratory analyses and transabdominal ultrasonography, spontaneous resolution of the duodenal hematoma was revealed by follow-up CT examination two weeks after the onset.

**Conclusion** Ultrasonography and CT are useful diagnostic tools in recognition of the intramural duodenal hematoma and other locations of hemorrhage and in monitoring therapeutic effects.

**Keywords:** duodenal hematoma; anticoagulant intoxication; ultrasonography; computed tomography

## INTRODUCTION

Intramural hematoma of the duodenum commonly is traumatic, caused by a blunt abdominal trauma [1]. Nontraumatic spontaneous intramural hematomas are rare, and most cases have been induced by anticoagulant therapy [2, 3]. Such case was reported first time in 1838 [4]. Duodenum is the rarest site of the spontaneous intramural hematoma of the small bowel (about 10%) in comparison to the jejunum and ileum [5, 6]. This condition can be life threatening if bleeding is massive so a rapid and accurate diagnosis is required. The diagnosis is based on clinical and biochemical parameters, endoscopy and radiological examinations such are X-ray contrast upper gastrointestinal examination, endoscopic ultrasound (EUS), transabdominal ultrasonography (US), computed tomography (CT) or magnetic resonance imaging (MRI). Early identification by using the CT is very important in order to promptly stop the oral anticoagulant therapy and introduce the antagonists of warfarin, which would allow avoiding the surgical treatment [7]. The objective of this report was to present clinical and radiological

presentation of intramural duodenal hematoma caused by anticoagulant therapy.

## CASE REPORT

A 43-year-old female patient was presented with the epigastric pain, nausea, haematemesis and melena. She had a positive medical history of deep venous thrombosis of the pelvis one month ago, why she has received cumarin anticoagulant therapy (acenocoumarol). Physical examination revealed diffuse abdominal tenderness without defense and subcutaneous hematoma of the left lower leg with the presence of melena on digital rectal examination. Laboratory analyses showed leukocytosis ( $24 \times 10^9/L$ ), anemia (hemoglobin 113 g/L, MCV 82), elevated C-reactive protein (243 mg/L) and markedly elevated international normalized ratio (INR) of prothrombin time (INR > 7), which indicated the anticoagulant intoxication (reference range of INR is < 1.3). Upper flexible endoscopy demonstrated narrowed lumen of the descendent duodenum with the intact mucosa.

**Received • Примљено:**

April 10, 2019

**Revised • Ревизија:**

June 2, 2019

**Accepted • Прихваћено:**

June 25, 2019

**Online first:** July 4, 2019**Correspondence to:**

Aleksandra ĐURIĆ-STEFANOVIĆ  
First Surgery University Clinic  
Unit of Digestive Radiology  
Center of Radiology and MR  
Clinical Center of Serbia  
Koste Todorovica 6  
11000 Belgrade, Serbia  
[avstefan@eunet.rs](mailto:avstefan@eunet.rs)

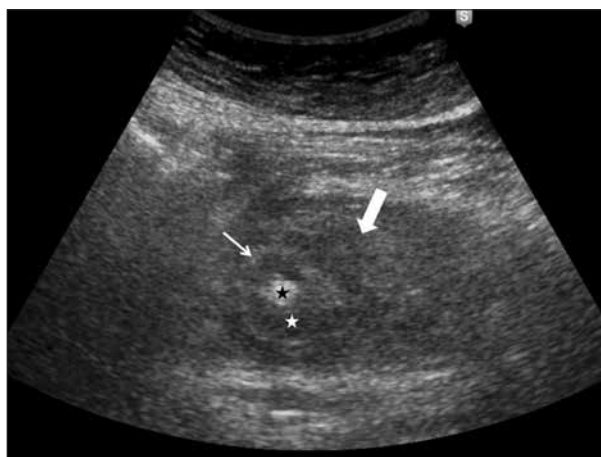Transabdominal US showed distended stomach and circumferential, uniformly hypoechoic duodenal wall thickening with the periduodenal fat stranding and small amount of fluid in the hepatorenal recess (Figure 1). Abdominal CT examination was performed using the following protocol: after the ingestion of 1.5 L of water, the three-phase CT scanning was performed (native phase and late arterial and portal venous post-contrast phase). CT showed luminal narrowing with uniform circumferential wall thickening of the descending and horizontal part of the duodenum, which was hyper dense in the native series and slight and uniform ring-formed enhancement in the post-contrast phases, a typical CT presentation of intramural duodenal hematoma. Periduodenal and right-sided pararenal hematomas were also visualized. CT revealed luminal narrowing with the uniform circumferential wall thickening of the descending and horizontal part of the duodenum (Figure 2). Thickened duodenal wall was hyperdense in the native (Figure 3) and both post-contrast phases, with mild and uniform post-contrast attenuation of the whole wall and marked hyperattenuation of the mucosal layer (Figure 4). Periduodenal strips were propagated towards the right anterior pararenal fascia, hepatorenal recess, mesentery, and recto-uterine recess (Figure 4). According to the CT presentation, the diagnosis of the intramural duodenal hematoma together with the periduodenal hematoma and right perirenal hematoma was established (Figures 2, 3, and 4).

After stopping the anticoagulant therapy and performing conservative treatment (vitamin K was given to reverse the anticoagulant effect of coumarin) with the good therapeutic effect being monitored by laboratory analyses and transabdominal US, spontaneous resolution of the duodenal hematoma was revealed by follow-up CT examination two weeks after the onset.

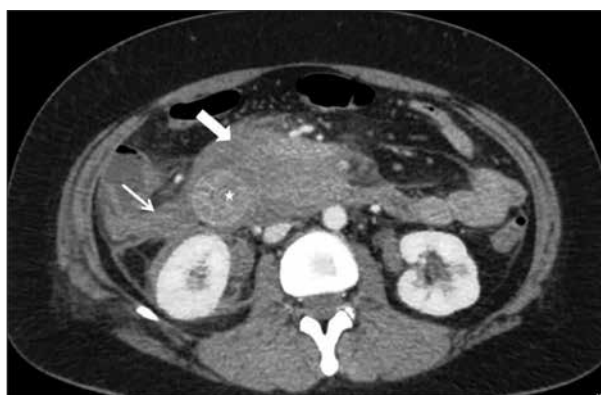
## DISCUSSION

Spontaneous intramural duodenal hematoma is usually associated with coagulation factors' abnormalities resulting from anticoagulation drugs [8]. The vitamin K antagonist warfarin remains a primary agent for oral anticoagulation in the treatment of thromboembolic disorders [9]. Due to its extensive interpatient variability and narrow therapeutic range, warfarin requires frequent laboratory monitoring by INR testing and close patient follow-up in order to prevent adverse effects of therapy such is spontaneous bleeding [10]. Hemorrhagic complications of the anticoagulant therapy could be manifested by hematuria, gastrointestinal hemorrhage, cerebral hemorrhage, soft tissue hematoma, epistaxis, and retroperitoneal hematomas [11]. An incidence of a spontaneous intramural hematoma of the duodenum of one per 2,500 patients who receive the warfarin-based anticoagulant therapy was reported [12]. To the best of our knowledge, this is the first case of a spontaneous intramural duodenal hematoma secondary to oral anticoagulant therapy intoxication reported in Serbia.

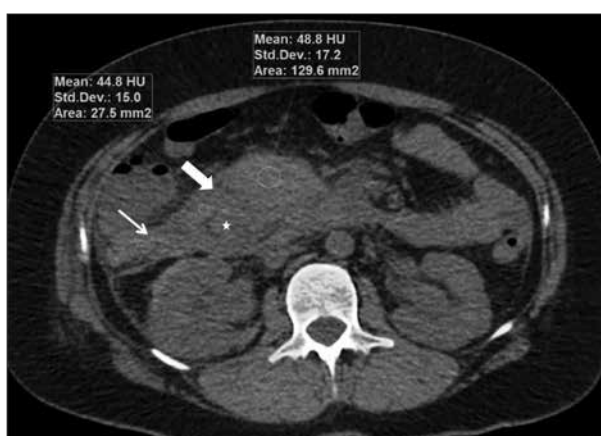Gastrointestinal hemorrhage can be life-threatening due to frequent subclinical manifestations, possibilities of



**Figure 1.** Transabdominal ultrasonography – axial ultrasound scan in the right hypochondrium: thickened and homogenous hypoechoic D2 duodenal wall (white star, thin arrow), with the hypoechoic periduodenal mass (thick arrow), represents intramural and periduodenal hematoma (black star indicates narrowed duodenal lumen)

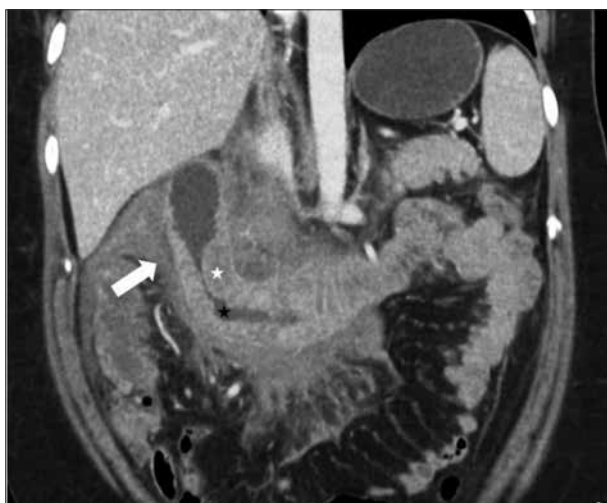

**Figure 2.** Contrast-enhanced abdominal CT – axial scan: thickened and predominantly hyperdense D2 duodenal wall (white star), with luminal narrowing and hyperdense periduodenal mass (thick arrow), represents intramural and periduodenal hematoma; also notice right perirenal hematoma (thin arrow)



**Figure 3.** Non-contrast abdominal CT – axial scan: thickened and hyperdense D2 duodenal wall (average attenuation 44.8 HU) (white star: lumen of the duodenum), with hyperdense periduodenal mass (thick arrow; average attenuation 48.8 HU), represents intramural and periduodenal hematoma; also notice right perirenal hematoma (thin arrow)

intramural and extra luminal bleeding, difficult endoscopic diagnosis in case of massive intraluminal and intramural bleeding and poor results of surgical treatment. Surgical



**Figure 4.** Contrast enhanced abdominal CT – multiplanar coronal reconstruction: thickened and predominantly hyperdense D2 and D3 duodenal wall (white star), with luminal narrowing, and hyperdense periduodenal mass (thick arrow), represents intramural and periduodenal hematoma

treatment should be considered when there is no evidence of partial resolution after conservative treatment, or in cases of perforation or peritonitis, which increases the size of the hematoma [13, 14].

Noninvasive imaging diagnostic tools such as abdominal US or CT scans may help in early diagnosis of intramural hematomas, as well as in detecting other locations of bleeding such as retroperitoneum and peritoneum, urinary tract, and soft tissues. US and CT also serve as imaging tools in evaluating the therapeutic effects of conservative and surgical treatment. Transabdominal ultrasonography

is useful in detection of a thickened duodenal wall and distended fluid-filled stomach as an indirect sign of “gastric outlet” obstruction. CT is crucial in diagnosing intramural hematoma and its causes, and important in monitoring the effects of therapy [1, 2]. If duodenal hematoma is suspected, abdominal CT should be performed in both unenhanced and contrast-enhanced phases after the peroral preparation (the stomach and the duodenum distended with water) [15]. Typical CT presentation of intramural duodenal hematoma, like other intramural hematomas, includes circumferential ring-like hyperdense duodenal wall thickening with luminal narrowing in the native phase, without marked post-contrast enhancement in both arterial and venous phases [1, 2, 15, 16]. In addition to the intramural hematoma, duodenal perforation or intraluminal, periduodenal, and retroperitoneal active bleeding can be detected by contrast-enhanced CT [1, 2]. Due to a similar CT presentation, complicated duodenal ulcer (hemorrhagic or perforated), villous adenoma, or lymphoma of the duodenum could be considered in differential diagnosis with the intramural duodenal hematoma [1].

In summary, we described a rare complication of oral anticoagulant drug therapy, the spontaneous intramural duodenal hematoma. We concluded that intramural duodenal hematoma should be considered in patients presenting with symptoms of gastric outlet obstruction and gastrointestinal bleeding following the anticoagulant therapy. Ultrasonography and CT are useful diagnostic tools in detecting the hematoma, extramural and other locations of hemorrhage and in monitoring the therapeutic effects.

**Conflict of interest:** None declared.

## REFERENCES

- Federle MD. Gastroduodenal trauma. In: Federle MD, Raman SP, editors. *Diagnostic imaging: Gastrointestinal*. 3rd ed. Philadelphia: Elsevier; 2015. p. 326–7.
- Abbas MA, Collins JM, Olden KW. Spontaneous intramural small-bowel hematoma: imaging findings and outcome. *AJR Am J Roentgenol*. 2002; 179(6):1389–94.
- Veldt BJ, Haringsma J, Florijn KW, Kuipers EJ. Coumarin-induced intramural hematoma of the duodenum: case report and review of the literature. *Scand J Gastroenterol*. 2011; 46(3):376–9.
- McLauchlan J. Fatal false aneurysmal tumour occupying nearly the whole of the duodenum. *Lancet*. 1883; 30(766):203–5.
- Samie AA, Theilmann L. Detection and management of spontaneous intramural small bowel hematoma secondary to anticoagulant therapy. *Expert Rev Gastroenterol Hepatol*. 2012; 6(5):553–9.
- Kang EA, Han SJ, Chun J, Lee HJ, Chung H, Im JP, et al. Clinical features and outcome in spontaneous intramural small bowel hematoma: cohort study and literature review. *Intest Res* 2019; 17(1):135–43.
- Eichele DD, Ross M, Tang P, Hutchins GF, Mailliard M. Spontaneous intramural duodenal hematoma in type 2B von Willebrand disease. *World J Gastroenterol*. 2017; 19(41):7205–8.
- Polat C, Dervisoglu A, Guven H. Anticoagulant induced intramural intestinal hematoma. *Am J Emerg Med*. 2003; 21(3):208–11.
- Barnes GD, Lucas E, Alexander GC, Goldberger ZD. National trends in ambulatory oral anticoagulant use. *Am J Med*. 2015; 128(12):1300–5.
- Ansell J, Hirsh J, Dalen J, Bussey H, Anderson D, Poller L, et al. Managing oral anticoagulant therapy. *Chest*. 2001; 119(1 Supl):225–385.
- Hou SW, Chen CC, Chen KC, Ko SY, Wong CS, Chong CF. Sonographic diagnosis of spontaneous intramural small bowel hematoma in a case of warfarin overdose. *J Clin Ultrasound*. 2008; 36(6):374–6.
- Bayraktar A, Ercan LD, Bakkalogly H, Gok AFK, Ilhan M, Aydin AE. Duodenal intramural hematoma due to early postoperative anticoagulant treatment after a renal transplant: a case report. *Ulus Travma Acil Cerrahi Derg*. 2018; 24(6):594–6.
- Zinelis SA, Hershenson LM, Ennis MF, Boller M, Ismail-Beigi F. Intramural duodenal hematoma following upper gastrointestinal endoscopic biopsy. *Dig Dis Sci*. 1989; 34(2):289–91.
- Kwon CI, Ko KH, Kim HY, Hong SP, Hwang SG, Park PW, et al. Bowel obstruction caused by an intramural duodenal hematoma: a case report of endoscopic incision and drainage. *J Korean Med Sci*. 2009; 24(1):179–83.
- Plojoux O, Hauser H, Wettstein P. Computed tomography of intramural hematoma of the small intestine: a report of 3 cases. *Radiology*. 1982; 144(3):559–61.
- Končar I, Davidović L, Čolić M, Dragaš M, Ilić N, Menković N, et al. Intramural hematoma and penetrating aortic ulcer – outcome and treatment modalities: report of four cases. *Srp Arh Celok Lek*. 2011; 139(5–6):380–5.

## Спонтани интрамурални хематом дуоденума као последица интоксикације антикоагулантним лековима

Драган Васин<sup>1</sup>, Александра Ђурић-Стефановић<sup>1,2</sup>

<sup>1</sup>Клинички центар Србије, Центар за радиологију и МР, Београд, Србија;

<sup>2</sup>Универзитет у Београду, Медицински факултет, Београд, Србија

### САЖЕТАК

**Увод** Хематоми дуоденума најчешће су трауматске етиологије, проузроковани ударном повредом трбуха. Нетрауматски спонтани интрамурални хематоми дуоденума су ретки и у највећем броју случајева узроковани антикоагулантном терапијом. Дијагноза се базира на клиничким и биохемијским параметрима, налазима ендоскопије и радиолошких метода прегледа.

Циљ овог рада је приказ клиничке слике и радиолошке презентације интрамуралног хематома дуоденума проузрокованог антикоагулантном терапијом.

**Приказ болесника** Жена стара 43 године се јавила лекару због епигастричног бола, мучнине, хематемезе и мелене. У личној анамнези је постојао податак о дубокој венској тромбози, која је дијагностикована месец дана раније, због чега је примала антикоагулантну терапију на бази кумарина. Физикалним прегледом је констатована дифузна болна осетљивост трбуха, а лабораторијским анализама повишен *INR* (преко 7), што је указивало на интоксикацију антикоагулансима. Компјутеризованом томографијом (КТ)

приказано је сужење лумена, са равномерним, циркумферентним задебљањем зида десцендентног и хоризонталног дела дуоденума; зид је био хипердензан у нативној фази, са слабом и равномерном контрастном опацификацијом у виду прстена у постконтрастним фазама, што је типична презентација на КТ интрамуралног хематома дуоденума. Такође су визуализовани перидуоденални и деснострани параренални хематом. После обустављања антикоагулантне терапије и укључивања конзервативне терапије (витамин К), са добрим терапијским одговором који је потврђен физикалним налазом, лабораторијским анализама и ултразвуком, на контролном прегледу КТ после две недеље констатована је спонтана резолуција интрамуралног хематома дуоденума. **Закључак** Ултразвук и КТ су корисне дијагностичке методе у препознавању интрамуралног хематома дуоденума, екстрамуралне и других локализација крварења, као и у праћењу терапијског ефекта.

**Кључне речи:** хематом дуоденума; интоксикација антикоагулансима; ултразвук; компјутеризована томографија