

CASE REPORT / ПРИКАЗ БОЛЕСНИКА

Focal brain lesions as a consequence of an obscure neurosurgical treatment in a drug-addicted patient

Ivana Stojić^{1,2}, Dalibor Ilić¹, Mirela Juković^{1,2}, Miloš Vujanović^{2,3}, Ivana Čanak⁴, Viktor Till^{1,2}¹Clinical Center of Vojvodina, Center for Radiology, Novi Sad, Serbia;²University of Novi Sad, Faculty of Medicine, Novi Sad, Serbia;³Clinical Center of Vojvodina, Clinic for Infectious Diseases, Novi Sad, Serbia;⁴Institute for Pulmonary Diseases of Vojvodina, Sremska Kamenica, Serbia**SUMMARY**

Introduction Infectious or non-infectious noxae may occur in drug-addicted patients who have clinical presentation of meningeal syndrome with a spectrum of possible complications, such as a diffuse or focal brain lesions.

The objective of this report is to present a rare case of a drug-addicted male patient, initially suspected of mycosis of the central nervous system, but computed tomography (CT) and magnetic resonance imaging (MRI) showed the signs of an invasive neurosurgical operation that the patient underwent during the treatment of drug addiction.

Case outline A 37-year-old male patient was hospitalized at the Clinic for Infectious Diseases, Clinical Center of Vojvodina, with a meningeal syndrome, initially suspected of mycosis of the central nervous system. He was diagnosed at the Center for Radiology. Neuroimaging – CT and MRI were used in order to prove or disprove the presence of brain infection. These diagnostic procedures ruled out the presence of brain infection, but opened questions about the type of neurosurgical treatment performed out of legal institution, due to the presence of craniotomy and focal glial brain lesions in the frontal lobes.

Conclusion In drug-addicted patients, meningeal syndrome can be connected with diffuse or focal brain infections. Together with laboratory and clinical analysis, imaging methods contribute to the decision making and optimal treatment of patients. In our case, CT and MRI made a significant contribution in the detection of the focal brain lesions and clarification of their etiology.

Keywords: magnetic resonance imaging; tomography, X-ray computed; substance-related disorders; neuroimaging; craniotomy; nervous system

INTRODUCTION

Intravenous (IV) drug addicts are prone to various blood-borne infectious diseases. Most common are human immunodeficiency virus (HIV) and hepatitis B and C infections [1]. Due to a high coincidence of IV drug use with HIV, malnutrition, and immunodeficiency, we used laboratory tests, serological and molecular biological tests to differentiate these conditions. IV addicts can suffer from numerous infectious and non-infectious diseases of the central nervous system (CNS). Patients with HIV develop neurological complications in 40–80% of cases [2]. These complications arise from opportunistic infections, tumors or HIV encephalitis [2, 3]. They are more often caused by bacteria and fungi than by viruses [4]. These diseases can have a clinical presentation of meningeal syndrome with a spectrum of possible complications, such as diffuse or focal brain lesions [4, 5]. Unexplained and constant headaches in IV drug addicts should raise suspicion of intracerebral abscess along with other life-threatening pathologies [6]. Neuroimaging methods such as computed tomography (CT) and magnetic resonance imaging (MRI) are of crucial importance in setting a diagnosis of parenchymal brain lesions.

The objective of this report is to present a rare case of a 37-year-old drug-addicted male patient, initially suspected of mycosis of the CNS, but after both CT and MRI have been done, it showed the signs of an invasive neurosurgical operation that the patient underwent during the treatment of drug addiction.

This study was conducted in accordance with the Helsinki Declaration and Guidelines for Good Clinical Practice and was approved by the Ethics Committee of the Faculty of Medicine, University of Novi Sad.

CASE REPORT

A 37-year-old intravenous male patient, addicted to drugs for 15 years, came to the emergency department complaining of photophobia, vomiting, and extreme headaches – signs of the meningeal syndrome. The patient was disoriented and uncooperative – thus, medical history was difficult to obtain. He still used heroin from time to time, the last time being 3–4 weeks before admission. He said that he did not have any recent viral or bacterial infection nor loss of body mass. Laboratory analysis showed HCV-positive infections, but HIV status

Received • Примљено:

July 6, 2019

Revised • Ревизија:

September 18, 2019

Accepted • Прихваћено:

September 27, 2019

Online first: October 1, 2019**Correspondence to:**Ivana STOJIĆ
34 Mičurinova Street
Novi Sad 21000
ivana.stojic2901@gmail.com

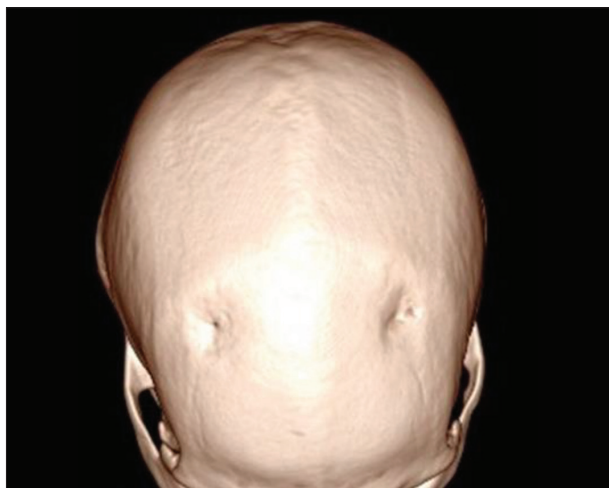

Figure 1. Computed tomography axial bone window displays bone defects of the frontal bones

of the patient was unknown. Clinical examination indicated that the patient was afebrile, somnolent, with old scars on both sides of the frontoparietal scalp. Neurological examination showed that the right pupil was slightly more dilated, meningeal signs were negative, and deep tendon reflexes on the lower extremities were brisker than normally. Other internal and neurological findings were without a coarse outburst. In laboratory findings, slightly elevated inflammation parameters were recorded – sedimentation rate 38/70 mm/h, C-reactive protein 30.1 mg/l (ref. 0–5), fibrinogen was in the normal range, as well as all the other biochemical blood and urine analyses. Acute bacterial and fungal nasopharyngeal infections were excluded (bacterial nasal and pharyngeal cultures, as well as fungal cultures were sterile). Hemoculture, bacteriological, and fungal findings were negative. Serological testing for toxoplasmosis (ELISA method) was negative. Chest X-ray, abdominal and pelvic ultrasonography were made during hospitalization and they were without any pathological findings. Initially, parenteral antibiotics, antimycotics (aminopenicillin, vancomycin, metronidazole, fluconazole), antiedematous therapy (mannitol), nonspecific hepatoprotective drug (Silymarin caps), infusion, and symptomatic (analgesic) therapy were included. The patient remained afebrile the entire time and his headaches had a tendency to regress. Lumbar puncture showed normal cerebrospinal fluid. During his hospitalization, head CT and MRI were done.

Non-enhanced head CT was performed. The contrast was not applied because the peripheral vein could not be accessed. It showed focal hypodense brain lesions in both frontal lobes. An infection of CNS was firstly suspected, but in differential diagnostics malignant tumors could not be excluded. On the bone window, bone defects from previous trepanation were seen on both sides of frontal bones (Figure 1). Acute pansinusitis was detected, most prominently in the right aspect of the frontal sinus, as well as sinusitis of the right maxillary sinus, which was described as mycotic (fungal ball) sinusitis.

Brain MRI and time of flight angiography showed oval T1 weighted (T1W) hypo/T2 weighted (T2W)

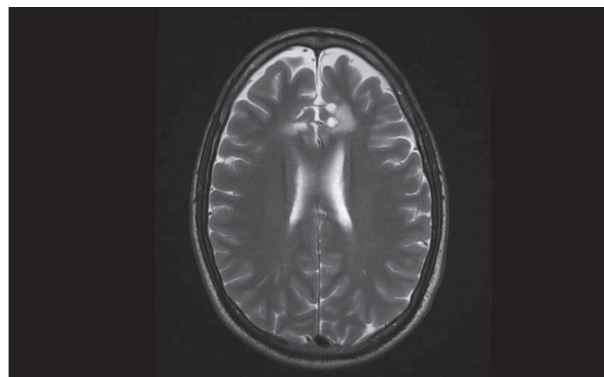


Figure 2. Magnetic resonance imaging T2W axial plane sequence – hyperintense zones frontally parasagittally bilaterally

hyperintense zones (Figure 2) with marginal T2W/FLAIR hyperintensity, without restriction of water molecules diffusion, without postcontrast enhancements frontally parasagittally bilaterally and with no pathological signal on proton density. Symmetrically from these zones throughout the postoperative skull defects there were linear T2W/FLAIR hyperintensities that suit gliosis. These findings are primarily fields of encephalomalacia and gliosis due to a nonstandard neurosurgical procedure. Infectious, malignant, and inflammatory processes were excluded with great certainty.

Just after we presented our results to the patient, he revealed that he underwent a neurosurgical procedure in order to treat his addiction, but he did not have any medical documentation to prove the claim.

DISCUSSION

A persistent headache in IV drug users imposes consideration of infectious complications of the CNS [6]. An afebrile state with normal or slightly elevated inflammatory parameters (leukocytosis, sedimentation, C-reactive protein) do not exclude infection of the CNS [7]. The type of narcotics, route, and length of application significantly affect the etiology, localization, and the form of CNS infection [6]. The severe headache which our patient had could be prescribed to acute pansinusitis detected on CT since we excluded CNS infections.

Focal brain infections in IV drug addicts are among possible complications and are usually caused by *Staphylococcus aureus*, *Streptococcus spp.*, and *Cryptococcus spp.* [6, 8]. Bacterial sinusitis can also be the source of meningitis, cerebritis, and focal parenchymal lesions of the CNS [9]. Given the suspicion of the fungal etiology of focal brain lesions in CNS, we firstly suspected *Cryptococcus neoformans*, which is the most common causative agent of focal brain lesions. But after a non-enhanced CT was done, it made a huge reversal in our diagnosis. We found bone defects on both sides of the frontal bones, and although they could have been caused by a fungus (fungal osteomyelitis), these holes looked like trepanation defects. These facts opened a question about the type of non-documented neurosurgical treatment which was performed out of

a legal institution, due to the presence of a craniotomy. Stereotactic neurosurgical procedure had been initially performed for treating psychiatric complaints [10]. It later extended and was used as a treatment for pain and movement disorders [11]. A recent research has exposed the fact that it can be very useful in patients with an addiction refracted to therapy and for treating Parkinson's disease as well [12, 13]. Nowadays, with the development of deep brain stimulation (DBS), it is mainly used in implanting the intracerebral electrodes [14]. DBS presents an adaptable, adjustable, helpful neurosurgical procedure which delivers electrical pulses to the specific areas in the brain using implanted electrodes [11]. Considering all this, DBS was among our most probable causes, but we had to think of others as well.

Different surgical procedures have been performed to treat drug addiction, but without precise data from a large sample and randomized controlled trials concerning possible complications and the efficiency of the treatment [13]. Frontal lobe plays an important role in cognitive, behavioral and emotional processes with significant interactions between mesolimbic and mesocortical circuits, especially in drug-addicted patients [15]. Dopaminergic dysfunction in neural circuits also plays a specific role in prefrontal and anterior cingulate cortices in drug-addicted patients, and these specific areas are the target sites for neurosurgical interventions [12]. Bilateral cingulotomy and DBS are shown to be possible treatments in the therapy of

addiction, psychiatric diseases, and essential tremor [16]. For the first time in 1973, Balasubramaniam et al. analyzed the results of 28 addicted patients treated with bilateral stereotaxic cingulotomy with no long-term complications [17]. Later, Medvedev et al. [18] also investigated the characteristics and effect of the cingulotomy treatment in 348 heroin-dependent patients in 2003 [13]. Until the 2000s, 300 heroin-addicted patients were treated with bilateral cingulotomy in Russia. DBS can have adverse events, such as infections (1.7%), transient confusions (15.6%), seizures (1.5%), and can lead to death (0–0.4%). Implantation of the electrode, other than minor gliosis, do not cause any other damage to the brain tissue [19].

Brain imaging methods CT and MRI are essential for differential diagnosis and give more information about the types of brain lesions [4, 20]. The significance of radiological imaging modalities in our drug-addicted patient, especially MRI, was to show that the bilateral focal lesions in frontal brain regions did not originate from infections, but were rather a result of an invasive neurosurgical treatment.

In drug-addicted patients; meningeal syndrome could be connected with diffuse or focal brain infections. Together with laboratory and clinical analysis, imaging methods contribute to the decision-making and optimal treatment of patients.

Conflict of interest: None declared.

REFERENCES

- Clarke K, Harris D, Zweifler JA, Lasher M, Mortimer RB, Hughes S. The significance of harm reduction as a social and health care intervention for injecting drug users: an exploratory study of a needle exchange program in Fresno, California. *Soc Work Public Health*. 2016;31(5):398–407.
- Satishchandra P, Mahadevan A, Shibu VP, Ravishankar S, Sidappa N, Udaykumar R, et al. Usefulness of stereotactic biopsy and neuroimaging in management of HIV-1 Clade C associated focal brain lesions with special focus on cerebral toxoplasmosis. *Clin Neurol Neurosurg*. 2013;115(7):995–1002.
- Bowen LN, Smith B, Reich D, Quezado M, Nath A. HIV-associated opportunistic CNS infections: pathophysiology, diagnosis and treatment. *Nat Rev Neurol*. 2016;12(11):662.
- Levine DP, Brown PD. Infections in injection drug users. In: Mandell, Douglas, and Bennett's Principles and Practice of Infectious Diseases (Eighth Edition). Elsevier; 2015. p. 3475–91.
- Shen G, Wu M, Gao B. Opportunistic Infections. In: *Imaging of CNS Infections and Neuroimmunology*. Springer; 2019. p. 79–85.
- Garber B, Glauser J. Complications of Injection Drug Abuse. *Emerg Med Rep*. 2015;36(24).
- Velissaris D, Pintea M, Pantzaris N, Spatha E, Karamouzou V, Pierrakos C, et al. The role of procalcitonin in the diagnosis of meningitis: a literature review. *J Clin Med*. 2018;7(6):148.
- Davidson R, Brent A, Seale A. *Oxford handbook of tropical medicine*. Oxford University Press; 2014.
- Shih RY, Koeller KK. Bacterial, fungal, and parasitic infections of the central nervous system: radiologic-pathologic correlation and historical perspectives: from the radiologic pathology archives. *Radiographics*. 2015;35(4):1141–69.
- Bari AA, Mikell CB, Abosch A, Ben-Haim S, Buchanan RJ, Burton AW, et al. Charting the road forward in psychiatric neurosurgery: proceedings of the 2016 American Society for Stereotactic and Functional Neurosurgery workshop on neuromodulation for psychiatric disorders. *J Neurol Neurosurg Psychiatry*. 2018;89(8):886–96.
- Hell F, Palleis C, Mehrkens JH, Koeglsperger T, Bötzel K. Deep Brain Stimulation Programming 2.0: Future Perspectives for Target Identification and Adaptive Closed Loop Stimulation. *Front Neurol*. 2019;10:314.
- Kahan J, Mancini L, Flandin G, White M, Papadaki A, Thornton J, et al. Deep brain stimulation has state-dependent effects on motor connectivity in Parkinson's disease. *Brain*. 2019;142(8):2417–31.
- Luigjes J, Van Den Brink W, Feenstra M, Van den Munckhof P, Schuurman PR, Schippers R, et al. Deep brain stimulation in addiction: a review of potential brain targets. *Mol Psychiatry*. 2012;17(6):572–83.
- Müller UJ, Voges J, Steiner J, Galazky I, Heinze H, Möller M, et al. Deep brain stimulation of the nucleus accumbens for the treatment of addiction. *Ann N Y Acad Sci*. 2013;1282(1):119–28.
- Wang TR, Moosa S, Dallapiazza RF, Elias WJ, Lynch WJ. Deep brain stimulation for the treatment of drug addiction. *Neurosurg Focus FOC*. 2018;45(2):E11.
- Pycroft L, Stein J, Aziz T. Deep brain stimulation: An overview of history, methods, and future developments. *Brain Neurosci Adv*. 2018;2:2398212818816017.
- Stelten BM, Noblesse LH, Ackermans L, Temel Y, Visser-Vandewalle V. The neurosurgical treatment of addiction. *Neurosurg Focus*. 2008;25(1):E5.
- Medvedev SV, Anichkov AD, Poliakov I. Physiological mechanisms of the effectiveness of bilateral stereotactic cingulotomy in treatment of strong psychological dependence in drug addiction. *Fiziol Cheloveka*. 2003;29(4):117–23.
- Müller UJ, Voges J, Steiner J, Galazky I, Heinze H, Möller M, et al. Deep brain stimulation of the nucleus accumbens for the treatment of addiction. *Ann N Y Acad Sci*. 2013;1282(1):119–28.
- Jindal N, Verma SR, Gupta PK, Mital M. Imaging of Intracranial Space Occupying Lesions: A Prospective Study in A Tertiary Care Centre in Northern India. *IOSR J Dent Med Sci*. 2016;15(5):34–41.

Фокалне лезије мозга као последица нејасног неурохирушког третмана код интравенског корисника психоактивних супстанци

Ивана Стојић^{1,2}, Далибор Илић¹, Мирела Јуковић^{1,2}, Милош Вујановић^{2,3}, Ивана Чанак⁴, Виктор Тил^{1,2}

¹Клинички центар Војводине, Центар за радиологију, Нови Сад, Србија;

²Универзитет у Новом Саду, Медицински факултет, Нови Сад, Србија;

³Клинички центар Војводине, Клиника за инфективне болести, Нови Сад, Србија;

⁴Институт за плућне болести Војводине, Сремска Каменица, Србија

САЖЕТАК

Увод У основи менингеалног синдрома код интравенских корисника психоактивних супстанци диференцијалнодијагностичка размишљања иду у правцу нокси инфективног и неинфективног порекла, са могућим компликацијама као што су дифузне или фокалне лезије мозга.

Циљ рада је приказ случаја интравенског корисника психоактивних супстанци са иницијалном сумњом на микозу централног нервног система, где су компјутеризована томографија (КТ) и магнетна резонанца (МР) показале знакове неурохирушке операције, којој се болесник подвргао у циљу лечења зависности.

Приказ болесника Мушкарац стар 37 година примљен је на Клинику за инфективне болести Клиничког центра Војводине са знацима менингеалног синдрома. Прво се сумњало на микозу централног нервног система, а КТ и МР су се спровеле да би се проверило да ли постоји инфекција. Дијаг-

ностичке процедуре су искључиле постојање инфекције, али се отворило питање о врсти неурохирушке процедуре која је спроведена ван легалне институције, с обзиром на постојање краниотомије и фокалних глијалних лезија у фронталним режњевима.

Закључак Код интравенских корисника психоактивних супстанци менингеални синдром може бити повезан са дифузним или фокалним инфекцијама мозга. Заједно са лабораторијским и клиничким анализама, сликовне методе доприносе доношењу одлука и оптималном третману болесника. У овом случају, КТ и МР су дале значајан допринос у откривању фокалних лезија мозга и разјашњавању њихове етиологије.

Кључне речи: магнетна резонанца; компјутеризована томографија; поремећаји повезани са уносом психоактивних супстанци; неуроснимање; краниотомија; нервни систем