

## CASE REPORT / ПРИКАЗ БОЛЕСНИКА

# Multidisciplinary treatment of patients with chronic odontogenic maxillary sinusitis – a case series

Liana Karapetyan<sup>1</sup>, Valeriy Svistushkin<sup>1</sup>, Ekaterina Diachkova<sup>2</sup>, Svetlana Tarasenko<sup>2</sup>,  
Liudmila Shamaeva<sup>3</sup>

<sup>1</sup>Sechenov First Moscow State Medical University, ENT Department, Moscow, Russian Federation;

<sup>2</sup>Sechenov First Moscow State Medical University, Department of Dental Surgery, Moscow, Russian Federation;

<sup>3</sup>Sechenov First Moscow State Medical University, Maxillofacial Surgery Department, Moscow, Russian Federation



## SUMMARY

**Introduction** The treatment of chronic odontogenic maxillary sinusitis remains an important problem for medicine due to the presence of numerous available techniques, number of complex surgical approaches, performed by an ENT or maxillofacial surgeon or both.

This study aims to analyse different methods of treatment of chronic maxillary sinusitis by several specialists for the choice of the optimal treatment technique.

**Outline of cases** We describe two clinical cases of multidisciplinary treatment of patients with chronic odontogenic maxillary sinusitis with the involvement of different specialists – the ENT and the maxillofacial surgeon. One patient was treated with endoscopic technique, and other underwent classic open sinusotomy using local tissues and xenogenic collagen membrane for removing an oroantral fistula. For assessing the condition before and after the treatment, clinical examination and computed tomography were used.

**Conclusion** According to the results of our study, the endoscopic technique is the preferred method of treatment of patients with chronic maxillary sinusitis when there is no connection with the oral cavity. If an oroantral fistula is present, it is necessary to perform an open operation by a maxillofacial surgeon.

**Keywords:** chronic odontogenic maxillary sinusitis; surgical treatment; multidisciplinary treatment

## INTRODUCTION

Chronic odontogenic sinusitis is a disease that requires the involvement of several specialists in its diagnosis and treatment: an ENT, maxillofacial, and dental surgeon [1, 2]. Moreover, their intervention will depend on the patient's condition and the well-organized collaboration of specialists. In the case of chronic odontogenic sinusitis, both endoscopic sinus sanitation and open surgery in the volume of traditional sinusotomy are possible [2, 3]. Treatment of patients with chronic perforated maxillary sinus (MS) is complex because of the absence of the primary substrate for neo-osteogenesis and the presence of an oroantral fistula. The process of healing and tissue regeneration is extremely slow due to persistent microbial contamination. Disease recurrence is frequent, which then leads to the need for reoperation and reduction in the overall quality of the patient's life.

There is no one common opinion among specialists on how odontogenic maxillary sinusitis should be treated, and by whom – ENT or maxillofacial or oral surgeon. This is one of the reasons why the results are often quite controversial.

To demonstrate our collective work at the Sechenov University, we hereby present two clinical cases with different modalities of surgical treatment.

The subjects' written consent was obtained, according to the Declaration of Helsinki, and the study was approved by the competent ethics committee (protocols of Local Ethics Committee N8 from May 26, 2014, and N10-12 from October 18, 2012) and conforms to the legal standards. Both patients have given oral and written agreement for using their computed tomography (CT) images and medical data.

## CASE REPORT #1

Patient D., a 38-year-old woman, was admitted to the Clinic for ENT Diseases at the Sechenov University with bilateral nasal obstruction, intermittent mucopurulent discharges, mainly from the left side, and intermittent "pulling" pain in the left cheek.

The patient had dental treatment of the left upper jaw about 10 years previously, re-odontic treatment of 2.5–2.6 teeth, followed by their extraction after one year because of exacerbation of chronic apical periodontitis and poor success after therapeutic dental treatment.

The dental implantation in the area of these teeth was planned. After cone beam CT of the paranasal sinuses, the patient was sent by a surgical dentist to the ENT clinic for the treatment of chronic left-side maxillary sinusitis. During

**Received • Примљено:**

August 22, 2019

**Revised • Ревизија:**

February 3, 2020

**Accepted • Прихваћено:**

February 13, 2020

**Online first:** February 20, 2020

**Correspondence to:**

Liudmila SHAMANAeva  
Sechenov First Moscow State  
Medical University  
Maxillofacial Surgery Department  
Trubetskaya 8/2  
Moscow 119991  
Russian Federation  
[shamaeva@bk.ru](mailto:shamaeva@bk.ru)

the examination, nasal breathing was difficult through both halves of the nasal cavity and the mucous membrane of the nasal cavity was pink and moist. The nasal septum was deviated in both directions, more to the right with the formation of a crest in the bone and cartilage and compensatory diffuse hypertrophy of the left inferior nasal concha.

At the time of examination, there was no pathological discharge in the nasal cavity. When examining the oral cavity, teeth 2.5 and 2.6 were missing. The remaining ENT findings were normal. Based on the results of clinical examination and CT, the patient was diagnosed with chronic left-side odontogenic maxillary sinusitis, foreign body of the left MS, nasal septum deviation and hypertrophic rhinitis (Figure 1).

At the Clinic for ENT Diseases at the Sechenov University, the patient underwent septoplasty with a single-step endoscopic operation on the left MS with removal of a foreign body and radio wave correction of the conchae under combined endotracheal anesthesia. The postoperative period was uneventful. On the first day, the operation tampons were removed from the common nasal passages. On the second day, nasal packings were removed from the middle nasal meatus. Nasal and sinus irrigation through the extended natural ostium and applications of the vasoconstrictors were performed.

The patient was discharged on the fourth postoperative day with improvement. Giving the possible presence of postoperative edema of the mucous membrane of the nasal cavity and the left MS, dental implantation was recommended two to three months after surgery.

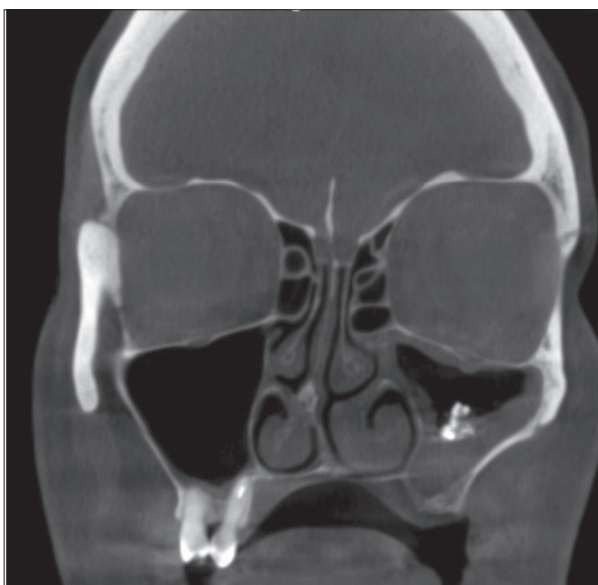
## CASE REPORT #2

Patient S., a 21-year-old man, reported to the Sechenov University at the Department of Surgical Dentistry with facial edema on the right side, and air and food getting from the oral cavity to the nose while eating.

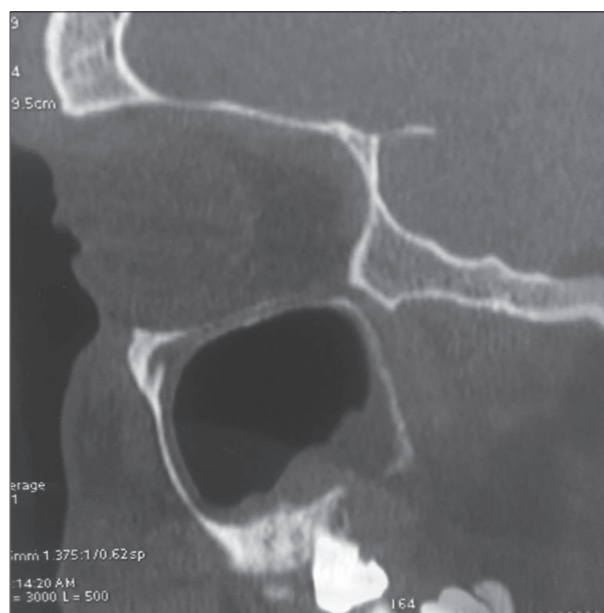The patient had tooth 1.8 removed three weeks previously. A week later, he noted the appearance of these symptoms. His doctor at the dental clinic sutured the area of socket of the previously removed tooth 1.8 with a temporary positive effect. A week later, the buccal edema appeared on the right side of the face and his body temperature rose to 38°C. The patient had again turned to the clinic, where antimicrobial therapy was prescribed. His body temperature returned to normal, but the buccal edema remained.

On the orthopantomogram, prior to the extraction of the tooth 1.8, the root tips were present in the MS.

During the examination, swelling of the cheek on the right side was present, with skin moderately hyperemic, gathered in the fold. On palpation, the temperature of this area was higher compared to the other side. The symptom of fluctuation was negative. Mouth opening was moderately limited to 3.5 cm and painful due to swelling of the cheek on the right side. Swallowing was free and painless. Palpation marked a moderate increase in size of submandibular lymph nodes, more to the right. On examining the oral cavity, the mucous membrane of the right buccal region was swollen, hyperemic and painful during



**Figure 1.** Patient D.; cone beam computed tomography of the paranasal sinuses before surgery; the crest of the nasal septum, the decrease in pneumatization of the left maxillary sinus, and the shadow of high density in the middle sections of the sinus (filling material and dense fungal inclusions) are determined



**Figure 2.** Computed tomogram of patient S; before surgery: the defect of the alveolar process of the right upper jaw, the fistula of the right maxillary sinus with the oral cavity, and thickening of the sinus mucosa are visualised

palpation, and the symptom of fluctuation was positive. When examining the area of a previously removed tooth 1.8, the defect of the alveolar process of the upper jaw was visualized in the retromolar region, with a transition to the vestibular side up to 1.5–1.8 cm. The nasal test was positive. Puncturing the line of mucous membrane closure of the right buccal area, pus was obtained. Abscess of the buccal region on the right and chronic odontogenic sinusitis with oroantral fistula on the right were diagnosed.

Under conditions of local infiltration and conductive anesthesia, a purulent focus was reorganized: an opening

of the abscess of the right buccal region, wound revision, washing with antiseptics, and its drainage. The patient was under dynamic observation and underwent a course of antibacterial therapy. Daily dressing was performed. After the patient's condition improved, a course of physiotherapy was performed (magnetic therapy) to reduce the swelling of the soft tissues of the buccal region. After three weeks (Figure 2), the patient underwent sanitation of the sinus through the bone defect area. Plasty of the oroantral bone fistula was done with local tissues, the buccal flap and collagen xenogenic membrane. The postoperative period was uneventful. During the entire period of dynamic observation of the patient, signs of recurrent oroantral fistula or exacerbation of chronic sinusitis were not detected.

## DISCUSSION

The method of treatment of patients with chronic maxillary sinusitis and oroantral fistula remains a very important problem for otorhinolaryngology, maxillofacial, and oral surgery.

This chronic sinusitis is usually odontogenic in nature and is frequently iatrogenic. For example, Philipsen et al. [4] reported odontogenic cause of chronic sinusitis in 4.7% of 788 patients after their treatment in dental clinics. Tooth extraction is the most common dental procedure that leads to sinusitis, in approximately 30%. The most common reason of perforated form of sinusitis during recent years was the open sinus lifting. Surgeons can damage Schneider membrane during the detachment, thus leaving the connection of the MS with the oral cavity in the most severe cases. According to the literature, the rate of similar situations is not less than 30%.

Due to the complex character of chronic odontogenic maxillary sinusitis (COMS), surgical treatment requires a multidisciplinary approach. There is no method that can be considered the standard of treatment for chronic maxillary sinusitis. Endoscopic surgical techniques promote the transition from extensive type of surgery to minimally invasive. Endoscopic approach allows for saving important anatomical structures of the area operated on and maintaining physiological function in the MS in the postoperative period [5].

On recognized odontogenic nature of maxillary sinusitis and the absence of signs of acute inflammation, there is an opportunity for the primary endodontic preparation of the canals, followed by endoscopic sanitation of the MS by an ENT surgeon. In other cases, when tooth roots do not penetrate mucous membrane of the MS, maxillofacial surgeon (or dental surgeon) can work in collaboration with the ENT surgeon during a single procedure. The first doctor performs tooth extraction, while the second one removes changed mucous membrane of the MS as well as foreign bodies. However, endoscopic treatment has its own limitations associated with the angle of working instruments and endoscopes. This problem can be solved with changing the approach from transnasal to microsurgical intraoral approach under the upper lip.

For example, Karpischenko et al. [6] presented a case report of surgical treatment in a patient with exacerbation

of chronic maxillary sinusitis. Due to multiple previous surgeries (two endoscopic surgeries and one radical sinusotomy of the left MS) 3D CT of paranasal sinuses presented multiple cells with abnormal contents, a front-wall sinus defect, and scar retractions. The complex anatomy of the MS forced the authors to use electromagnetic navigation system during the surgical treatment of the patient. This device allowed for the assessment of the sinus anatomy and adjacent structures and adequate surgical opening of all sinus cells. On control 3D CT scan of the reconstruction of paranasal sinuses, all cells of MS on the side of operation were not damaged [6].

The more difficult case for surgical treatment is the partial location of the upper third molar in oral cavity where there isn't enough soft tissue to provide good impermeability of the surgical wound. This could lead to perforation after tooth extraction and then formation of oroantral fistula. Dental and maxillofacial surgeons must be prepared for these situations and have available different additional instruments, suture and osteoplastic or barrier materials to prevent formation of oroantral fistula.

The difficulties of using different techniques for closing of acute perforation after tooth extraction are connected with wide spreading of microorganism in oral cavity and easy migration through the surgical wound to MS. Appearance of area inflammation, especially in the zone of intraoperative bleeding with later formation of hematoma, leads to development of acute maxillary sinusitis in postoperative period. The presence of microorganism increases the risk of suture failure and the inability of secondary wound healing during persistent infection. Thus, methods and materials for closing of acute perforation of MS and oroantral fistula should be chosen very carefully.

There are various techniques of repairing odontogenic perforations of the bottom of the MS using mucosal flap from the palatine and the vestibule side of the oral cavity, flaps from the lateral surface of the tongue, the mucous membrane of the cheek and the nasal cavity. All of them have their advantages and disadvantages and require further investigation.

Thus, the issue of treating patients with chronic odontogenic sinusitis remains open due to a rather large number of conditions, which makes the selection of the leading specialist complex. With COMS with a foreign body present, if the sinus anatomy is preserved and there is no communication with the oral cavity, it is preferable to conduct endoscopic sanitation of the MS by an ENT specialist. In the presence of an oroantral fistula, additional involvement of the maxillofacial surgeon or dental surgeon is necessary to conduct a full-fledged sinusotomy and to perform reconstructive techniques using osteoplastic materials and flaps.

## ACKNOWLEDGEMENT

The paper was supported by the Russian Academic Excellence Project 5-100.

**Conflict of interest:** None declared.

## REFERENCES

1. Horowitz G, Koren I, Carmel NN, Balaban S, Abu-Ghanem S, Fliss DM, et al. One stage combined endoscopic and per-oral buccal fat pad approach for large oro-antral-fistula closure with secondary chronic maxillary sinusitis. *Refuat Hapeh Vehashinayim*. 2015;32(3):32–7, 68.
2. Naros A, Peters JP, Biegner T, Weise H, Krimmel M, Reinert S. Fungus Ball of the Maxillary Sinus-Modern Treatment by Osteoplastic Approach and Functional Endoscopic Sinus Surgery. *J Oral Maxillofac Surg*. 2019;77(3):546–54.
3. Lopatin AS, Sysolyatin SP, Sysolyatin PG, Melnikov MN. Chronic maxillary sinusitis of dental origin: is external surgical approach mandatory? *Laryngoscope*. 2002;112(6):1056–9.
4. Philipsen BB, Ghawsi S, Kjeldsen AD. Odontogenic sinusitis among patients surgically treated for maxillary sinus disease. *Rhinology Online*. 2018;1:60–6.
5. Vishnyakov V, Yalymova D. Surgical treatment for chronic odontogenic maxillary sinusitis and posttreatment assessment of quality of life in patients. *Vrach*. 2015;7:78–80.
6. Karpischenko SA, Bolozneva EV, Baranskaya SV. Recurrent sinusitis and revision surgery in a patient with a multicells maxillary sinus. *Folia otorhinolaryngologiae et pathologiae respiratoriae*. 2015;21(4):41–6.

## Мултидисциплинарно лечење болесника са хроничном одонтогеном упалом максиларног синуса – прикази болесника

Лијана Карапетјан<sup>1</sup>, Валериј Свистушкин<sup>1</sup>, Јекатерина Дијачкова<sup>2</sup>, Светлана Тарасенко<sup>2</sup>, Људмила Шаманајева<sup>3</sup>

<sup>1</sup>Први московски државни медицински универзитет „И. М. Сеченов“, Катедра за оториноларингологију, Москва, Руска Федерација;

<sup>2</sup>Први московски државни медицински универзитет „И. М. Сеченов“, Катедра за денталну хирургију, Москва, Руска Федерација;

<sup>3</sup>Први московски државни медицински универзитет „И. М. Сеченов“, Катедра за максилофацијалну хирургију, Москва, Руска Федерација

### САЖЕТАК

**Увод** Лечење хроничног одонтогеног максиларног синуситиса и даље је важан проблем за медицину због бројних расположивих техника, сложених хируршких приступа, које обављају оториноларинголошки или максилофацијални хирург или обојица.

Циљ ове студије је да се анализирају различите методе лечења хроничног максиларног синуситиса од стране различитих специјалиста како би се начинио избор најпогодније технике лечења.

**Прикази болесника** Описују се два клиничка случаја мултидисциплинарног лечења болесника са хроничним одонтогеном максиларним синуситисом уз учешће различитих специјалиста – оториноларинголошког и максилофацијалног

хирурга. Један болесник је лечен ендоскопском техником, а други је подвргнут класичној отвореној синусотомiji коришћењем локалних ткива и ксеногене мембране колагена за уклањање ороантралне фистуле. За процену стања пре и после лечења коришћени су клинички преглед и компјутеризована томографија.

**Закључак** Према резултатима ове студије, ендоскопска техника је пожељна метода лечења болесника са хроничним максиларним синуситисом када није повезан са усном шупљином. Ако постоји ороантрална фистула, потребно је да отворену операцију изведе максилофацијални хирург.

**Кључне речи:** хронични одонтогени максиларни синуситис; хируршко лечење; мултидисциплинарни третман