



CASE REPORT / ПРИКАЗ БОЛЕСНИКА

A case report of a hybrid procedure (visceral and partial aortic arch debranching) in the treatment of a challenging aneurysm of the thoracoabdominal aorta in the endovascular era

Miloš Sladojević^{1,2}, Igor Končar^{1,2}, Petar Zlatanović², Sanja Jovanović³, Lazar Davidović^{1,2}

¹University of Belgrade, Faculty of Medicine, Belgrade, Serbia;

²Clinical Center of Serbia, Clinic for Vascular and Endovascular Surgery, Belgrade, Serbia;

³Center for Radiology and Magnetic Resonance Imaging, Clinical Center of Serbia, Belgrade, Serbia

SUMMARY

Introduction This paper aimed to present a hybrid approach as a less invasive and acceptable treatment.

Case outline Because of respiratory failure, the patient was deemed at high risk for open repair. Standard thoracic endovascular aortic repair (TEVAR) was unfeasible, so the patient underwent the hybrid procedure – partial aortic arch debranching at the first stage, followed by visceral debranching and endovascular exclusion of thoracic aortic aneurysm as a final procedure. The postoperative course was uneventful and the patient was discharged 10 days after TEVAR and visceral debranching.

Conclusion Staged hybrid procedure with combined debranching of the aortic arch and visceral arteries is feasible and should be considered as an alternative treatment option in patients with high-risk for open repair.

Keywords: endovascular procedure; aortic aneurysm; dissecting aneurysm

INTRODUCTION

Hybrid treatment with visceral and arch vessel debranching followed by thoracic endovascular aortic repair (TEVAR) has been used to treat high-risk patients and therefore allows treatment in this population group [1, 2, 3]. This paper aimed to present a hybrid approach as a less invasive and acceptable treatment.

CASE REPORT

A 56-year-old male was admitted to our hospital due to chronic dissecting aneurysm of the thoracic aorta with the maximum diameter of 8 cm (Figure 1). Visceral and infrarenal part of the abdominal aorta was free of dissection and aneurysmal disease. A few years ago, he suffered acute aortic dissection. Considering co-existing chronic obstructive pulmonary disease (forced expiratory volume in the first second was 50%), the patient's condition carried high risk for open repair. Multidetector computed tomography with angiography (MDCTA) imaging showed that standard TEVAR was unfeasible because of inappropriate characteristics of the proximal and distal sealing zone, so staged hybrid procedure was selected. Partial debranching of the aortic arch and visceral arteries provided an adequate length of both sealing zones of 25 mm. To achieve adequate

proximal sealing zone for stent-graft deployment in the Ishimaru zone 1 of the aortic arch, we performed extrathoracic paratracheal carotid–carotid bypass in a right-to-left manner in conjunction with carotid–subclavian bypass using 8 mm tubular Dacron graft. After the transverse section of the left common carotid artery, the proximal part was ligated, while the distal part was anastomosed to the Dacron graft in an end-to-side fashion. The end-to-side anastomosis was also created to the left subclavian artery. We always endeavor to ligate the subclavian artery. However, in this case, the prevertebral part of the subclavian artery was difficult to approach. The left subclavian artery originated from the proximal landing zone, 12 mm away from the entry tear. Hence, it was expected that stent-graft would cover the artery origin preventing the endoleak from the left subclavian artery. Otherwise, endovascular occlusion of the artery would have been indicated. The procedure was performed under general anesthesia. The carotid shunt was not used because the retrograde flow from common carotid arteries was pulsatile. The postoperative course was uneventful, so two days later we performed visceral debranching via the midline laparotomy. The right common iliac artery was selected as an adequate inflow vessel for visceral debranching. Celiac trunk (CT) revascularization was accomplished via bypass to the common hepatic artery (CHA)

Received • Примљено:
July 31, 2019

Revised • Ревизија:
February 5, 2020

Accepted • Прихваћено:
February 17, 2020

Online first: February 20, 2020

Correspondence to:

Sanja JOVANOVIĆ
Center for Radiology and MRI
Clinical Center of Serbia
Pasterova 2
11000 Belgrade, Serbia
dr.sanja.jovanovic@gmail.com

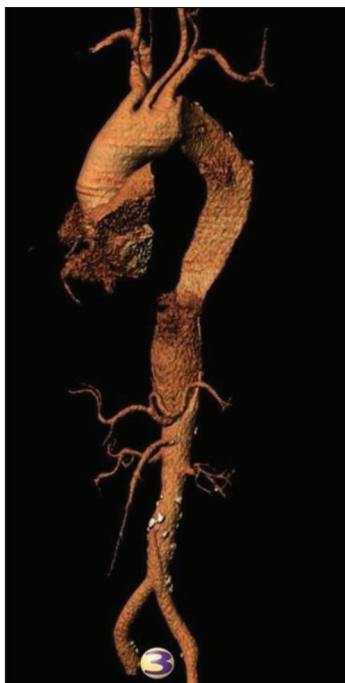

Figure 1. Multidetector computed tomography with angiography in volume rendering reconstruction; a chronic dissecting aneurysm of the thoracic aorta

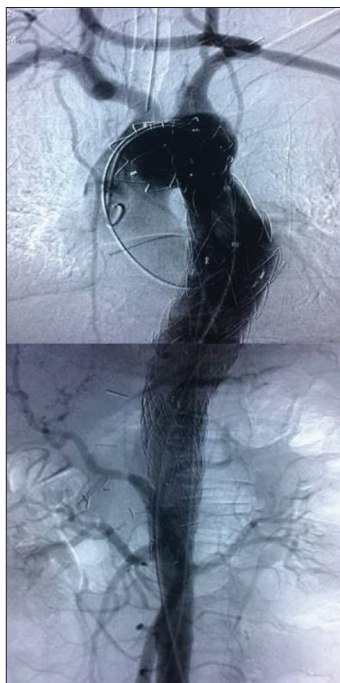


Figure 2. Completion angiography after thoracic endovascular aortic repair

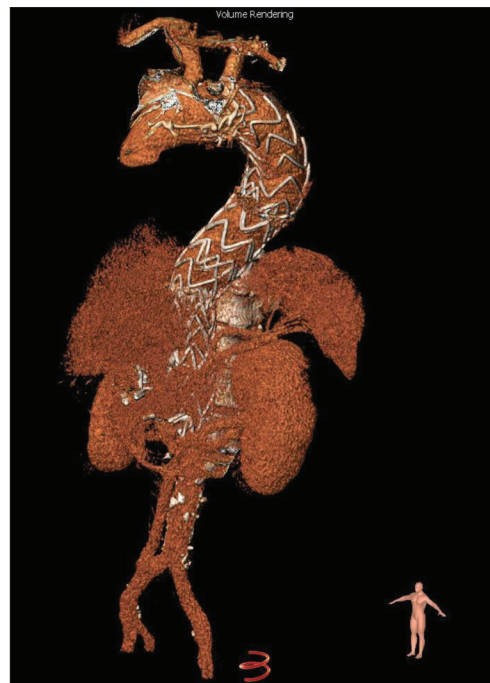


Figure 3. Multidetector computed tomography with angiography in volume rendering reconstruction, five years after thoracic endovascular aortic repair

in an end-to-side fashion. CT and CHA were approached through the gastrohepatic ligament in the lesser sac, while superior mesenteric artery (SMA) was identified at the base of the transverse mesocolon proximally to the origin of the middle colic artery. We used a jump graft (tubular Dacron graft of 8 mm) from the SMA to the CHA. The graft was passed retroperitoneally from the right common iliac artery to the SMA and then behind the pancreas to the CHA. The CT and SMA were ligated after completion of the bypass to avoid retrograde filling of the aneurysm sac. TEVAR was performed immediately after visceral debranching via the left transfemoral approach (Figure 2).

The thoracic aortic aneurysm was excluded using three Valiant Thoracic Stent Grafts (Medtronic Vascular, Santa Rosa, CA, USA) deployed above the renal arteries upwards to the innominate artery using the distal-to-proximal implantation technique which enables the deployment of a larger diameter stent-graft into a smaller diameter graft. Oversizing at the proximal and distal landing zone was 10–15%. To prevent paraplegia, cerebrospinal fluid drainage was used during the following 72 hours to maintain the intrathecal pressure below 10 mmHg and mean arterial pressure was targeted at ≥ 80 mmHg. The postoperative course was uneventful and the patient was discharged 10 days after TEVAR and visceral debranching. After five years of follow-up, MDCTA showed the regular position of the stent-graft and regular patency of the supra-aortic and visceral debranching (Figure 3).

This case report was approved by the institutional ethics committee, and written consent was obtained from the patient for the publication of this case report and any accompanying images.

DISCUSSION

In this paper, we report a case with a chronic dissecting thoracic aortic aneurysm who successfully underwent hybrid procedure. In terms of age and respiratory comorbidity, our patient was considered high risk for conventional open repair of a thoracic aortic aneurysm, which would require thoracophrenolombotomy, single-lung ventilation, and aortic cross-clamping. A less invasive hybrid approach was indicated as an acceptable treatment. Its theoretical advantages implicate avoiding extensive two-cavity exposure, aortic cross-clamping, and extracorporeal circulation. Dissecting aortic aneurysm involved the thoracic part from the left subclavian artery to the CT. In order to achieve the adequate length of sealing zones and endograft apposition to the inner aortic curvature, partial arch debranching and retrograde bypass to the CT and the SMA were necessary. We opted for a two-stage hybrid treatment. Extra-thoracic partial debranching of the aortic arch was performed as a first procedure. We used the pretracheal route for crossover right-to-left carotid–carotid bypass, which we considered easier for tunneling and with more space for anastomosis creation. Other authors prefer the retropharyngeal route as a shorter and more direct path across the neck [4]. Also, in elective cases in which the left subclavian artery is going to be covered by endograft, we always perform a left carotid to subclavian artery bypass to prevent spinal cord ischemia, stroke, and arm claudication. Visceral debranching did not include renal arteries revascularization, so TEVAR was performed during the same procedure. In cases that require renal arteries clamping and revascularization, some authors recommend that TEVAR should be performed a

few days after visceral debranching to allow the kidneys to recover from the ischemia associated with the bypass before subjecting them to the nephrotoxic iodinated contrast during TEVAR [5]. Because of extensive coverage of the thoracic aorta, our patient was deemed as a high risk for spinal cord ischemia, hence prophylactic cerebrospinal fluid drainage was used as recommended by current guidelines of the European Society for Vascular Surgery [6].

Instead of hybrid procedures, in some institutions total endovascular repair is possible using custom-made and physician-modified fenestrated and branched devices, as well as parallel graft techniques (chimney/periscope).

Published mid-term results of endovascular renal and visceral artery revascularization are encouraging. Recently published studies showed a high technical success rate of 94–96% and primary five-year visceral arteries patency of 93% after fenestrated and branched endografts; however, in the same period, reinterventions were necessary in half of the cases [7, 8]. Also, Tsilimparis et al. [7] showed favorable outcomes of this technique, which is associated with lower mortality and morbidity (acute renal failure and mesenteric ischemia) in comparison to the hybrid procedure. High device costs and long manufacturing of custom-made fenestrated and branched devices limit this technique in cases with huge and symptomatic aneurysms. Also, these devices are not available in many centers in developing countries. Alternative “off the shelf” endovascular techniques, like parallel graft techniques and physician-modified fenestrated stent-grafts, involve the use of standard grafts with good short-term and mid-term results [9–15]. Considering the anatomy of our case, we deemed that the diameter and shape of the true lumen were inadequate to accommodate two chimney grafts for the CT and the SMA. Furthermore, we assessed that periscope graft in these arteries would be associated with acute angulation and risk for thrombosis.

Fenestrated stent-grafting in the aortic arch is technically challenging due to difficulties in stent-graft orientation and fenestration positioning. *In situ* fenestration techniques might avoid these problems, but because of possible issues with stent-grafts durability and ischemic complications during temporary carotid arteries coverage, this technique has not been widely adopted [16, 17, 18]. In recent years, arch branched endografts have been

developed as a new technique for revascularization of supra-aortic branches. Despite encouraging initial results, further studies are required to standardize this technique [19, 20, 21]. Chimney technique to extend the proximal landing zone in TEVAR is feasible in the majority of vascular centers, with satisfied midterm outcomes, but not without a risk of major complications [22–25]. Zhao et al. [26] compared the outcomes of the chimney and hybrid technique for the reconstruction of a single arch branch and found that type Ia endoleak rate was significantly higher in the chimney group. Supra-aortic branch angulation and excessive oversizing were determined as a major risk factor for type Ia endoleak. Furthermore, compression and fracture of chimney graft, as well as retrograde type A aortic dissection, can lead to lethal consequences [27, 28]. Frequently performed excessive oversizing and ballooning of endografts, as well as more than one chimney graft, carry the greatest risk for retrograde dissection. In our institution, fenestrated and branched endograft techniques are not an option for aortic repair yet. Although the problem of the proximal landing zone in our case could be resolved by two chimney grafts for the left subclavian and the common carotid artery, we did not consider this technique because of the abovementioned reasons.

In selected cases of difficult aortic arch anatomy and risk for retrograde type A dissection after TEVAR, a frozen elephant trunk can be an alternative method for arch repair [29]. Sometimes, when the aortoiliac segment is not suitable for inflow, antegrade visceral debranching from the ascending aorta might be performed [30].

Staged hybrid procedure with combined debranching of the aortic arch and the visceral arteries is feasible and should be considered as a treatment option in patients with high-risk for open repair.

ACKNOWLEDGMENT

The presented article is a part of a scientific research project (No. 175008) supported by the Ministry of Education, Science and Technological Development of the Republic of Serbia.

Conflict of interest: None declared.

REFERENCES

- Väärämäki S, Suominen V, Pimenoff G, Saarinen J, Uurto I, Salenius J. Hybrid repair of thoracoabdominal aortic aneurysms is a durable option for high-risk patients in the endovascular era. *Vasc Endovascular Surg.* 2016;50(7):491–6.
- Benrashed E, Wang H, Andersen ND, Keenan JE, McCann RL, Hughes GC. Complementary roles of open and hybrid approaches to thoracoabdominal aortic aneurysm repair. *J Vasc Surg.* 2016;64(5):1228–38.
- De Rango P, Cao P, Ferrer C, Simonte G, Coscarella C, Cieri E, et al. Aortic arch debranching and thoracic endovascular repair. *J Vasc Surg.* 2014;59(1):107–14.
- Bergeur R, Gonzalez JA. Revascularization by the retropharyngeal route for extensive disease of the extracranial arteries. *J Vasc Surg.* 1994;19(2):217–24.
- Hughes GC, Barfield ME, Shah AA, Williams JB, Kuchibhatla M, Hanna JM, et al. Staged total abdominal debranching and thoracic endovascular aortic repair for thoracoabdominal aneurysm. *J Vasc Surg.* 2012;56(3):621–9.
- Riambau V, Bockler D, Brunkwall J, Cao P, Chiesa R, Coppi G, et al. Management of descending thoracic aorta diseases: clinical practice guidelines of the European Society for Vascular Surgery (ESVS). *Eur J Vasc Endovasc Surg.* 2017;53(1):4–52.
- Tsilimparis N, Debus SE, Biehl M, Spanos K, Larena-Avallaneda A, Wipper S, et al. Fenestrated-branched endografts and visceral debranching plus stenting (hybrid) for complex aortic aneurysm repair. *J Vasc Surg.* 2018;67(6):1684–9.
- Oderich GS, Ribeiro M, Reis de Souza L, Hofer J, Wigham J, Cha S, et al. Endovascular repair of thoracoabdominal aortic aneurysms

- using fenestrated and branched endografts. *J Thorac Cardiovasc Surg.* 2017;153(2):S32–S41.e7.
9. Touma J, Verscheure D, Majewski M, Desgranges P, Cochenne F. Parallel Grafts Used in Combination with Physician-Modified Fenestrated Stent Grafts for Complex Aortic Aneurysms in High-risk Patients with Hostile Anatomies. *Ann Vasc Surg.* 2018;46:265–73.
 10. Cochenne F, Kobeiter H, Gohel M, Leopardi M, Raux M, Majewski M, et al. Early Results of Physician Modified Fenestrated Stent Grafts for the Treatment of Thoraco-abdominal Aortic Aneurysms. *Eur J Vasc Endovasc Surg.* 2015;50(5):583–92.
 11. Lachat M, Veith FJ, Pfammatter T, Glenck M, Bettex D, Mayer D, et al. Chimney and periscope grafts observed over 2 years after their use to revascularize 169 renovisceral branches in 77 patients with complex aortic aneurysms. *J Endovasc Ther.* 2013;20(5):597–605.
 12. Lindblad B, Bin Jadr A, Holst J, Malina M. Chimney Grafts in Aortic Stent Grafting: Hazardous or Useful Technique? Systematic Review of Current Data. *Eur J Vasc Endovasc Surg.* 2015;50(6):722–31.
 13. Schwierz E, Kolvenbach RR, Yoshida R, Yoshida W, Alpaslan A, Karmeli R. Experience with the sandwich technique in endovascular thoracoabdominal aortic aneurysm repair. *J Vasc Surg.* 2014;59(6):1562–9.
 14. Pecoraro F, Veith FJ, Puipe G, Amman-Vesti B, Bettex D, Rancic Z, et al. Mid- and Longer-term Follow up of Chimney and/or Periscope Grafts and Risk Factors for Failure. *Eur J Vasc Endovasc Surg.* 2016;51(5):664–73.
 15. Moulakakis KG, Mylonas SN, Avgerinos E, Papapetrou A, Kakisis JD, Brountzos EN, et al. The chimney graft technique for preserving visceral vessels during endovascular treatment of aortic pathologies. *J Vasc Surg.* 2012;55(5):1497–503.
 16. Shang T, Tian L, Li DL, Wu ZH, Zhang HK. Favourable Outcomes of Endovascular Total Aortic Arch Repair Via Needle Based In Situ Fenestration at a Mean Follow-Up of 5.4 Months. *Eur J Vasc Endovasc Surg.* 2018;55(3):369–76.
 17. Glorion M, Coscas R, McWilliams RG, Javerliat I, Goëau-Brissonniere O, Coggia M. A Comprehensive Review of In Situ Fenestration of Aortic Endografts. *Eur J Vasc Endovasc Surg.* 2016;52(6):787–800.
 18. Zhu J, Dai X, Noiniyom P, Luo Y, Fan H, Feng Z, et al. Fenestrated Thoracic Endovascular Aortic Repair Using Physician-Modified Stent Grafts (PMSGs) in Zone 0 and Zone 1 for Aortic Arch Diseases. *Cardiovasc Intervent Radiol.* 2019;42(1):19–27.
 19. Clough RE, Spear R, Van Calster K, Hertault A, Azzouli R, Sobocinski J, et al. Case series of aortic arch disease treated with branched stent-grafts. *Br J Surg.* 2018;105(4):358–65.
 20. Tsilimparis N, Dettler C, Law Y, Rohlfuss F, Heidemann F, Brickwedel J, et al. Single-center experience with an inner branched arch endograft. *J Vasc Surg.* 2019;69(4):977–85.e1.
 21. Tong Y, Qin Y, Yu T, Zhou M, Liu C, Liu C, et al. 3D Printing to Guide the Application of Modified Pre-fenestrated Stent Grafts to Treat Aortic Arch Disease. *Ann Vasc Surg.* 2002;S0890-5096(20)30007-8.
 22. Li Y, Hu Z, Wang J, Zhang Y, Chen Z, Zhang H. Endovascular Chimney Technique for Aortic Arch Pathologies Treatment: A Systematic Review and Meta-Analysis. *Ann Vasc Surg.* 2018;47:305–15.
 23. Voskresensky I, Scali ST, Feezor RJ, Fatima J, Giles KA, Tricario R, et al. Outcomes of thoracic endovascular aortic repair using aortic arch chimney stents in high-risk patients. *J Vasc Surg.* 2017;66(1):9–20.
 24. Ahmad W, Mylonas S, Majd P, Brunkwall JS. A current systematic evaluation and meta-analysis of chimney graft technology in aortic arch diseases. *J Vasc Surg.* 2017;66(5):1602–10.
 25. Wang T, Shu C, Li M, Li QM, Li X, Qui J, et al. Thoracic Endovascular Aortic Repair With Single/Double Chimney Technique for Aortic Arch Pathologies. *J Endovasc Ther.* 2017;24(3):383–93.
 26. Zhao Y, Cui J, Yin H, Wang M, Li Z, Yao C, et al. Hybrid operation versus the chimney technique for reconstruction of a single aortic arch branch: a single-centre experience. *Interact Cardiovasc Thorac Surg.* 2017;25(4):575–81.
 27. Kasahara H, Inoue Y, Hachiya T. Open Conversion for Type A Ascending Aortic Dissection after Thoracic Endovascular Aortic Repair by the Chimney Graft Technique. *Ann Thorac Cardiovasc Surg.* 2018;24(3):157–60.
 28. Hirano K, Tokui T, Nakamura B, Inoue R, Inagaki M, Maze Y, et al. Retrograde Ascending Dissection After Thoracic Endovascular Aortic Repair Combined With the Chimney Technique and Successful Open Repair Using the Frozen Elephant Trunk Technique. *Vasc Endovascular Surg.* 2018;52(1):80–5.
 29. Charchyan E, Breshenkov D, Belov Y. Follow-up outcomes after the frozen elephant trunk technique in chronic type B dissection. *Eur J Cardiothorac Surg.* 2020;57(5):904–11.
 30. Torsello G, Can A, Umscheid T, Tessarek J. Hybrid thoracoabdominal aneurysm repair with simultaneous antegrade visceral revascularization and supra-aortic debranching from the ascending aorta. *J Endovasc Ther.* 2007;14(3):342–6.

Приказ хибридне процедуре (висцералног и парцијалног 'дебранчинга' лука аорте) у третману комплексне анеуризме торакоабдоминалне аорте у ендоваскуларној ери

Милош Сладојевић^{1,2}, Игор Кончар^{1,2}, Петар Златановић², Сања Јовановић³, Лазар Давидовић^{1,2}

¹Универзитет у Београду, Медицински факултет, Београд, Србија;

²Клинички центар Србије, Клиника за васкуларну и ендоваскуларну хирургију, Београд, Србија;

³Клинички центар Србије, Центар за радиологију и магнетну резонанцу, Београд, Србија

САЖЕТАК

Увод Циљ овог рада био је да прикаже хибридни третман као мање инвазивну и прихватљиву опцију лечења.

Приказ болесника Због значајног респираторног коморбидитета болесник је био неприхватљивог ризика за класичну отворену хирургију анеуризме торакалне аорте. Такође, стандардни ендоваскуларни третман није био могућ због неадекватне проксималне и дисталне зоне фиксације, те је болесник третиран хибридном процедуром. Процедура је рађена у два акта. У првом акту учињен је парцијални 'дебранчинг' (енгл. *debranching* – одвајање грана од главног

стабла) лука аорте. У другом акту учињен је висцерални 'дебранчинг', после чега је анеуризма торакалне аорте ексکلудирана имплантацијом стент-графта. Постоперативни ток је протекао без компликација и болесник је отпуштен десетог постоперативног дана.

Закључак Комплексна хибридна процедура у два акта која укључује 'дебранчинг' аортног лука, а потом и висцералних артерија, представља могућу терапијску опцију код болесника са високим ризиком за отворено хируршко лечење.

Кључне речи: ендоваскуларна процедура; анеуризма аорте; аортна дисекција