



## CASE REPORT / ПРИКАЗ БОЛЕСНИКА

# A rare mechanism of subconjunctival dislocation of anterior chamber intraocular lens after blunt ocular trauma

Mladen Bila, Igor Kovačević, Goran Damjanović, Jelena Potić, Jelena Karadžić

Clinical Center of Serbia, Clinic for Eye Diseases, Belgrade, Serbia

**SUMMARY**

**Introduction** Dislocation of intraocular lens (IOL) after ocular trauma is an emergency situation requiring prompt surgery. Dislocation of IOL into the subconjunctival space or pseudophacocoele is a rare event after blunt ocular trauma.

**Case outline** We report a case of a pseudophakic patient with a dislocation of the anterior chamber IOL (ACIOL) into subconjunctival space following blunt trauma to the right eye. A 76-year-old man presented with ACIOL dislocation into subconjunctival space, adapted old scleral wound and preserved corneal integrity. Fifteen years previously he suffered right eye globe rupture after blunt trauma, which was surgically closed and ACIOL was inserted.

**Conclusion** This case highlights a rare mechanism of ACIOL dislocation into subconjunctival space following blunt ocular trauma with preserved corneal integrity and adapted old scleral wound. In cases of post-traumatic aphakia, IOL dislocation into the subconjunctival space should be suspected.

**Keywords:** ocular trauma; intraocular lens; subconjunctival lens dislocation; eye globe rupture; epiretinal membrane

**INTRODUCTION**

Ocular trauma may cause significant ocular morbidity and is usually associated with the displacement of the natural lens in a phakic eye and of the intraocular lens (IOL) in a pseudophakic eye [1]. Biedner et al. [2] first defined the term “pseudophacocoele” for the subconjunctival extrusion of an IOL associated with eyeball rupture following blunt ocular trauma. Pseudophacocoele represents a rare clinical condition and therefore scarce data on patients' visual outcomes are reported. Blunt eye trauma may lead to IOL subluxation, dislocation into the vitreous cavity, anterior chamber or suprachoroidal space, or IOL may be extruded from the eye in the subconjunctival space, most commonly through the surgical wound [3].

We present a rare case of blunt ocular trauma in which an anterior chamber IOL was dislocated into the subconjunctival space with preserved integrity of bulbar wall despite the ocular trauma.

**CASE REPORT**

A 76-year-old man was admitted to our Clinic for Eye Diseases and presented with subconjunctival anterior chamber intraocular lens (ACIOL) dislocation following blunt trauma. He reported that he had suddenly lost consciousness, fallen down, and struck his right eye against a bedside table a month earlier. Medical

history included transient ischemic attacks with sudden loss of consciousness. His ocular history included right eye globe rupture due to a similar blunt ocular trauma that he experienced 15 years previously. At that time, the globe rupture was surgically treated and the scleral wound was closed at another eye clinic. Later that year the ACIOL was inserted into his right eye at the same eye clinic. He had undergone a cataract operation with implantation of a posterior chamber intraocular lens (PCIOL) in his left eye several years prior to the latest blunt trauma.

The patient's best corrected visual acuity was 6/60 on the right eye and 6/6 on the left eye. Intraocular pressure of the right eye was 13 mmHg and 16 mmHg of the left eye. Slit lamp examination of the anterior segment in his right eye showed mild hyperemia of the bulbar conjunctiva and displaced ACIOL in the inferotemporal subconjunctival space (Figure 1). Examination of the sclera revealed an intact and adapted old scleral wound at 12 to 3 o'clock, with incarcerated uveal tissue at 2 o'clock (Figure 2). Corneal leucoma in the limbal zone from 10 to 2 o'clock was present. Observation of the anterior chamber demonstrated the presence of vitreous body and hyphema presented as a reddish tinge. Also, the presence of traumatic aniridia was revealed in his right eye (Figure 3). Eye fundus examination demonstrated mild partial hemophthalmos and epiretinal membrane in the macula. Fundus photography revealed the presence of an

**Received • Примљено:**

February 5, 2020

**Revised • Ревизија:**

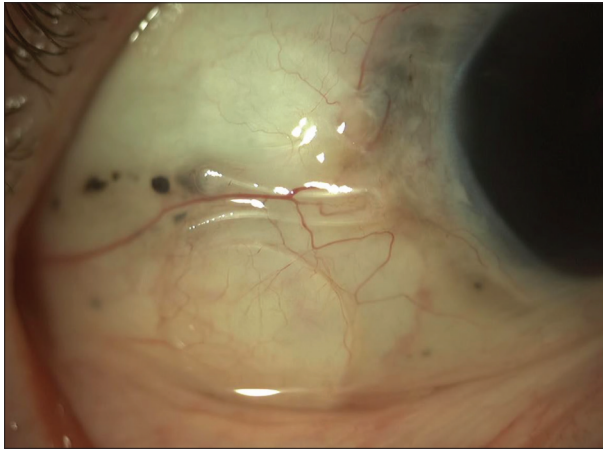
April 18, 2020

**Accepted • Прихваћено:**

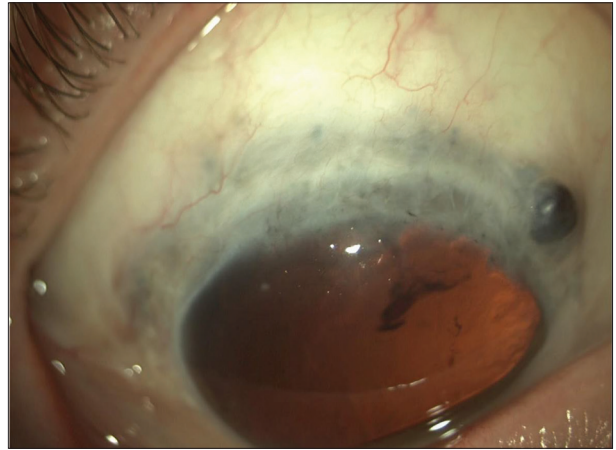
April 19, 2020

**Online first:** April 27, 2020**Correspondence to:**

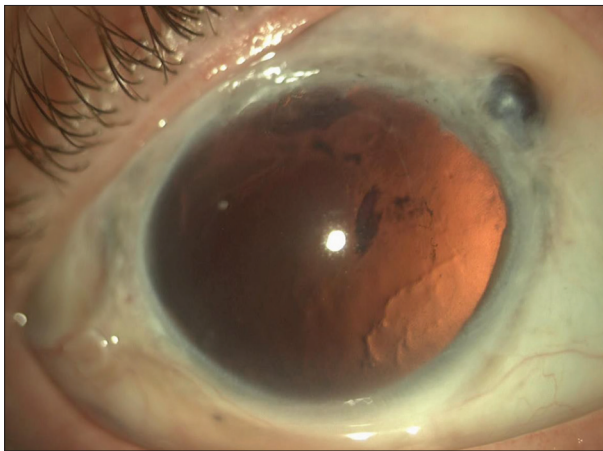
Mladen BILA  
Clinic for Eye Diseases  
Clinical Center of Serbia  
Pasterova 2  
11000 Belgrade, Serbia  
[mladen.bila@gmail.com](mailto:mladen.bila@gmail.com)



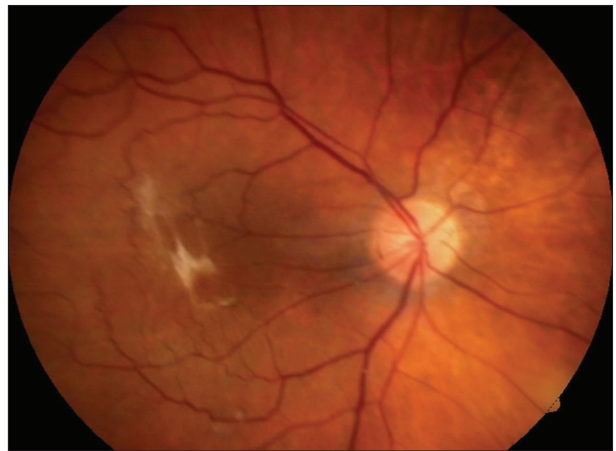**Figure 1.** Dislocated anterior chamber intraocular lens in inferotemporal subconjunctival space



**Figure 2.** Intact and adapted scleral wound with the incarcerated uveal tissue at 2 o'clock



**Figure 3.** Corneal leucoma from 10 to 2 o'clock in the limbal zone, traumatic aniridia, the presence of vitreous body and hyphema in the anterior chamber



**Figure 4.** Fundus photography of an epiretinal membrane in the macula

epiretinal membrane in the macula in his right eye (Figure 4). Examination of the left eye showed the presence of PCIOL and hypertone fundus with no other abnormalities. Dislocated ACIOL in his right eye was operatively extracted from subconjunctival space under local anesthesia.

## DISCUSSION

Pseudophacocoele or dislocation of IOL into the subconjunctival space after blunt ocular trauma is a rare entity and can lead to serious ocular complications [4]. In this case report we describe a rare mechanism of an ACIOL being dislocated into the subconjunctival space after blunt ocular trauma with no evidence of the dehiscence of an old scleral wound which occurred after the rupture of the eye globe following trauma 15 years previously. Scleral wound was adapted and intact, with incarcerated uveal tissue, and covered by conjunctiva. The integrity of the cornea was preserved.

Most commonly, IOL may be extruded from the eye into the subconjunctival space through the surgical wound. The presence of a large surgical wound increases the risk of IOL extrusion after blunt trauma, as presented by Aziz

et al. [5], in which the authors hypothesized that IOL was dislocated into the subconjunctival space through the large corneal wound following the anterior-posterior compression and equatorial expansion of the globe. Kumawat et al. [6] reported a case of post-traumatic pseudophacocoele where no scleral wound dehiscence could be noted. In the reported case, previous scleral wound from cataract surgery may have opened up and led to the dislocation of IOL, but may have sealed spontaneously. We hypothesize that anterior-posterior compression and equatorial expansion of the globe may be a possible mechanism of ACIOL dislocation in our patient. Of note, our patient's visual outcome was surprisingly good considering the fact that he had experienced two serious blunt ocular traumas associated with complications including traumatic aniridia, aphakia, and epiretinal membrane.

We present a case of ACIOL dislocation in the inferotemporal part of the subconjunctival space following blunt ocular trauma with a rare mechanism of ACIOL dislocation since the bulbar wall integrity was preserved. We believe that in our patient previous corneal wound from cataract surgery may have opened up, caused the dislocation of the ACIOL, after which the wound sealed spontaneously as the patient was presented to our clinic a month after the

blunt eye trauma. The presence of epiretinal membrane in the macula, aphakia, and traumatic aniridia may be treated by vitrectomy with membrane peeling accompanied by transconjunctival intrascleral fixation of intraocular lens or by intrascleral insertion of a three-piece lens and silicon iris prosthesis [7, 8, 9].

ACIOL dislocation into the subconjunctival space after blunt ocular trauma should be suspected while examining cases of post-traumatic aphakia.

## REFERENCES

1. Narang P, Agarwal A. Clinical outcomes in traumatic pseudophacocoele: A rare clinical entity. *Indian J Ophthalmol.* 2017;65(12):1465–9.
2. Biedner B, Rothkoff L, Blumenthal M. Subconjunctival dislocation of intraocular lens implant. *Am J Ophthalmol.* 1977;84(2):265–6.
3. Mohan A, Kaur N, Sharma V. Inferior subconjunctival dislocation of posterior chamber intraocular lens after blunt trauma. *Indian J Ophthalmol.* 2017;65(6):521–3.
4. Bawankar PM, Lahane T, Parekh R. Pseudophacocoele. *Indian J Ophthalmol.* 2018;66(8):1191.
5. Aziz S, Asokumaran T, Intan G. Pseudophacocoele following blunt ocular trauma. *Med J Malaysia.* 2011;66(1):64–5.
6. Kumawat D, Sachan A, Sahay P, Kumar V. Delayed presentation of post-traumatic pseudo-phacocoele. *BMJ Case Rep.* 2018;2018:bcr2018226957.
7. Yamane S, Sato S, Maruyama-Inoue M, Kadonosono K. Flanged Intrascleral Intraocular Lens Fixation with Double Needle Technique. *Ophthalmology.* 2017;124(8):1136–42.
8. Yavuzer K, Evcimen Y. Sutureless transconjunctival intrascleral intraocular lens fixation: the modified Yamane technique. *Arq Bras Oftalmol.* 2019;82(5):389–93.
9. Gooi P, Teichman JC, Ahmed II. Sutureless intrascleral fixation of a custom-tailored iris prosthesis with an intraocular lens. *J Cataract Refract Surg.* 2014;40(11):1759–63.

## ACKNOWLEDGMENT

All procedures performed were in accordance with the ethical standards of the institutional and national research committee and with the 1964 Helsinki declaration and its later amendment. Written consent to publish all shown material was obtained from the patient.

**Conflicts of interest:** None declared.

## Редак механизам супконјунктивалне дислокације предњекоморног сочива после контузионе повреде ока

Младен Била, Игор Ковачевић, Горан Дамјановић, Јелена Потих, Јелена Караџић  
Клинички центар Србије, Клиника за очне болести, Београд, Србија

### САЖЕТАК

**Увод** Дислокација интраокуларног сочива као последица трауме ока је стање које захтева хитну хируршку интервенцију. Дислокација артифицијалног сочива у супконјунктивални простор или псеудофакоцела је ретка и неуобичајена последица после тупе повреде ока.

**Приказ болесника** Код болесника старог 76 година је утврђена дислокација артифицијалног предњекоморног сочива у доњетемпорални супконјунктивални простор после контузионе повреде десног ока настале после губитка свести и пада. Код болесника је утврђен очуван интегритет булбуса са добро адаптираном старом раном на склери у коју је инкарциран део увеалног ткива. Болесник је 15

година раније имао трауматску руптуру булбуса на десном оку која је била хируршки збринута и тада му је уграђено артифицијално предњекоморно сочиво.

**Закључак** У раду је приказан редак механизам дислокације артифицијалног предњекоморног сочива у супконјунктивални простор после контузионе повреде ока са очуваним интегритетом рожњаче и добро адаптираном старом склералном раном. У случајевима посттрауматске афакије треба имати у виду и могућност дислокације интраокуларног сочива у супконјунктивални простор.

**Кључне речи:** траума ока; интраокуларно сочиво; супконјунктивална дислокација сочива; руптура булбуса; епиретинална мембрана