



CASE REPORT / ПРИКАЗ БОЛЕСНИКА

Blastic plasmacytoid dendritic cell neoplasm of the uterus

Predrag Đurđević¹, Željko Todorović¹, Danijela Jovanović¹, Ivan Čekerevac¹, Ljiljana Novković¹, Slobodanka Mitrović², Vesna Čemerikić³, Vladimir Otašević⁴, Darko Antić^{4,5}

¹University of Kragujevac, Faculty of Medical Sciences, Department of Internal medicine, Kragujevac, Serbia;

²University of Kragujevac, Faculty of Medical Sciences, Department of Pathology, Kragujevac, Serbia;

³Beo-lab, Belgrade, Serbia;

⁴Clinical Center of Serbia, Clinic for Hematology, Belgrade, Serbia;

⁵University of Belgrade, Faculty of Medicine, Belgrade, Serbia

SUMMARY

Introduction Blastic plasmacytoid dendritic cell neoplasm (BPDCN) is a rare and very aggressive hematological malignancy derived from precursor of the plasmacytoid dendritic cell. We present a case with cervix uteri involvement without skin lesions, which is, to the best of our knowledge, the first case of BPDCN localized in the cervix.

Case outline A 66-year-old previously healthy women initially presented with a four-week history of vaginal bleeding. Gynecologic examination revealed a tumorous bleeding formation on cervix uteri. Except paleness of the skin, physical examination results were normal. Complete blood counts showed anemia and thrombocytopenia. Computed tomography scans showed an expansive tumorous formation at the level of the isthmus and cervix uteri, 60 × 42 mm in size. Cervical biopsy was done and final pathohistological diagnosis was BPDCN. Karyotype analysis results from the bone marrow aspiration specimen demonstrated tetrasomy of chromosome 2 and monosomy of chromosome 16. The patient did not accept treatment and died two months after the initial diagnosis was established.

Conclusion Attributes such as aggressive clinical course of BPDCN, demonstrated unusual localization, infrequency, and the absence of consensus about standard treatment options, demand constructive clinical reasoning and tight cooperation between medical professionals of various fields.

Keywords: BPDCN; hematologic malignancy; aggressive

INTRODUCTION

Blastic plasmacytoid dendritic cell neoplasm (BPDCN) is rare and very aggressive hematological malignancy derived from precursor of the plasmocytoid dendritic cell (pDC) [1]. First it was described in mid-1990s and formerly was known as hematodermic neoplasm and blastic natural killer lymphoma [2, 3, 4]. In 2008, in WHO classification for hematopoietic tumors it was categorized under “acute myeloid leukemia (AML) and related precursor neoplasm” [5]. However, in 2016 WHO myeloid neoplasm and acute leukemia classification, BPDCN is distinguished as a separate entity, in contrast to the previous classification [6]. BPDCN is characterized by high frequency of cutaneous involvement at diagnosis, which can be the only clinical manifestation at the beginning [7]. Bone marrow and lymph nodes involvement is observed in about 50% of cases [8]. A minority of cases initially present with acute leukemia, but leukemia is more often a presentation of the advanced disease [9]. Other infrequent sites of BPDCN localization are the spleen, liver, central nervous system, tonsils, lungs, kidneys, and muscles [7]. We present a case with cervix uteri involvement without skin lesions, which is, to

the best of our knowledge, the first case of BPDCN localized in the cervix.

CASE REPORT

A 66-year-old previously healthy women initially presented with a four-week history of vaginal bleeding. Gynecologic examination showed a tumorous bleeding formation on cervix uteri. Except paleness of the skin, physical examination results were normal. Complete blood counts showed bicytopenia (hemoglobin 10 g/dL, platelet count 29,000/mm³, and white blood cell count 6500/mm³). Routine hemostasis screening test results were normal (international normalized ratio of 1.17, fibrinogen 2.03 g/l, activated partial thromboplastin time 34 seconds, D-dimer 299 μg/l). Lactate dehydrogenase was elevated to 1777 U/L, while other components of the biochemical panel were in reference ranges. Computed tomography (CT) scans revealed expansive tumorous formation in the level of the isthmus and cervix uteri 60 × 42 mm in size, which invaded all the layers of uterus and partly propagated by periuterine adipose tissue (Figure 1). CT also revealed multiple enlargements of iliac,

Received • Примљено:
November 11, 2019

Revised • Ревизија:
April 10, 2020

Accepted • Прихваћено:
May 7, 2020

Online first: May 13, 2020

Correspondence to:

Darko ANTIĆ
Clinical Center of Serbia
Clinic for Hematology,
darko.antic1510976@gmail.com

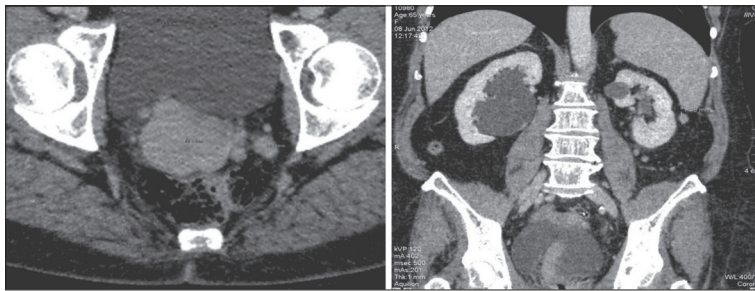


Figure 1. Pelvic computed tomography scans showed a 60 mm mass at the level of the isthmus and cervix uteri, which invaded all the layers of the uterus and partly propagated by periuterine adipose tissue

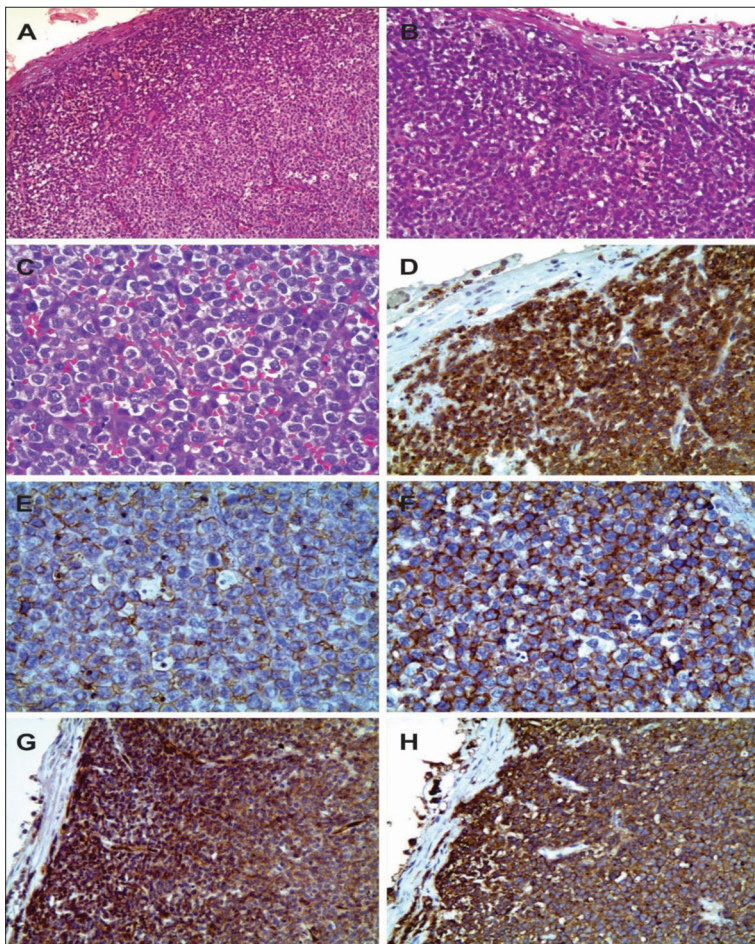


Figure 2. The patient's cervix pathohistology and immunohistochemistry; hematoxylin and eosin staining showed small- to medium-sized blastoid cells diffusely infiltrating predominantly cervical stroma, sparing the epithelium (A, B, C); immunohistochemically, tumor cells were positive for CD4 (D), CD43 (E), CD 56 (F), CD 123 (G), CD45 (H)

retroperitoneal, mediastinal lymph nodes with peritoneal nodular formations.

Cervical biopsy was made and pathohistological examination of specimen showed diffuse infiltration of mucosa with uniform small to medium size cells with blast-like morphology. Tumor cells predominantly occupy the cervical stroma sparing the squamous epithelium. The cells showed large, irregular, oval nuclei with finely granulating chromatin, one or more nucleoli and scant and agranular cytoplasm (Figure 2: A, B, C). Immunohistochemical staining was performed on formalin-fixed, paraffin-embedded

tissue. Tumor cells co-expressed CD4, CD43, CD56, CD123, CD45, CD33 and showed partial positivity for CD68 (Figure 2: D, E, F, G, H). One part of nuclei was also positive on p16 and Oct-2. The cells were negative to vimentin, TdT, CD34, CD117, CK5, CK7, p63, p16, SM actin, synaptophysin, PGP 9.5, chromogranin A, PAX-5, CD79a, CD20, CD10, MUM-1, CD138, CD30, CD15, CD2, CD3, CD5, CD7, CD8, granzyme B, perforin, CD13, MPO, CD14, CD163, bcl-2, bcl-6. The final pathohistological diagnosis was BPDCN.

Bone marrow biopsy showed a slightly hypercellular marrow, with CD4-, CD56-, CD123-positive large blast cells accounting for 5–7% of cellularity. Lymphoid, NK, and myeloid lineage-associated antigens were negative.

Karyotype analysis results from the bone marrow aspiration specimen demonstrated tetrasomy of chromosome 2 and monosomy of chromosome 16 in 12 out of 20 analyzed metaphase cells. (47,XX,+2,+2,-16[12]/46,XX[8]).

Based on clinical, radiographic, and predominantly on histological and immunohistochemical findings of cervical and bone marrow biopsy, the patient was diagnosed with BPDCN, but refused further treatments and died two months after the initial diagnosis was established.

Written consent for publication of this article was obtained from the patient's family member.

DISCUSSION

BPDCN is a very rare and aggressive form of lymphoma-like disease derived from precursor of the pDC. Diagnosis is made based on clinical presentation and histological and immunophenotype features of the involved tissue. In the majority of cases it presents with indolent cutaneous lesions, later followed by dissemination and bone marrow and lymph node involvement [10]. A minority of cases present with fulminant leukemia without skin infiltration. Biopsy of involved tissue usually reveals medium-sized blast cells with irregular nuclei, fine chromatin, and at least one small nucleolus. The cytoplasm is scant and agranular. Because of the overlap with other hematopoietic neoplasms such as myeloid sarcoma/AML, T-cell lymphoblastic leukemia/lymphoma, NK-cell lymphoma/leukemia, extensive immunophenotype analysis is necessary [7, 10, 11]. A recent multicentric study suggested that triple positive CD4+CD56+CD123+ phenotype associated with negativity for lineage-specific markers

such as markers for B cells (CD20, CD79a), T cells (CD3), myeloid cells (myeloperoxidase), and monocytes (CD11c, CD163, lysozyme) is a minimum requirement for defining BPDCN [12].

Our patient presented with a quite unique localization of BPDCN in cervix and isthmus uteri. The origin of tumor cells remained unresolved – whether it was bone marrow or cervical mucosa – because BPDCN has an aggressive clinical presentation that probably affects both sites either consecutively or simultaneously. Histopathological features and triple positive (CD4+CD56+CD123+) phenotype in the absence of specific lineage markers clearly point to BPDCN. However, the diagnosis criteria varied from study to study but majority of them included the following five markers: CD4, CD56, CD123, CD303 (also known as BDCA-2), and TCL1 [10]. Heterogeneity of BPDCN tumor cells is more emphasized by occasional CD56 and/or CD123 surface marker expression [7, 11]. An interesting fact is that blasts with immature plasmacytoid dendritic cell phenotype present typically without extramedullary (e.g. skin) disease; on the other hand, mature blast cell phenotype more frequently displays skin/extramedullary involvement [13]. However, a few myeloid-associated antigens have been seen in a significant number of cases [11]. It is highly important to diagnostically differentiate BPDCN from AML or AML-associated leukemia cutis or myeloid sarcoma. BPDCN is characterized by pDC antigens positivity, CD123 and TCL1, and myeloperoxidase (MPO) negativity, while AML or myeloid sarcoma show MPO positivity and negativity for pDC antigens [14]. In particular, CD68, an antigen typically expressed by granulocytes and histiocytes as well as normal plasmacytoid dendritic cells, is noted in significant number of cases [11]. Another myeloid antigen frequently found in the BPDCN neoplastic cells is CD33, which is the most frequently reported myeloid marker expressed by BPDCN neoplastic cells [11]. Other strong myeloid markers' expression, CD13 and CD117, has also been reported [10]. Neoplastic cells in our case show positivity on both antigens, as well as on CD45 and CD43, which are also often positive on BPDCN cells [10, 11]. Similar triple

positive (CD4+CD56+CD123+) cells with blast morphology were found in bone marrow, indicating bone marrow involvement.

Cytogenetic analysis frequently reveals complex aberrations seen in AML or myelodysplastic syndromes [11]. An interesting fact is that at the time of diagnosis two-thirds of patients show cytogenetic anomalies [10]. Recent studies showed several structural and numerical chromosomal aberrations, as well as gene mutations associated with BPDCN. Most frequent recurrent published genomic losses are as follows: 5q21 or 5q34, 12p13, 13q13-21, 6q23, monosomy 15, and monosomy 9 [10, 11]. As aforementioned, BPDCN cells can carry multiple genetic abnormalities that overlap with the genetic abnormalities of myeloid and lymphoid neoplasms, but tetrasomy of chromosome 2 and monosomy of chromosome 16 described in this case are not one of them and influence of this numerical chromosomal aberration on the etiology and pathogenesis of BPDCN is unknown.

Because of low incidence, there is no consensus for the optimal therapy for BPDCN. The objective of treatment should be the achievement of complete remission after first-line treatment based on protocols for AML or acute lymphoblastic leukemia and, after that, consolidation with allogeneic hematopoietic stem cell transplantation (allo-HSCT). A recent study confirms that the combination of methotrexate and asparaginase for the frontline treatment could be a good solution with a low toxicity profile, even in elderly patients [10, 12]. Having in mind that the CD123 positivity occurs in virtually all cases, using specific BPDCN CD123-directed cytotoxin (tagraxofusp) consisting of recombinant human interleukin-3 fused to a truncated diphtheria toxin could be a reasonable treatment option. Based on the results of a study carried out by Pemmaraju et al. [15], tagraxofusp was approved as the only treatment specifically indicated for untreated or relapsed BPDCN patients with potential development of adverse events as well as included capillary leak syndrome, hepatic dysfunction, and thrombocytopenia [16].

Conflict of interest: None declared.

REFERENCES

- Herling M, Jones D. CD4+/CD56+ hematodermic tumor: the features of an evolving entity and its relationship to dendritic cells. *Am J Clin Pathol.* 2007;127(5):687–700.
- Adachi M, Maeda K, Takekawa M, Hinoda Y, Imai K, Sugiyama S, et al. High expression of CD56 (N-CAM) in a patient with cutaneous CD4-positive lymphoma. *Am J Hematol.* 1994;47(4):278–82.
- Willemze R, Jaffe ES, Burg G, Cerroni L, Berti E, Swerdlow SH, et al. WHO-EORTC classification for cutaneous lymphomas. *Blood.* 2005;105(10):3768–85.
- Chan J, Jaffe E, Ralfkiaer E. Blastic NK-cell lymphoma. In: Jaffe ES, Harris NL, Stein H VJ. *Blastic NK-cell lymphoma.* In: Jaffe ES, Harris NL, Stein H VJ, editor. *World Health Organization Classification of Tumors Pathology & Genetics Tumours of Haematopoietic and Lymphoid Tissues.* London: IARC Press; 2001. p. 22–5.
- Facchetti F, Jones D PT. Blastic plasmacytoid dendritic cell neoplasm. In: Swerdlow S, Campo E HN et al., editor. *WHO Classification of Tumors of Hematopoietic and Lymphoid Tissues.* Lyon, France: IARC; 2008. p. 145–7.
- Arber DA, Orazi A, Hasserjian R, Thiele J, Borowitz MJ, Le Beau MM, et al. The 2016 revision to the World Health Organization classification of myeloid neoplasms and acute leukemia. *Blood.* 2016;127(20):2391–405.
- Riaz W, Zhang L, Horna P, Sokol L. Blastic plasmacytoid dendritic cell neoplasm: update on molecular biology, diagnosis, and therapy. *Cancer Control.* 2014;21(4):279–89.
- Laribi K, Denizon N, Besancon A, Farhi J, Lemaire P, Sandrini J, et al. Blastic Plasmacytoid Dendritic Cell Neoplasm: From Origin of the Cell to Targeted Therapies. *Biol Blood Marrow Transplant.* 2016;22(8):1357–67.
- Zhang YW, Zhong JH, Chen XL, Xiao F, Chen FY. Blastic plasmacytoid dendritic cell neoplasm: A case report and literature review. *Exp Ther Med.* 2016;12(1):319–22.
- Garnache-Ottou F, Vidal C, Biichlé S, Renosi F, Poret E, Pagadoy M, et al. How should we diagnose and treat blastic plasmacytoid dendritic cell neoplasm patients? *Blood Adv.* 2019;3(24):4238–51.
- Shi Y, Wang E. Blastic plasmacytoid dendritic cell neoplasm: a clinicopathologic review. *Arch Pathol Lab Med.* 2014;138(4):564–9.
- Pagano L, Valentini CG, Grammatico S, Pulsoni A. Blastic plasmacytoid dendritic cell neoplasm: diagnostic criteria and therapeutic approaches. *Br J Haematol.* 2016;174(2):188–202.

13. Wang W, Li W, Jia JJ, Zheng Y, Wang H, Gao XM, et al. Blastic plasmacytoid dendritic cell neoplasm: A case report. *Oncol Lett.* 2015;9(3):1388–92.
14. Sullivan JM, Rizzieri DA. Treatment of blastic plasmacytoid dendritic cell neoplasm. *Hematol Am Soc Hematol Educ Progr.* 2016;2016(1):16–23.
15. Pemmaraju N, Lane AA, Sweet KL, Stein AS, Vasu S, Blum W, et al. Tagraxofusp in Blastic Plasmacytoid Dendritic-Cell Neoplasm. *N Engl J Med.* 2019;380(17):1628–37.
16. Haddadin M, Taylor J. Chemotherapy Options for Blastic Plasmacytoid Dendritic Cell Neoplasm. *Hematol Oncol Clin North Am.* 2020;34(3):539–52.

Бластична плазмоцитоидна дендритична неоплазма материце

Предраг Ђурђевић¹, Жељко Тодоровић¹, Данијела Јовановић¹, Иван Чекеревац¹, Љиљана Новковић¹, Слободанка Митровић², Весна Чемериќић³, Владимир Оташевић⁴, Дарко Антић^{4,5}

¹Универзитет у Крагујевцу, Факултет медицинских наука, Одељење интерне медицине, Крагујевац, Србија;

²Универзитет у Крагујевцу, Факултет медицинских наука, Одељење патологије, Крагујевац, Србија;

³„Бео-лаб“, Београд, Србија;

⁴Клинички центар Србије, Клиника за хематологију, Београд, Србија;

⁵Универзитет у Београду, Медицински факултет, Београд, Србија

САЖЕТАК

Увод Бластична плазмоцитоидна дендритична неоплазма (БПДН) представља редак и врло агресиван хематолошки малигнитет који потиче од прекурсора плазмоцитоидне дендритичне ћелије.

Приказујемо случај захватања грлића материце БПДН, без кожних лезија. Према нашим сазнањима, ово је први забележен случај БПДН локализован у грлићу материце.

Приказ болесника Претходно здрава жена, стара 66 година, јавила нам се проблемом крварења из усмине. Гинеколошким прегледом је уочена крварећа туморска формација грлића материце. Осим блеђе пребојености коже, физикални налаз је био уредан. Анализом крви уочене су анемија и тромбоцитопенија. Компјутеризованом томографијом је

радиолошки верификована експанзивна туморска формација грлића материце промера 60 × 42 mm. Потом је урађена биопсија наведене промене, а *pH* налаз је показао да се ради о БПДН. Анализом кариотипа из аспирира ћелија коштане сржи утврђена је тетразомија хромозома 2 и монозомија хромозома 16. Болесница је одбила третман и преминула два месеца после постављања дијагнозе БПДН.

Закључак Агресиван клинички ток БПДН, поменута неуобичајена локализација, ретка болест и недостатак слагања о стандардним терапијским опцијама захтевају конструктивно клиничко резонавање и сарадњу медицинских професионалаца из различитих области.

Кључне речи: БПДН; хематолошки малигнитет; агресиван