

ORIGINAL ARTICLE / ОРИГИНАЛНИ РАД

Foramen of Vesalius – constant or variable foramen

Miloš Maletin¹, Miloš Vuković^{2,3}, Dušica Marić⁴, Dimitrije Jeremić^{1,5}, Kosta Petrović⁶¹Clinic of Urology, Clinical Center of Vojvodina, Novi Sad, Serbia;²University of Novi Sad, Faculty of Medicine, Department of Radiology, Novi Sad, Serbia;³Center for Imaging Diagnostics, Oncology Institute of Vojvodina, Novi Sad, Serbia;⁴University of Novi Sad, Faculty of Medicine, Department of Anatomy, Novi Sad, Serbia;⁵University of Novi Sad, Faculty of Medicine, Department of Surgery, Novi Sad, Serbia;⁶Haukeland University Hospital, Bergen, Norway**SUMMARY**

Introduction/Objective The foramen of Vesalius is a variable foramen located at the base of the skull, anteromedial to the foramen ovale, and lateral to the foramen rotundum. Through this foramen, passes one of the emissary veins, which establishes communication between the cavernous sinus and the pterygoid plexus.

The aim of the study was to determine the incidence of this foramen in adults depending on gender, along with the number of foramina, distributions relative to the side of the skull and diameter of the foramen.

Methods A material used in the study were digital computed tomography (CT) scans of adult paranasal cavities from the archives of the Radiology Center, archived in the PACS software system. We analyzed axial CT sections of 1 mm thickness. The research included 500 subjects (250 males and 250 females).

Results The foramen of Vesalius was present in 67.6% of respondents. In 50.9% cases, the foramen was bilateral and in 49.1% it was unilateral. The average oblique diameter of the foramen in men was 1.75 ± 0.59 mm and in women 1.56 ± 0.48 mm. In 22 subjects (6.51%) the foramina were doubled, and in two (0.60%) they were tripled.

Conclusion There was no statistically significant difference in the incidence of the foramen of Vesalius concerning gender. The mean diameter of the foramen was statistically higher in males. The presence of this foramen is important for neurosurgeons because, during the percutaneous trigeminal rhizotomy, the needle can pass through this foramen, injure the surrounding blood vessels, and lead to intracranial hemorrhage.

Keywords: foramen of Vesalius; CT scans; subjects; mean diameter

INTRODUCTION

There are many foramina on the floor of the middle cranial fossa, which are important because they allow the passage of essential structures such as nerves and blood vessels. The permanent apertures of the sphenoid bone are foramen rotundum, foramen ovale, and foramen spinosum, whereas the foramen of Vesalius (FV) and meningo-orbital (Hyrtl's channel) foramen represent non-permanent foramina [1].

The FV is a small, variable foramen located anteromedial to foramen ovale and posterolateral to foramen rotundum in the middle cranial fossa [2]. The FV (sphenoid emissary foramen) was first described and drawn by the anatomist Andreas Vesalius, after whom the foramen was named. The FV can be unilateral or bilateral. The mean diameter of this foramen in the adult is 1.4–2 mm [3].

The FV transmits one of the emissary veins that connect the cavernous sinus and the pterygoid plexus [4]. Emissary veins play a role in maintaining the balance between intracranial and extracranial pressure. Under physiological conditions, blood flow through the emissary veins is small, but in conditions of increased

intracranial pressure, these veins become an important blood drainage pathway [5]. According to Lang [6], a small nerve (lateral sphenoid nerve) can pass through the FV on the way to the cavernous sinus.

According to Wood-Jones [7], the FV is an indicator of the evolutionary complexation of the cranial venous system of man. The FV does not exist in any primate other than humans.

Anthropological research has shown a significant discrepancy regarding the prevalence of the FV between various authors [8]. Because of this, we have analyzed the digital data of computed tomography (CT) images of adult human skulls to determine the representation of the FV in the human population.

The aim of the study was to determine the incidence of FV in adults. In addition, the goal was to determine the number of foramina, the diameter of the foramina, and the foramen distribution related to the side of the skull.

METHODS

In this retrospective study, we used digital CT scans from adults that were archived in the Picture Archiving and Communications System

Received • Примљено:

January 8, 2020

Revised • Ревизија:

August 17, 2020

Accepted • Прихваћено:

August 18, 2020

Online first: September 9, 2020**Correspondence to:**

Miloš MALETIN
Clinic of urology
Clinical Center of Vojvodina
Hajduk Veljkova 4
21000 Novi Sad, Serbia
milosmaletin1@gmail.com

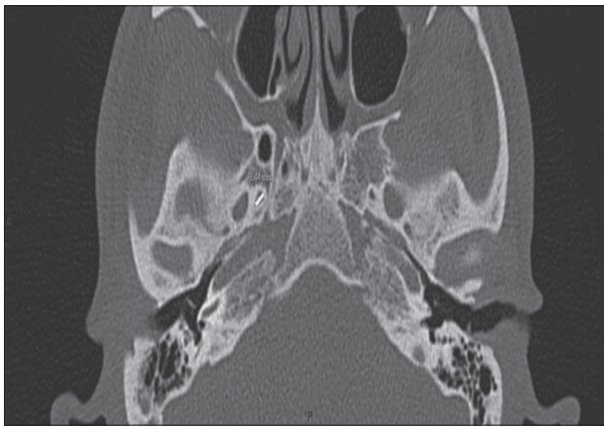


Figure 1. Measurement of the oblique diameter of the foramen in the PACS software (the white line represents foramen of Vesalius diameter)

(PACS) software system of the Radiology Center of the Clinical Center of Vojvodina. The patient's recordings were made as part of a CT scan of the paranasal cavities on the CT scanner Siemens Sensation 64 (Siemens AG, Siemens Healthineers AG, Erlangen, Germany). The study included 500 subjects, of which 250 were male and 250 were female. The study was approved by the Ethics Committee of the Faculty of Medicine, University of Novi Sad.

We analyzed axial CT sections of 1 mm thickness and resolution H60s. The foramen was measured using a digital measuring tool of the PACS software. The largest oblique diameter of the foramen at the axial section was measured (Figure 1).

The images were evaluated for the presence or absence and unilateral or bilateral pattern of FV. Including criteria were localization of the foramen – anteromedial to foramen ovale and posterolateral to foramen rotundum, visibility on both surfaces of the sphenoid bone, and a maximum oblique diameter greater than 1 mm. The cut off value of 1 mm regarding maximum oblique diameter was used to avoid misidentification with a spongy bone of the skull base. Obtained results were presented in figures and tables.

The software program SPSS v.21.0 (IBM SPSS Statistics for Windows, IBM Corp., Armonk, NY, USA) was used for storing and analyzing data. The results of numerical continuous variables were presented as arithmetic mean and standard deviation. The categorical variables were compared by the χ^2 test and the independent samples t-test. The significance level value was set at 0.05.

RESULTS

In the sample of 500 subjects, we analyzed the presence of the FV. The foramen was present in 338 subjects (67.6%) and absent in 162 (32.4%) subjects (Figure 2).

In our sample (Table 1), the FV was observed in 165 (66%) male and 173 (69%) female subjects. During data processing, it was found that there was no statistically significant difference in the FV incidence between male and female skulls ($\chi^2 = 0.584$, $p = 0.444$).

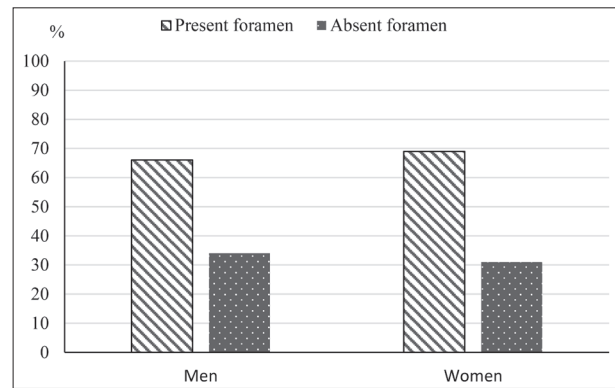


Figure 2. Percentage representation of the foramen of Vesalius

Table 1. Frequency of occurrence of the foramen of Vesalius concerning the sex

| Gender | Present foramen | Absent foramen | Total |
|--------|-----------------|----------------|------------|
| Men | 165 (66%) | 85 (34%) | 250 (100%) |
| Women | 173 (69%) | 77 (31%) | 250 (100%) |

Table 2. Distribution of the presence of foramina concerning the sex

| Sex | Unilateral foramen | Bilateral foramen | Total |
|-------|--------------------|-------------------|-------|
| Men | 71 (43%) | 94 (57%) | 165 |
| Women | 96 (55.5%) | 77 (45.5%) | 173 |
| Total | 166 (49.1%) | 172 (50.9%) | 338 |

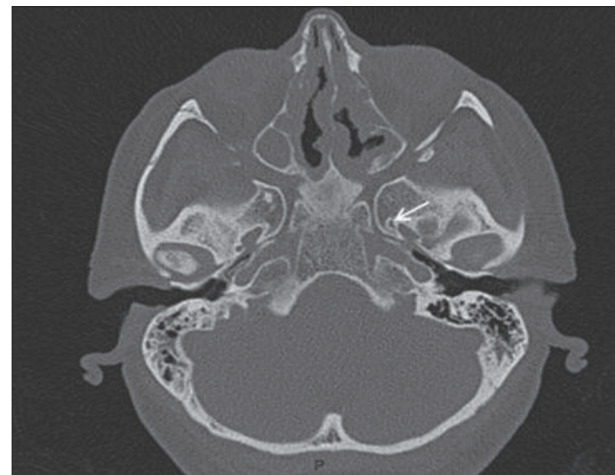


Figure 3. Unilateral foramen (white arrow) on a computed tomography scan

The FV was observed bilaterally in 50.9% cases. The incidence of unilateral foramen in this study was 49.1% of which 46.6% on the right side and 53.4% on the left side of the skull. (Figure 4).

Examining 165 male skulls, a bilateral foramen was present in 57% of cases and unilateral in 43%. In 173 female subjects the FV was bilateral in 77 (45.5%) skulls and in 96 (55.5%) unilateral (Table 2). Bilateral foramen was more common in men and unilateral in women ($\chi^2 = 4.759$, $p = 0.0291$).

In 124 male subjects (47.1%), the foramen was located on the right side and in 139 (52.9%) on the left side of the skull (Figure 5). There was no statistically significant difference ($\chi^2 = 0.0147$, $p = 0.903$) considering the

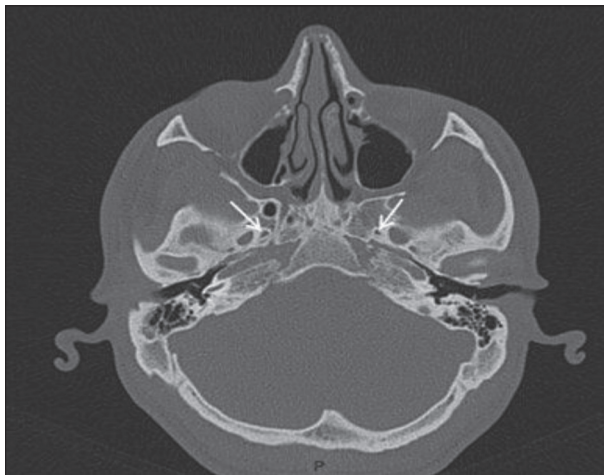


Figure 4. Bilateral foramen (white arrow) on a computed tomography scan

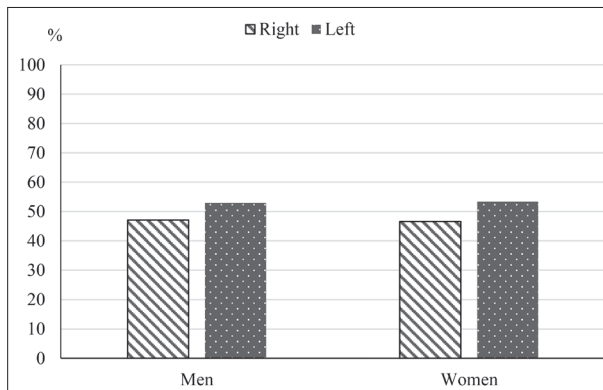


Figure 5. Distribution of foramina concerning the side of the skull and the sex

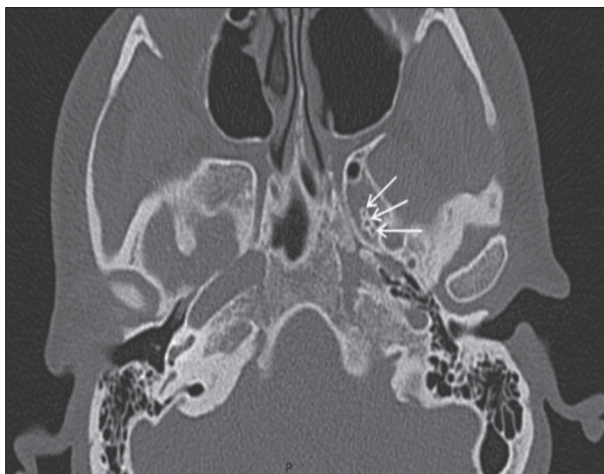


Figure 6. Triple foramen of Vesalius (white arrows) on computed tomography scan

distribution of the FV between the sexes in relation to the side of the skull.

Considering the measurements of the largest oblique diameter of the FV, all foramina were classified into seven groups (Table 3). A total of 226 foramina were 1–1.49 mm in diameter, which is the most commonly recorded foramen size. The largest diameter of the foramen was 4.48 mm and was recorded in one male subject.

Table 3. The maximum oblique diameter of the foramen in millimeters (arranged in groups)

| Diameter of the foramen (mm) | Men | Women | Total |
|------------------------------|-----|-------|-------|
| 1–1.49 | 100 | 126 | 226 |
| 1.5–1.99 | 64 | 77 | 141 |
| 2–2.49 | 45 | 22 | 67 |
| 2.5–2.99 | 22 | 5 | 27 |
| 3–3.99 | 6 | 2 | 8 |
| 3.5–3.99 | 3 | 2 | 5 |
| 4–4.59 | 1 | / | 1 |

Table 4. Percentage of the foramen of Vesalius in different races and peoples

| Author and year | Country | Sample number | Percentage of the foramen of Vesalius |
|----------------------------|---------|----------------|---------------------------------------|
| Boyd (1930) | England | 1500 skulls | 36.5% |
| Lanzieri (1988) | America | 50 CT scans | 64% |
| Ginsberg (1994) | America | 123 CT scans | 80% |
| Kodama (1997) | Japan | 400 skulls | 21.75% |
| Gupta (2005) | India | 35 skulls | 42.90% |
| Ramvalho (2007) | Brazil | 80 skulls | 71.87% |
| Kaplan (2007) | Turkey | 10 skulls | 100% |
| Shaik (2007) | India | 125 skulls | 36% |
| Shinohara (2010) | Brazil | 400 skulls | 33.5% |
| Nirmala (2014) | India | 180 skulls | 50% |
| Raval (2015) | India | 150 skulls | 60% |
| Murli manju (2015) | India | 78 skulls | 37.2% |
| Bayrak (2018) | Turkey | 317 CBCT scans | 28.1% |
| Costa do Nascimento (2018) | Brazil | 194 skulls | 18.55% |
| Nayak (2018) | India | 30 skulls | 30% |
| Leonel (2019) | Brazil | 170 skulls | 45.2% |
| Kaplan (2019) | Turkey | 350 CBCT scans | 41.1% |
| Maletin (2019) | Serbia | 26 skulls | 61.54% |
| Görürgöz (2020) | Turkey | 269 CBCT scans | 73.1% |
| Our current work (2020) | Serbia | 500 CT scans | 67.70% |

CT – computed tomography; CBCT – cone-beam computed tomography

The average value of the oblique diameter of the FV in the whole sample was 1.66 ± 0.55 mm. The average diameter of the foramen on the right side of the skull was 1.62 ± 0.55 mm and the left one was 1.69 ± 0.54 mm. We found no significant difference in the size of the foramen diameter compared to the lateral distribution ($t = 1.015$, $p = 0.856$).

The average diameter of the foramina in the male subjects was 1.75 ± 0.59 mm, while in the female subjects it was 1.56 ± 0.48 mm. The average diameter of the FV was significantly higher in male than female skulls ($t = 15.65$, $p = 0.000$).

During the research, double and triple foramina were noticed in a certain number of respondents. Double foramina represent two foramina, while triple foramina represent three foramina located on the same side of the skull placed next to each other. The presence of a double foramen was

noted in 22 (4.4%) out of 500 analyzed skulls. Twenty-two subjects (5.92%) had double FV on one side of the skull, while one subject (0.3%) had double foramina on both sides of the skull. Triple foramina were found in two female subjects (0.6%), and it was located on the left side in both skulls (Figure 6).

DISCUSSION

In this study, which included digital data of 500 CT scans of adults, the presence of the FV was detected in 67.7% of cases. These results are similar with those reported by Görürgöz et al. [4] with 73.1% presence, Maletin et al. [9] in which FV was present in 61.54% of dry adult skulls, and with the study of Lanzieri et al. [10], Raval et al. [11], where the FV was present in 64% and 60% of the respondents. In their research, Shinohara et al. [12] and Shaik et al. [13] state that the foramen representation is 33.75% and 36%, respectively, which is less than the results of our study. According to most authors, the incidence of the FV is lower (Table 4) [3, 12–20]. There is a significant discrepancy in the incidence of the FV between various authors. This may be explained by the different number of examined subjects, ethnicity, and differences in FV identification methodology which can be the subject of future research.

In our sample, there is approximately equal representation of bilateral and unilateral foramina. This finding correlates with the results of Shinohara [12], Gupta [20], and Nirmala [21]. Based on our data we can disagree with the results of the previous studies, which reported that the incidence of the bilateral foramen is higher than unilateral foramen in adult skulls [17, 22, 23].

Regarding the incidence of the FV, we observed no remarkable differences in the ratio between the male and the female subjects (Table 1). This result is consistent with the findings of Kodama et al. [22] whose research included 400 adult human skulls. Unlike our results, some authors reported that the foramen is more common in female subjects [24]. In a study by Chaisuksunt et al. [25] the FV is more likely to occur in males than in females, which can be explained by the higher number of male subjects included in the study (246 males and 131 females).

Analyzing data, we found that bilateral FV was significantly more common in males and unilateral in females. Kodama et al. [22] did not find a difference in the distribution of unilateral and bilateral foramina concerning gender, while other studies did not address this issue.

According to Andreas Vesalius's book titled *De humani corporis fabrica libri septem* [2], there is no remarkable difference between the left and right side regarding the lateral distribution of the FV. The results of our study correlate with the citation of the mentioned well-known anatomist, unlike Rossi et al. [24] which pointed out that the FV is more frequent on the right side of the skull, while in some cases it was more common on the left side [18].

Based on the results of our study, the mean diameter of the FV on the right side was 1.62 ± 0.55 mm and on the left side was 1.69 ± 0.54 mm. These data are similar

to the results of Kodama et al. which state that the mean foramen diameter on the left is 1.59 ± 0.94 mm, while on the right it is 1.46 ± 1.04 mm [22], as well as in the study of Görürgöz et al. [4] with right side FV diameter 1.75 ± 1.33 mm and 1.75 ± 1.2 mm on the left side. In the results of the study by Shinohara et al. [12] the average foramen size on the right side is 0.67 ± 0.28 mm and on the left side is 0.76 ± 0.39 mm, which is smaller than the results of our study. Unlike the mentioned studies, Bayrak et al. [16] stated that the mean diameter on the right side is 2.66 mm, and 2.82 on the left side, which is bigger than the results of our study. To the best of our knowledge, there are no possible explanations for the difference in the diameter of the FV in different authors in contemporary literature. The discrepancy in the data of our study and other reports regarding the mean diameter of FV may be the result of a different methodology in defining the FV. Due to the potential false-positive findings, foramina with a diameter smaller than 1 mm were excluded from our study.

In male subjects, the average foramen diameter is 1.75 ± 0.59 mm, while in female subjects it is 1.56 ± 0.48 mm ($t = 15.65$, $p = 0.000$). After statistical data processing, it was found that the size of the foramen diameter was larger in men than in women, whereas in the study by Prakash and Viveka [26] the average diameter of the foramen in males is significantly lower than females. Görürgöz et al. [4] did not find a significant difference in the FV diameter between genders.

The clinical significance of the FV lies in the fact that it provides passage to the emissary vein. Through the FV, septic thrombus can reach from extracranial veins to the cavernous sinus causing cavernous sinus thrombosis. Thrombosis of the cavernous sinus is a very serious condition that can be lethal in up to 30% of the cases or cause serious complications such as ophthalmoplegia, blindness, or cerebrovascular insult. The most likely cause of this pathological condition is an infection within the orbit, paranasal sinuses, or tissue of the upper half of the face [27]. In addition, the FV also has surgical significance. One of the treatment options for trigeminal neuralgia is radiofrequency rhizotomy. During this procedure, while approaching the trigeminal nerve, a needle is inserted intracranially through foramen ovale. When reaching the foramen ovale, the needle may erroneously pass through the FV leading to cavernous sinus puncture and intracranial hemorrhage, which could be life-threatening conditions [28, 29].

Since the FV is not as rare as previously thought, the presence of an excess number of foramina should be suspected during the diagnostic examination of the middle cranial fossa [30]. The presence of the FV, its localization, and diameter are important information for anatomists, radiologists, maxillofacial surgeons, and neurosurgeons.

CONCLUSION

The FV is inconsistent foramen of the base of the skull. The incidence of FV (67.7%) in this study is considerably

higher than in most previous studies, so FV is not that uncommon finding as previously thought. Regarding the gender incidence of the FV, there is no statistically significant difference between males and females. There is no remarkable difference in the lateral distribution of the FV. The mean diameter of the FV is significantly higher in men than women. We found an interesting fact that in addition to one FV, there may be double and triple foramina, which were found in 22 subjects (6.5%) and two subjects (0.6%) respectively. The exact cause of variations

observed in the current study is difficult to determine but these might be due to genetic, nutritional, environmental, or other unknown factors.

Detailed knowledge of the anatomy of the base of the skull and its varieties, including the FV, is very important to the maxillofacial surgeons and neurosurgeons for performing successful and safe microsurgical procedures.

Conflict of interest: None declared.

REFERENCES

1. Standring S. Gray's Anatomy, The Anatomical Basis of Clinical Practice. In external skull. 40th edition. London: Churchill Livingstone Elsevier; 2008. p. 424–25, 610–11.
2. Vesalius A. De humani corporis fabrica libri septem. Bruxelles 1543.
3. Boyd GI. The emissary foramina of the cranium in man and anthropoids. *J Anat.* 1930;65(Pt 1):108–21.
4. Görürgöz C, Paksoy C. Morphology and morphometry of the foramen venosum: a radiographic study of CBCT images and literature review. *Surg Radiol Anat.* 2020;42(7):779–90.
5. Reis CV, Deshmukh V, Zabramski JM, Crusius M, Desmuskh P, Spetzler RF, et al. Anatomy of the mastoid emissary vein and venous system of the posterior neck region: neurosurgical implications. *Neurosurg.* 2007;61(5 Suppl 2):193–201.
6. Lang J. Clinical Anatomy of the Head, Neurocranium, Orbit and Craniocervical Region. Berlin: Springer-Verlag, 1883.
7. Wood-Jones F. The non-metrical morphological characteristics of the skull as criteria for racial diagnosis: part I: general discussion of the morphological characters applied in racial diagnosis. *J Anat.* 1931;65(Pt 2):179–95.
8. Shapiro R, Robinson F. The foramina of the middle cranial fossa: a phylogenetic, anatomic and pathologic study. *Am J Roentgenol Radium Ther Nucl Med.* 1967;101(4):779–94.
9. Maletin M, Vuković M, Sekulić M, Drljević Todić V. Morphological characteristics of foramen vesalius in dry adult human skulls. *Medicinski pregljed.* 2019;72(11–12):357–61.
10. Lanzieri CF, Duchesneau PM, Rosenbloom SA, Smith AS, Rosenbaum AE. The significance of asymmetry of the foramen of Vesalius. *AJNR Am J Neuroradiol.* 1988;9(6):1201–4.
11. Raval B, Singh PR, Rajguru J. A morphologic and morphometric study of foramen vesalius in dry adult human skulls of gujarat region. *J Clin Diagn Res.* 2015;9(2):AC04–7.
12. Shinohara AL, de Souza Melo CG, Silveira EM, Lauris JR, Andreo JC, De Castro Rodrigues A. Incidence, morphology and morphometry of the foramen Vesalius: complementary study for a safer planning and execution of the trigeminal rhizotomy technique. *Surg Radiol Anat.* 2010;32(2):159–64.
13. Shaik HS, Shepur MP, Desai SD, Thomas ST, Maavishettar GF, Haseena S. Study of foramen vesalius in South Indian skulls. *Indian J Med Healthcare.* 2012;1(1):22–4.
14. Leonel LCPC, Peris-Celda M, de Sousa SDG, Haetinger RG, Liberti EA. The sphenoidal emissary foramen and the emissary vein: Anatomy and clinical relevance. *Clin Anat.* 2020;33(5):767–81.
15. Murlimanju BV, Reddy GR, Latha VP, Vasudha VS, Rao CP, Mangala MP, et al. Foramen of vesalius: prevalence, morphology, embryological basis and clinical implications. *Journal of Surgical Academia.* 2015;5(1):24–8.
16. Bayrak S, Kurşun-Çakmak EŞ, Atakan C, Orhan K. Anatomic study on sphenoidal emissary foramen by using cone-beam computed tomography. *J Craniofac Surg.* 2018;29(5):e477–80.
17. Nayak G, Pradhan S, Panda SK, Chinara PK. Anatomical study of foramen vesalius. *J Evol Med Dent Sci.* 2018;7(35):3847–50.
18. Costa do Nascimento JJ, da Silva Neto EJ, de Oliveira Ribeiro EC, de Almeida Holanda MM, Valença MM, Oliveira Gomes LD, et al. Foramen Venosum in macerated skulls from the North-East of Brazil: morphometric study. *Eur J Anat.* 2018;22(1):17–22.
19. Akkoca Kaplan F, Bayrakdar İŞ, Bilgir E. Incidence of anomalous canals in the base of the skull: a retrospective radio-anatomical study using cone-beam computed tomography. *Surg Radiol Anat.* 2020;42(2):171–7.
20. Gupta N, Ray B, Ghosh S. Anatomic characteristics of foramen vesalius. *Kathmandu Univ Med J (KUMJ).* 2005;3(2):155–8.
21. Nirmala D, Hema N. Study of emissary sphenoidal foramen and its clinical implications. *Journal of Evidence Based Medicine and Healthcare.* 2014;1(4):175–9.
22. Kodama K, Inoue K, Nagashima M, Matsumura G, Watanabe S, Kodama G. Studies on the foramen vesalius in the Japanese juvenile and adult skulls. *Hokkaido Igaku Zasshi.* 1997;72(6):667–74.
23. Kale A, Aksu F, Oztuk A, Gurses IA, Gayretli O, Zeybek FG, et al. Foramen of vesalius. *Saudi Med J.* 2009;30(1):56–9.
24. Rossi AC, Freire AR, Prado FB, Caria PHF, Botacin PR. Morphological characteristics of foramen Vesalius and its relationship with clinical implication. *J Morphol Sci.* 2010;27(1):26–9.
25. Chaisuksunt V, Kwathai L, Namonta K, Rungruang T, Apinhasmit W, Chompoopong S. Occurrence of the foramen of Vesalius and its morphometry relevant to clinical consideration. *ScientificWorldJournal.* 2012;2012:817454.
26. Prakash KG, Viveka S. Morphometry and variations of foramen vesalius: significance in surgical approach to mandibular nerve. *Int J Anat Res.* 2015;3(4):1737–40.
27. Freire AR, Rossi AC, Souza de Oliveria VC, Prado F, Caria PHF, Botacin PR. Emissary foramina of the human skull: anatomical characteristics and its relations with clinical neurosurgery. *Int J Morphol.* 2013;31(1):287–92.
28. Sindou M, Keravel Y, Abdennebi B, Szapiro J. Neurosurgical treatment of trigeminal neuralgia. Direct approach or percutaneous method?. *Neurochirurgie.* 1987;33(2):89–111.
29. Sweet WH, Poletti CE. Complications of percutaneous rhizotomy and microvascular decompression operations for facial pain. In: Schmideck HH, Sweet WH, editors. *Operative neurosurgical techniques: indication, methods and results.* Orlando: Grune and Stratton Inc; 1988. p. 1139–45.
30. Ginsberg LE, Pruett SW, Chen MY, Elster AD. Skull-base foramina of the middle cranial fossa: reassessment of normal variation with high-resolution CT. *AJNR Am J Neuroradiol.* 1994;15(2):283–91.

Везалијусов отвор – сталан или несталан отвор

Милош Малетин¹, Милош Вуковић^{2,3}, Душица Марић⁴, Димитрије Јеремић^{1,5}, Коста Петровић⁶

¹Клинички центар Војводине, Клиника за урологију, Нови Сад, Србија;

²Универзитет у Новом Саду, Медицински факултет, Катедра за радиологију, Нови Сад, Србија;

³Институт за онкологију Војводине, Центар за имџинг дијагностику, Нови Сад, Србија;

⁴Универзитет у Новом Саду, Медицински факултет, Катедра за анатомију, Нови Сад, Србија;

⁵Универзитет у Новом Саду, Медицински факултет, Катедра за хирургију, Нови Сад, Србија;

⁶Универзитетска болница Хаукеланд, Берген, Норвешка

САЖЕТАК

Увод/Циљ Везалијусов отвор је варијабилан отвор који се налази на бази лобање, испред и унутра од овалног отвора, а споља и иза округлог отвора. Кроз Везалијусов отвор пролази једна од емисарних вена која успоставља комуникацију између кавернозног синуса и криластог венског сплета.

Циљ истраживања био је утврђивање учесталости Везалијусовог отвора код одраслих особа у зависности од пола, као и утврђивање броја отвора, дистрибуција у односу на страну лобање и одређивање дијаметра отвора.

Методе Као материјал коришћени су дигитални подаци снимка параназалних шупљина одраслих особа урађених компјутерском томографијом из архивског материјала Центра за радиологију, који су архивирани у софтверском систему PACS. Анализирани су аксијални пресеци КТ дебљине 1 mm. Истраживање је обухватило 500 испитаника (250 мушког и 250 женског пола).

Резултати Везалијусов отвор је био присутан код 67,6% испитаника. У 50,9% случајева отвор је био билатералан, а у 49,1% случајева унилатералан. Просечни коси дијаметар отвора код мушкараца износи $1,75 \pm 0,59$ mm, а код жена $1,56 \pm 0,48$ mm. Код 22 испитаника (6,51%) уочени су удвојени, а код два испитаника (0,60%) утројени отвори.

Закључак Нема статистички значајне разлике у учесталости јављања Везалијусовог отвора у односу на пол. Просечни измерени дијаметар Везалијусовог отвора је статистички био већи код мушкараца. Присуство Везалијусовог отвора представља важан податак за неурохирурге, јер током перкутане тригеминалне ризотомије игла може да прође кроз овај отвор, повреди околне крвне судове и доведе до интракранијалне хеморагије.

Кључне речи: Везалијусов отвор; снимци компјутеризованом томографијом; испитаници; просечни дијаметар