

Supernumerary Premolars - A Case Report

SUMMARY

Supernumerary teeth are defined as any teeth or tooth substance in excess of the normal dental formula. Their incidence is approximately 1 per 110 children. Premolars account for approximately 8.4% of all supernumerary teeth. The occurrence of multiple supernumeraries in the absence of an associated systemic condition (as in our case) is nevertheless a much rarer phenomenon with only a few examples reported in the literature. Most associated problems are due to their potential to interfere with the normal occlusal development or orthodontic mechanics. Decision of their extraction vs. retention and periodic monitoring should include the potential risk of leaving them in place weighed against the possible complications of surgical removal.

A 30-year-old non-syndromal Caucasian male patient was referred to the Orthodontic private practice being concerned about the appearance of his supernumerary premolar's cusp within the mouth cavity between #35 and #36. Intraoral assessment showed presence of spaces between lower teeth, especially between #33 and #34, and supra-eruption of #47 due to the long absence of its antagonists. Radiographic assessment showed a satisfactory degree of root development of the supernumerary (beyond two thirds). Treatment aimed at mandibular space closure, submergence of #47 and occlusal detailing.

Keywords: Supernumerary Teeth, premolars

S. Al-Zuriqat, T. Georgiou, E. Markovitsi

Dental School of the Aristotle University of Thessaloniki, Greece

CASE REPORT (CR)

Balk J Stom, 2009; 13:172-176

Introduction

Supernumerary teeth may be defined as any teeth or tooth substance in excess of the normal dental formula, i.e. of 20 deciduous and 32 permanent teeth, and they may be encountered in various regions of the dental arches^{3,5,15}. The incidence of supernumerary teeth among the general population is approximately 1 in every 110 children, and the ratio of prevalence in the maxilla to mandible is 8.2 to 1^{19-21,23,24}.

The most common supernumerary teeth, listed in order of frequency are the:

1. maxillary midline supernumerary teeth (mesiodentes);
2. maxillary fourth molars;
3. maxillary paramolars (rudimentary supernumeraries that develop buccally or lingually to the maxillary molars);

4. mandibular premolars;
5. maxillary lateral incisors;
6. mandibular fourth molars;
7. maxillary premolars^{3,13,19,21}.

Concerning premolars, they account for approximately 8.4% of all supernumerary teeth, with mandibular teeth constituting 6.6% of the total. This is in variance to the observed maxilla to mandible ratio mentioned above^{1,12,18-20,23}. The wide variation in percentages reported can be attributed to variations in size of study, age, range, racial composition and methods of detection¹⁸.

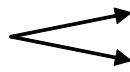The prevalence of supernumerary teeth in the permanent dentition ranges between 0.1-3.8% while in the primary dentition between 0.3-0.8%^{3,5,13,16,18}. While there is no sex predilection for supernumerary teeth in the primary dentition, males are affected twice as often as females in the permanent dentition^{1,5,16,18}.

The incidence of supernumeraries in general population, mentioned above, refers to studies concerning Caucasian populations, whereas other populations (Mongoloid 2.3-3.4%, Asian) seem to be more affected^{12,15,23}. Single supernumeraries occur in 76-86% of cases,

double supernumeraries in 12-23% of cases and multiple supernumeraries in less than 1% of cases.¹⁵

While the occurrence of supernumerary teeth is a rare phenomenon, it is often found in association with a number of syndromes, developmental, and systemic conditions^{5,12,15}, such as:

1. Cleidocranial dysplasia (35% anterior upper and lower regions, and 27% for the upper and lower premolar regions)^{3,5,12,13,15,16,18,19};
2. Cleft lip-palate (28% especially in the anterior region)^{3,5,15,16,18,19};
3. Gardner's syndrome (21%)^{3,12,13,15,16,18,24};
4. Oral-facial-digital syndromes, such as orodigitofacial dysostosis^{9,16};
5. Hallerman-Streiff syndrome¹⁶;
6. Down's syndrome⁹;
7. Crouzon's disease⁹;
8. Robinow syndrome
9. Fabry-Anderson syndrome⁶;
10. Ehlers-Danlos syndrome ž⁶
11. Facial fistulas⁶;
12. Occulocerebrocutaneous syndrome²;
13. Chondroectodermal syndrome²²;
14. Partial anodontia⁴;
15. Megadontia (supernumerary teeth in siblings)¹⁷;
16. Hereditary gingival fibromatosis-hearing deficiencies-hypertelorism¹⁴;
17. Nance-Horan syndrome⁷;
18. Steroid dehydrogenase deficiency⁷.



Dominant form: 10.3% supernumerary teeth

Recessive form: no supernumerary teeth¹¹

On the other hand, the occurrence of multiple supernumerary teeth in the absence of an associated systemic condition or syndrome is a much rarer phenomenon, and only a few examples of non-syndromal multiple supernumerary teeth have been reported in the literature^{15,12}. Reviewing most of the cases published in the English language, Yusof found that when non-syndromal multiple supernumeraries are present, the most common site affected is the mandibular premolar region, followed by the molar and the anterior regions, respectively^{15,18,23}.

Although the exact etiology of supernumerary teeth remains unclear, several hypotheses have been proposed^{1,3,5,12,15,17,19}. The phylogenetic theory of atavism (evolutionary throwback) is one of the first speculated pathways suggested by some authors to explain their development, but this theory has faced serious doubts^{3,5}.

The dichotomy of a tooth bud has also been suggested as a possible etiological factor in the development of supernumerary teeth. A complete, equal split of the bud would give rise to a "supplemental" supernumerary tooth, while an unequal split would result in one normal tooth and one smaller tooth^{3,5,16,19}.

Most literature supports the dental lamina theory^{1,5,15,19}. This theory proposes that supernumeraries are formed as a result of localized, independent and conditional hyperactivity of the dental lamina, or due to the proliferation of dental lamina remnants or

cell rests^{6,12,18}. Findings in animal studies support that proliferation of epithelial remnants, mainly from Hertwig's root sheath, may be stimulated by trauma, as there is possibly a cause-and-effect relationship between jaw fractures and supernumerary tooth formation¹⁹.

Heredity also seems to play an important role as supernumerary teeth are more likely to be present in patients whose relatives possessed supernumeraries, although there are no satisfactory explanations for the mode of inheritance which does not follow the simple Mendelian pattern^{3,12,15,16,18}. An autosomal dominant trait has been suggested, though the sex predilection of males over females has influenced several authors to indicate the possibility of a sex-linked inheritance^{3,19}. To be more precise, the combination of environmental factors and genetics may lead to hyperactivity of the dental lamina and the cascade of events which follow^{3,5}.

A number of different types of supernumerary teeth exist and are classified according to their morphological features³:

- Rudimentary, which are either conical (most common), tuberculate or molariform;
- Supplemental, which resemble that tooth of the normal series with which they are associated. These are usually smaller in size and are found either as primary supernumeraries or as permanent supernumerary premolars^{3,13,19,23}.

Supernumerary maxillary premolars have a variable morphology, but are predominantly conical. Those in the mandible tend to have the shape of a normal crown^{10,18}.

Most problems associated with supernumeraries are because of their potential to interfere with normal occlusal development or with orthodontic mechanics, such as:-

- 1) Abnormal diastema or premature space closure^{5,15,18,19};
- 2) Displacement or rotation of permanent tooth^{5,12,15,16,18,19,21};
- 3) Impaction/ failure of eruption^{5,15,18,19,21,23,24};
- 4) Fusions with normal teeth¹³;
- 5) Abnormal eruption sequence, i.e: retained deciduous teeth and delayed eruption of permanent teeth^{15,16,18,19,24};
- 6) Impediment to orthodontic alignment of permanent teeth, such as a compromised space closure^{5,15,18,19}.

Other complications include:

- Dilacerations, delayed or abnormal root development of the permanent teeth^{5,19};
- Pathologic resorption of adjacent tooth^{10,12,13,15,18,24};
- Eruption into the nasal cavity or the maxillary sinus^{5,15,18};
- Cystic formation^{5,10,12,13,15,18,21,23,24};
- Compromised alveolar bone grafting, implant site preparation or implant placement⁵;
- Increased incidence in caries of adjacent teeth²⁴;
- Gingival inflammation and periodontal abscesses²⁴;
- Spontaneous eruption⁵;
- When they erupt, aesthetically undesirable¹⁶.

A decision regarding the appropriate treatment for patients diagnosed with supernumerary teeth should be carefully made¹². The potential risks of leaving the teeth in place must be weighed against the possible complications of surgical removal¹². The generally recommended course of treatment is extraction, unless a good reason for retention can be found²⁴. Such reasons exist when:

- 1) The surgery would be unjustifiably hazardous to adjacent structures^{3,15,23,24};
- 2) The tooth could be used for orthodontic reasons^{19,24};
- 3) It is contraindicated by the patient's medical status¹⁸;
- 4) The patient is not willing to undergo a surgical procedure for a condition she/he was unaware of and that is not causing an immediate problem^{19,24}.

In the case of supernumerary premolars, surgical removal is indicated if any of the previously mentioned complications are found or anticipated during radiographic or clinical examination.¹⁹ Bodin et al. reported that only 2% of supernumeraries in the premolar region exhibited any pathological change, and indicated that these teeth should be left untreated rather than risk surgical damage.^{3,19} Although, in general terms, extraction of supernumerary premolars has been the recommended treatment choice, the timing of surgical removal appears to be controversial.¹⁹

A. An early intervention. This is suggested when the supernumerary is causing problems such as prevention

of eruption or malposition of permanent teeth. Early diagnosis and treatment also permits an interceptive orthodontic approach and correction of arch crowding.

B. A later intervention. This could take place: i) prior to orthodontic treatment, ii) in conjunction with extraction of third molars in an attempt to minimize surgical trauma, iii) after the full permanent dentition has developed, as a late treatment of the overall condition (late extraction of normal deciduous, permanent, supernumerary premolars, as part of the orthodontic treatment plan) in one session reduces treatment time, as well as damage to adjacent structures and psychological trauma to the patient, and, iv) as suggested by most authors, after further development of their roots allows for uncomplicated surgery with less damage to adjacent structures.¹⁹

It should be noted that the vicinity of the mental nerve to the area poses the risk of surgical trauma which may lead to mental paraesthesia or anaesthesia^{12,23}. Regardless of whether the supernumerary is left in situ or extracted, a regular clinical and radiographic monitoring program should be implemented as there is an increased risk of further supernumerary teeth developing.¹²

Case Report

A 30-year-old non-syndromal Caucasian male was referred to the Orthodontic private practice after initially visiting the Dental Surgery Clinic of the Aristotle University of Thessaloniki. His main concern was the appearance of the cusp of his supernumerary premolar within the mouth cavity, which caused irritation and food impaction in the area between #35 and #36 (Figs. 1 and 2). He also asked for prosthetic rehabilitation of the area #15-#18. The patient stated that at about 10 years of age he had gone surgical extraction of "some" teeth in the premaxillary region. Nevertheless, his dental records could not be retrieved. It should be noted that there is a possible family history of supernumeraries. The patient's mother reported extraction of supernumeraries in the upper right quadrant when she was about 13 years of age.

Clinical findings were as follows:

Extra-oral assessment - average lower face height, competent lips at rest, acceptable facial profile;

Intra-oral assessment - acceptable overjet and overbite, right Angle class I and left Angle class II (Canine relationship - missing #16), diastema between #33 and #34, supraeruption of #47, mesial inclination of #48;

Radiographic assessment - the pre-treatment OPG showed an acceptable degree of root development of the supernumerary tooth (beyond two thirds), the supernumerary was not rudimentary (smaller, as found usually) but of normal size, a lower level of the right maxillary sinus floor in comparison to the left

side, a radiolucency beneath the crown portion of the supernumerary and at the level of junction between middle and apical thirds of the root of the second premolar. The progress OPG showed angular bone loss in the area described above (between the second premolar and the supernumerary) after the supernumerary has been brought to occlusion (Fig. 3).

The treatment aimed mainly at the closure of spaces in the mandible, this being the reason for maintaining the supernumerary tooth. It also aimed at the submergence of #47 (to facilitate the prosthetic rehabilitation of region #15-#18), and finally, at detailing the occlusion.

The treatment plan included the use of lower fixed appliances and elastic chain for space closure and detailing of occlusion, and the use of an Essix splint made

by vacuum formed thermoplastic material for occlusal stabilization.

Unfortunately, due to poor cooperation of the patient, there was a reassessment of the initial treatment goals concerning the submergence of #47 for prosthetic reasons. After a prolonged treatment period of about 2.5 years, due to poor patient cooperation, the mandibular dentition was well aligned and the supernumerary was brought into occlusion and into the line of the arch. All spaces were closed and a good relationship was obtained between upper and lower arches. Facial aesthetics were preserved (Fig. 4). Concerning the periodontal changes observed in the progress OPG, and after clinical examination, the patient has undergone initial periodontal treatment and will be periodically followed up.

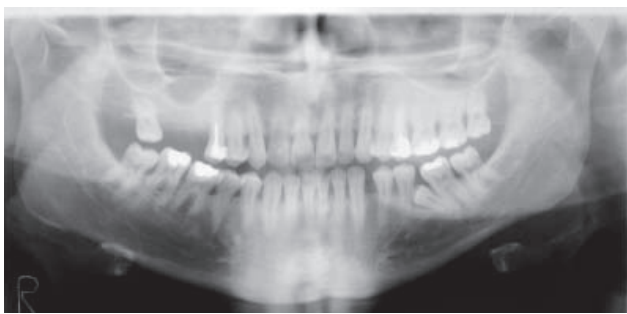


Figure 1. Pre-treatment OPG shows the impacted supernumerary premolar in the area between teeth #35 and #36

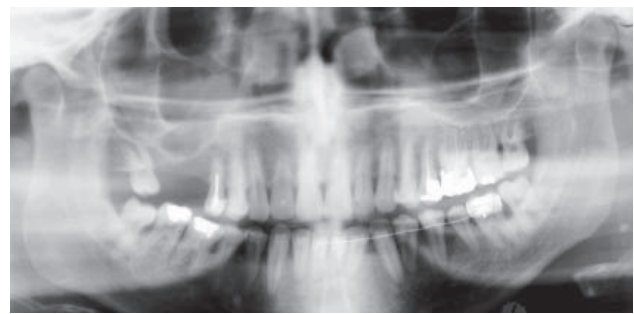

Figure 3. Progress OPG shows the supernumerary premolar brought to occlusion

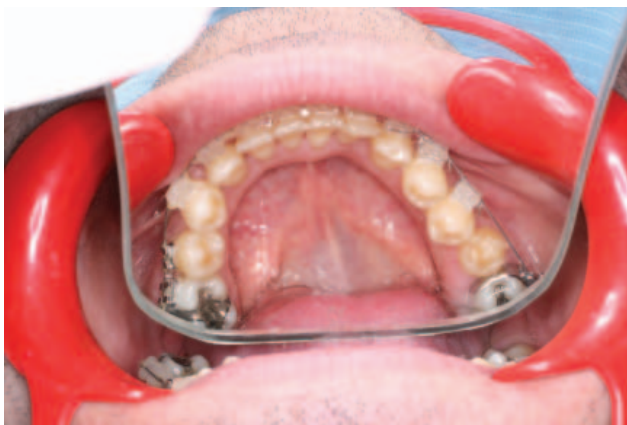

Figure 2. Occlusal view of the mandibular arch

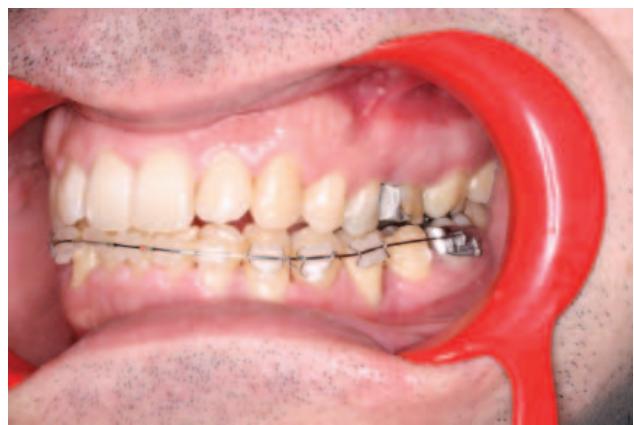

Figure 4. Intra-oral photograph in centric, showing the supernumerary premolar in occlusion

Discussion

Reactivation of the incompletely resorbed dental lamina takes place at around the time of crown completion of normal teeth¹⁹. This explains why supernumeraries tend to begin their development later than the corresponding teeth of the normal series¹⁰. Concerning supernumerary premolars, several authors support that these develop

approximately 7-11 years after the development of the normal teeth³.

However, it is difficult to determine when exactly a supernumerary tooth starts to form due to their lingual position (usually), making detection on routine radiographs difficult³. Careful radiographic follow up should be conducted in case any unusual radiolucencies are detected during routine radiographic screening¹⁰.

The interval between progress x-rays could be 1, 2 or 5 years, as suggested by various authors^{10,19}. It should be noted that since supernumerary premolars commonly occur in several regions of the same mouth, the finding of 1 indicates radiographic examination of the remaining premolar regions¹⁹.

Recurrence of supernumerary teeth after surgical extraction has also been reported. It is possible that the crypts of supernumerary premolars could have been present earlier, but were not detected in the previous radiographs. Periapical radiographs may also miss some of the more apically developing supernumerary premolars¹⁹. Recurrence of supernumerary premolars after surgical removal was reported in 8% of the total sample¹⁹. Therefore, even after supernumerary premolars are extracted, a long-term observation is advised as these may redevelop up to 5 years after initial extraction^{19,23}. Patients with a previous history of supernumerary teeth in the anterior region have a 24% possibility of developing supernumerary premolars at a later age, and should therefore be closely monitored. A good group for early diagnosis of supernumerary premolars is from 12 to 24 years of age¹⁹.

References

1. Batewan G, Mossey PA. Ectopia or concomitant hypohyperdontia? A case report. *J Orthod*, 2006; 33(2):71-77.
2. Cohen LL, Fancher A, McLaren JE, Lim CS. Oculocerebrocutaneous syndrome: a case report. *J Clin Pediatr Dent*, 2006; 31(1):63-65.
3. Cochrane SM, Clark JR, Hunt NP. Late developing supernumerary teeth in the mandible. *Br J Orthod*, 1997; 24(4):293-296.
4. Das, Sarkar, Saha, Bhattacharya. Coexistent partial anodontia and supernumerary tooth in the mandibular arch: a rare case. *J Indian Soc Pedo Prev Dent*, 2006; 24(2Suppl):S33-34.
5. Farahani RM, Zonuz AT. Triad of bilateral duplicated permanent teeth, persistent open apex, and tooth malformation: a case report. *J Contemp Dent Pract*, 2007; 8(7):94-100.
6. Fernandez Montenegro P, Valmaseda Castellón E, Berini Aytes L, Gay Escoda C. Retrospective study of 145 supernumerary teeth. *Med Oral Patol Oral Cir Bucal*, 2006; 11(4):E339-344.
7. Gorlin RJ, Hennekam RCM, Cohen MM Jr. Syndromes of the Head and Neck. 4th ed. New York: Oxford University Press, 2001.
8. Hall A, Onn A. The development of supernumerary teeth in the mandible in cases with a history of supernumeraries in the premaxillary region. *J Orthod*, 2006; 33(4):250-255.
9. Kalra N, Chaudhary S, Sanghi S. Non-syndrome multiple supernumerary teeth. *J Indian Soc Pedo Prev Dent*, 2005; 23(1):46-48.
10. Leonardi R, Barbato E. A late-developing supernumerary premolar. *J Clin Orthod*, 2004; 38(6):331-332.
11. Mazzeu, Pardono, Vianna-Margante, Richieri-Costa, Ae Kim, Brunoni, Martelli, de Andrade, Colin, Otto. Clinical characterization of autosomal dominant and recessive variants of Robinow Syndrome. *Am J Med Genet*, 2007; 143(4):320-325.
12. Moore SR, Wilson DF, Kibble J. Sequential development of multiple supernumerary teeth in the mandibular premolar region - a radiographic case report. *Int J Paediatr Dent*, 2002; 12(2):143-145.
13. Mopager V, Sudha P, Anegundi RT, Kulkarni S, Tavarageri A. Supplemental premolars in a 13 year old child - a case report. *J Indian Soc Pedo Prev Dent*, 2002; 20(4):169-172.
14. Nayak UA, Mathian VM, Veerakumar. Non-syndrome associated multiple supernumerary teeth: a report of two cases. *J Indian Soc Pedo Prev Dent*, 2006; 24(2suppl):S11-14.
15. Orhan AI, Ozer L, Orhan K. Familial occurrence of nonsyndromal multiple supernumerary teeth. A rare condition. *Angle Orthod*, 2006; 76(5):891-897.
16. Sasaki H, Funao J, Morinaga H, Nakano K, Ooshima T. Multiple supernumerary teeth in the maxillary canine and mandibular premolar regions: a case in the postpermanent dentition. *Int J Paediatr Dent*, 2007; 17(4):304-308.
17. Scarlan PJ, Hodges SJ. Supernumerary premolar teeth in siblings. *Br J Orthod*, 1997; 24(4):297-300.
18. Shah A, Hirani S. A late-forming mandibular supernumerary: a complication of space closure. *J Orthod*, 2007; 34(3):168-172.
19. Solares R, Romero MI. Supernumerary premolars: a literature review. *Pediatr Dent*, 2004; 26(5):450-58.
20. Stafne EC. Supernumerary Teeth. *Dent Cosmos*, 1932; 74:653-659.
21. Vande Voorde HE. Functioning supernumerary mandibular premolars. Report of a case. *Dent Dig*, 1971; 77(7):392-395.
22. Wynne SE, Aldred MJ, Bartold PM. Hereditary gingival fibromatosis associated with hearing loss and supernumerary teeth - a new syndrome. *J Periodontol*, 1995; 66:75-79.
23. Yeung KH, Lau YW, Lee KH. Mandibular supernumerary premolars: orthodontic and surgical considerations. *Prim Dent Care*, 1997; 4(3):115-117.
24. Zvolanek JW, Spotts TM. Supernumerary mandibular premolars: report of cases. *J Am Dent Assoc*, 1985; 110(5):721-723.

Correspondence and request for offprints to:

Dr. Eleni Markovitsi
Aristotle University of Thessaloniki
Dental School
Department of Orthodontics
P.O. Box 54006
Thessaloniki
Greece