Case report
Kratak izveštaj UDK 616.447-073 Medicus 2006; 7(3): 121-125

SIGNIFICANCE OF ^{99m}Tc-MIBI SCINTIGRAPHY AS PREOPERATIVE DIAGNOSTIC METHOD IN PARATHYROID GLAND DISORDERS: CASE REPORT

Jovan Pesovic[1], Ivan Paunovic[2], Stanko Mrvic[1], Dolores Srbovan[4], Aleksandar Djukic[3], Ljubisa Acimovic[1], Dejan Lazic[1] and Dragan Canovic[1]
[1]Surgical Clinic, Clinical Center, Kragujevac, [2]Endocrine Surgery Center, Institute of Endocrinology, Diabetes and Metabolic Disorders, Clinical Center of Serbia, Belgrade, [3]Institute of Pathological Physiology, School of Medicine, Kragujevac, [4]Institute of Oncology, Institute of Nuclear Medicine, Sremska Kamenica

ZNAČAJ ^{99m}Tc-MIBI SCINTIGRAFIJE KAO PREOPERATIVNE DIJAGNOSTIČKE METODE KOD OBOLJENJA PARATIREOIDNIH ŽLEZDA: PRIKAZ SLUČAJA

Jovan Pešović[1], Ivan Paunović[2], Stanko Mrvić[1], Dolores Srbovan[4], Aleksandar Đukić[3], Ljubiša Aćimović[1], Dejan Lazić[1] i Dragan Čanović[1]
[1]Hirurška klinika, Klinički centar, Kragujevac, [2]Centar za endokrinu hirurgiju, Institut za endokrinologiju, dijabetes i bolesti metabolizma, Klinički centar Srbije, Beograd, [3]Institut za patološku fiziologiju, Medicinski fakultet Kragujevac, [4]Institut za onkologiju, Zavod za nuklearnu medicinu, Sremska Kamenica

Received/Primljen: 20. 01. 2006. Accepted/Prihvaćen: 06. 10. 2006.

ABSTRACT

The aim of our study is to show significance of ^{99m}Tc-methoxyisobutylisonitril (MIBI) scintigraphy as a localization diagnostic preoperative method in surgical treatment of the parathyroid gland (PT) disorders. We showed in this study a patient who had surgical interventions twice due to primary hyperparathyreoidism (PHPT) caused by hyperplasia of the parathyroid glands and carcinoma of the ectopic parathyroid gland. The first surgical intervention was performed without preoperative diagnostics with ^{99m}Tc-MIBI scintigraphy. In the second surgical intervention ^{99m}Tc-MIBI scintigraphy was done preoperatively and it clearly showed a tumor change in the posterior mediastinum that corresponded to the ectopic parathyroid gland (PT). Pathohistologic (PH) findings after the surgical extirpation of PT showed that there was carcinoma of the ectopic PT. By using ^{99m}Tc-MIBI scintigraphy as a localization method before the first surgical intervention, the patient could be spared from undergoing the second surgical intervention and all operative and postoperative risks that these operations had.

Key words: ^{99m}Tc-MIBI scintigraphy, primary hyperparathyreoidism, ectopic parathyroid gland carcinoma, surgical intervention

Abbreviations:

MIBI - Methoxyisobutylisonitril, PHPT - Primary hyperparathyreoidismus, PT - Parathyroid gland, PH - Pathohistologic, MEN - Multiple endocrine neoplasia, HPT - Hyperparathyreoidismus, CT - Computerized tomography, US - Ultrasound, MRI – Magnetic resonance imaging, Tl - Thallium, Tc – Technetium, PTH – Parathyreoid hormone, SVC – Selective venous catheterization

SAŽETAK

Cilj našeg rada je da pokažemo značaj ^{99m}Tc-methoxyisobutylisonitrilom (MIBI) scintigrafije kao lokalizacione dijagnostičke preoperativne metode u hirurškom lečenju oboljenja paratireoidnih žlezdi (PT). U radu smo prikazali pacijenta kod koga je hirurški intervenisano u dva akta zbog primarnog hiperparatireoidizma (PHPT) izazvanog hiperplazijom paratireoidnih žlezdi i karcinomom ektopične paratireoidne žlezde. Prva hirurška intervencija je urađena bez preoperativne dijagnostike ^{99m}Tc-MIBI scintigrafijom. Kod druge hirurške intervencije preoperativno je urađena ^{99m}Tc-MIBI scintigrafija, koja je jasno pokazala tumorsku promenu u zadnjem medijastinumu koja je odgovarala ektopičnoj paratireoidnoj žlezdi (PT). Patohistološki nalaz (PH) posle hirurške ekstirpacije PT je pokazao da se radi o karcinomu ektopične PT. Korišćenje ^{99m}Tc-MIBI scintigrafije kao lokalizacione metode pre prve hirurške intervencije moglo je da poštedi pacijenta izlaganja drugoj hirurškoj intervenciji i svim operativnim i postoperativnim rizicima koje ove operacije nose sa sobom.

Ključne reči: ^{99m}Tc-MIBI scintigrafija, primarni hiperparatireoidizam, karcinom ektopične paratireoidne žlezde, hirurška intervencija

Skraćenice: MIBI - Methoxyisobutylisonitril, PHPT – Primarni hiperparatireoidizam, PT – Paratireoidna žlezda, PH – Patohistološki nalaz, MEN - Multipla endokrina neoplazija, HPT - Hiperparatireoidizam, CT – Kompjuterizovana tomografija, US - Ultrazvuk, MRI – Magnetna rezonanca, Tl - Talijum, Tc – Tehnecijum, PTH – Paratireoidni hormon, SVK – Selektivna venska kateterizacija

INTRODUCTION

PHPT is a disorder that is characterized by an enormous increase of parathyroid hormone secretion that directly affects the metabolism of calcium in that way that it goes out of physiological limits (1). In PHPT there is an increase of mass of functional parathyroid cells and their disturbed function. PHPT can occur as a hereditary or sporadic disorder. In hereditary forms, its manifestation is either isolated – familiar hyperparathyreoidism (in that case primary hyperparathyreoidism is only inherited) or within multiple endocrine neoplasia of type 1 and 2 (MEN1 and MEN2) (2,3). The cause of sporadic hyperparathyreoidism has not been known up to now, but influence of X-rays in the area of the neck and head is considered to be one of etiologic factors. Carcinoma as the cause of HPT is rare and it is found in 0,5–5% cases of HPT (4, 5). Diagnosis of primary HPT is established solely by laboratory analyses (4,6-8). The basic parameters are: hypercalcemia, increased parathyroid hormone (PTH) and calcuria. Symptomatic primary HPT is treated surgically and it falls into the most successful treatments in surgery. But, unsuccessful surgery with persistent hyperparathyreodism, due to inadequate preoperative or intraoperative localization, may be observed in about 10% patients. The conventional surgical approach is bilateral neck exploration, whereas minimally invasive parathyreoidectomy has been made possible by the introduction of ^{99m}Tc-MIBI scintigraphy for preoperative localization of parathyreoid gland (9).

CASE REPORT

The patient, male, age 54, had many complaints in the last few years such as: exhaustion, polyuria, renal colic, hypertension, depression, pains in muscles and bones as well as pathologic fractures of bones of the left lower leg and left forearm. His complaints gradually inten-

Correspondence:
Jovan Pesovic, MD, surgeon
phone: +381 34/302 195, +381 65 302–1955
e-mail: hirurg@ptt.yu
http://www.geocities.com/jovanpesovic
Raka Vukajlovića 8,
34000 Kragujevac

sified and after several hospitalizations, the diagnosis of primary hyperparathyreoidism was established by laboratory examinations (serum calcium, PTH, calcuria). Nodular disorder of the left lobe of thyroid gland (cold solitary nodule) was established by standard diagnostic procedures (US, scintigraphy, hormonal status). Increased values of serum calcium, low values of inorganic phosphates, calcuria (Table 1), high values of PTH (Table 2) were noted in the laboratory. After adequate endocrinologic preoperative preparation that consisted of the application of calcium antagonists (30 mg of pamidronat-Aredia), biphosphonates, corticosteroids (the last value of serum calcium was 2,86 mmol/L) as well as infusions of crystalloid solutions, the patient underwent a surgical intervention. Left lobectomy and resection of isthmus of the thyroid gland were performed, as well as subtotal parathyreoidectomy on the right and parathyreoidectomy on the left with resection of the cervical thymus. Hyperplasia of the removed parathyroid glands was confirmed by PH findings. Pathohistologic findings (no. 326 from 31.01.2005): Primary, nodular hyperplasia of PT, with domination of major cells and follicular histologic organization occurring here and there. Immediately after the surgical intervention, a slight decrease of calcium value occurs (2,87 mmol/L). The patient is discharged from hospital. During the control examination, symptoms of PHPT are still present Laboratory analyses show increased values of serum calcium (3,16 mmol/L), low values of inorganic phosphate (0,36 mmol/L) and increased values of PTH (1150 pg/mL), which points out the existence of ectopic parathyroid gland. Localization examinations are indicated as well as ^{99m}Tc-MIBI scintigraphy and computerized tomography (CT). Pathologic accumulation of radiopharmacs in the upper right half of the posterior mediastinum was registered by performed MIBI scintigraphy. Two-phase scintigraphy of the area of neck and the mediastinum was done 10 minutes after initiating 555 MBq ^{99m}Tc-MIBI and then after 2 hours. On the obtained scintigrams (thyroid phase), the accumulation of radiopharmacs is perceived in operative remains of the thyroid gland (the right lobe) with notable accumulation of radiopharmacs in the region of the upper mediastinum, directly next to pulmonary apices, (Figure1). On the late scintigram (parathyroid phase) after washing, slight accumulation of radiopharmac can be seen in the position of the thyroid gland remains, and the area of accumulation of radiopharmacs can also be detected in the upper mediastinum (next to pulmonary apices, more to the right side), which corresponds scintigraphically to the ectopic tissue of the parathyroid gland (Figure 2). Computerized tomography of the mediastinum in the middle posterior mediastinum retro and paratracheal on the right shows multiocular septal tumor shadow with peripheral calcificates and calcification of septa, attenuation of soft tissues, of size 45x55x65 mm. The change dislocates the esophagus and trachea to the opposite side and it is in close contact with the ascending aorta. After the application of contrast, marginal coloration of the tumor occurs with clear demarcation of cysticly degenerated parts (Figure 3). Existence of the ectopic parathyroid gland, the cause of PHPT was established by localization examinations. The second surgical intervention consisted of partial sternotomy and extirpation of the tumor size about 6x10 cm (Figure 4). PH findings of the extirpated tumor change (no.1225 from 01.04.2005): Carcinoma glandulae parathyreoideae (middle differentiated histologic type). The tumor consists of irregular major and light cells with moderate number of mitoses. Acellular hyalinated bands are present between the groups of malignant cells. There are clear calcifications in the connective tissue. Postoperative course went without surgical complications. Values of serum calcium (1,93 mmol/L) and parathormone (15,6 pg/mL) immediately after the surgical intervention decreased. Postoperative substitution therapy is performed (Ca-sandos, CaCl2, Alfakalcidol, Mg). Six days after the surgical intervention, the patient is taken to the Metabolic unit of the Internal Medicine Clinic where the treatment is continued with pharmaceutical preparations of calcium, magnesium, active form of vitamin D, ACE inhibitors, calcium antagonists, antibiotics, low-molecular heparin, with a constant monitoring of electrolytic, acido-basic, and hemodynamic status, with necessary corrections. The period of parenteral substitution lasted for a long time (about 3 months) which showed the intensity and duration of PHPT. After the administered therapy, subjective and objective improvement occurs (Table 3,4), so that the patient is discharged as recovered and examined to continue further treatment at the outpatient department with therapy: Calcium gluconate, ascorbic acid 500 tabl. 2+2+2, Alfakalcidol 0,25 tabl. 2+2+2, Magnesium hydroxide 150 tabl. 1+0+1, Quinapril 20 tabl. 1+0+1, Amlodipine 5 tabl. 1+0+0.

Table 1, Laboratory analyses before the first operation.

Parameter	value 1	value 2	value 3	Reference scope
Calcium	3.41	3.21	3.45	2.1–2,6 mmol/L
Magnesium			0.35	0.8–1 mmol/L
Calcium clearance	1.51	2.94	0.031	
Inorganic phosphate	0.50	0.74	0.63	0,8–1,6 mmol/L
Phosphorus clearance	21.0	19.8	15.6	6,0–15,0 ml/min
Calciuria	7.41	13.5	9.25	2,5–7,5 mmol/dU
Phosphaturia	14.82	21.06	14.0	12,9–42,0 mmol/dU
TRPO4 (%)	74.7%	74.8%	82.3%	82–95 %
Ionized calcium	2.00			1,12–1,23 mmol/L
Ratio of Cca/Ccr	0.0182	0.0374	0.0211	
Creatinine clearance	83.0 ml/min	78.6 ml/min	88.2 ml/min	97–137 ml/min

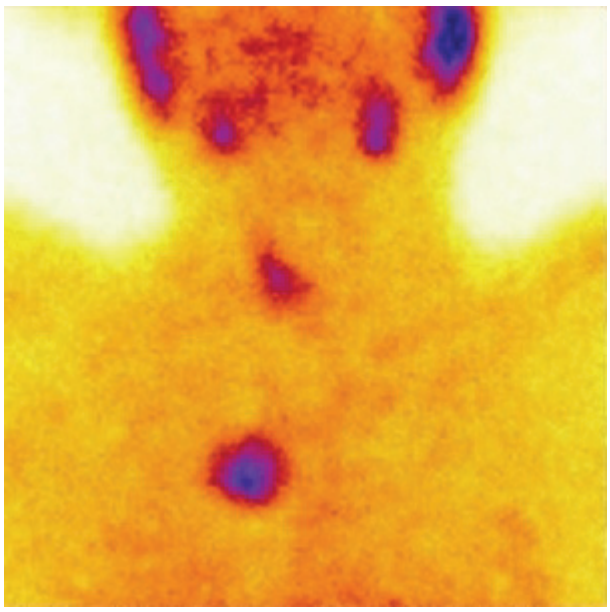

Figure 1, Scintigraphy of the parathyreoideae-early stage. Isotope 99mTc-MIBI (Institute of Oncology, Institute of Nuclear Medicine, Sremska Kamenica).

Table 2, Hormonal analyses before the first operation.

Hormone	Value	Reference scope
fT4	9.2	(7–18) pmol/L
TSH	1.3	(0,25–4) μIU/mL
PTH	1270.0	(15–65) pg/mL
Calcitonin	5.6	(<8.4) pg/mL

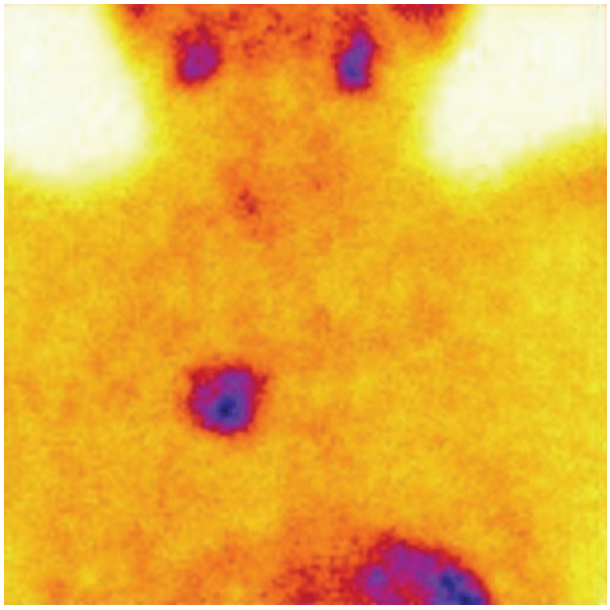

Figure 2, Scintigraphy of the parathyreoideae-late stage. Isotope 99mTc-MIBI (Institute of Oncology, Institute of Nuclear Medicine, Sremska Kamenica).

Table 3, Values of ionized calcium on discharge.

Date (2005.)	30.03.	01.04.	05.04.	12.04.	20.04.	24.06.	26.06.
ion Ca mmol/L	1.30	1.05	1.03	1.10	1.01	1.18	1.05

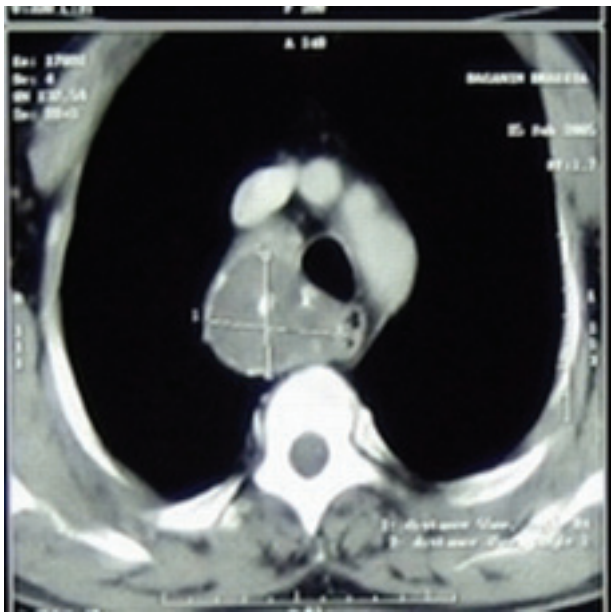

Figure 3, CT diagnostics.

Table 4, Laboratory analyses on discharge.

Proteins	58 U/L	Urea	7.1 mmol/L
Albumins	35 U/L	Creatinine	94 mmol/L
Globulins	23 mmol/L	Potassium	4.1 mmol/L
Fibrinogen	7.0 ml/s	Sodium	145 mmol/L
Glycemia	5.2 mmol/L	Chlorides	105 mmol/L
Bicarbonates	25 mmol/L		

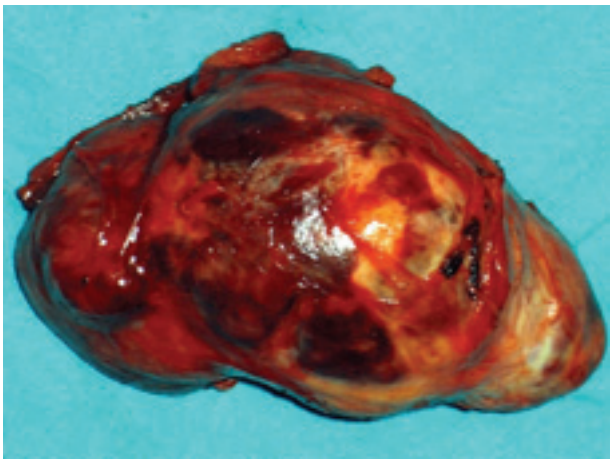

Figure 4, Carcinoma glandulae parathyreoideae (macroscopic slide).

DISCUSSION

Laboratory diagnostic methods (values of serum calcium, calcuria and PTH) are the basis for establishing the diagnosis of parathyroid gland disorders (4,6–8). Operative treatment of the parathyroid gland disorders requires clear localization of the same ones, which emphasizes the significance of localization examinations in the preoperative procedure (10–17).

Localization examinations can be non-invasive and invasive. Non-invasive methods are: ultrasound diagnostics (US), scintigraphy (primarily ^{99m}Tc-MIBI scintigraphy is used), computerized tomography (CT) and magnetic resonance imaging (MRI) (18–24). In invasive localization examinations, the fine needle biopsy under the con-

trol of ultrasound, selective arteriography and selective venous catheterization is used (21).

In 1983, Ferlin applied first the double radioisotopic scintigraphy with 201Tl - chloride and ^{99m}Tc pertechnetate in order to visualize the parathyroid glands (25). There are many controversial opinions concerning the application of localization examinations before the first operation. In most cases, preoperative localization examinations are not applied in the first operation due to the attitude that some experienced surgeon will always discover the diseased parathyroid gland during the first operation. This attitude is confirmed by the fact that localization examinations are without great value in hyperplasias of the parathyroid glands (4,26–29). Doppman is of the same opinion because he considers that the only thing needed for the localization of pathologically changed parathyroid gland is an experienced surgeon. (6). However, frequent need for the second operation in treatment of PHPT has imposed the necessity for localization examinations (27, 30–32). Localization examinations should be critically applied due to relatively high percentage of false negative and false positive results, which was shown by Clarck (16) (Table 5). Because of the disadvantages of localization methods Clarck suggests the algorithm of application of these methods in diagnostics of pathological conditions of the parathyroid glands. (Figure 5).

Table 5. Efficacy of localization diagnostics according to Clarck et al. (16).

	US	Tc/TI	CT	MRI	SVC
Positive	58%	49%	46%	65%	71%
Negative	31%	28%	39%	18%	29%
False positive	13%	2%	15%	18%	-

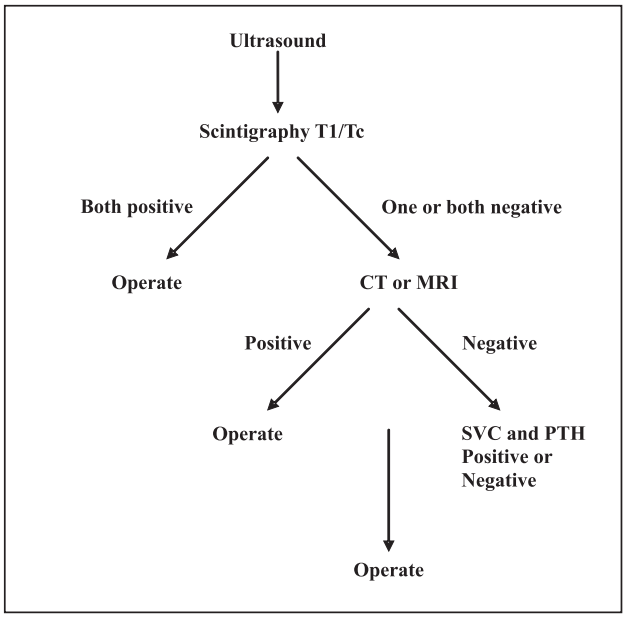

Figure 5. Sequence of procedures in localization diagnostics according to Clarck (17).

CONCLUSION

Localization methods, especially ^{99m}Tc-MIBI scintigraphy, US, CT and MRI are significant in preoperative diagnostics of pathological conditions of the parathyroid glands. The case presented shows that performed MIBI procedure in combination with CT has localized the etiologic cause of PHPT and that application of localization diagnostic procedures will significantly decrease the need for secondary operative intervention and all the risks that it may have.

REFERENCES

1. Bismar HA, El-Bakry AA. Primary hyperparathyroidism. Saudi Med J 2003; 24: 1214–8.
2. Kraimps JL, Barbier J. Familial parathyroidism in multiple endocrine neoplasia syndromes. In: Clark OH, Duh QY, eds. Textbook of endocrine surgery. Philadelphia: Saunders and Co, 1997: 381–3.
3. Huang SM, Duh QY, Shaver J, et al. Familial hyperparathyroidism without multiple endocrine neoplasia. World J Surg 1997; 21: 22–9.
4. Janković R. Primarni hiperparatireoidizam. U: Janković R. Hirurgija tiroidne i paratiroidnih žlezda. 2-go izd. Beograd: Zavod za udžbenike i nastavna sredstva, 2001: 194–203. (in Serbian)
5. Kebebew E, Arici C, Duh QY, Clark OH. Localization and reoperation results for persistent and recurrent parathyroid carcinoma. Arch Surg 2001; 136: 878–85.
6. Dopman JL. Reoperative parathyroid surgery: localisation procedure. Prog Surg 1968; 18: 1171–9.
7. Rothmund H, Diethelm J, Brunner C, et al. Diagnosis and surgical treatment of mediastinal parathyroid tumors. Ann Surg 1976; 183: 139–45.
8. Đurić i sar. Tumori endokrinog sistema. U: Janković R. Hirurgija paratireoidnih žlezda. 1-vo izd. Beograd: Zavod za izdavanje udžbenika, 1988: 491–500. (in Serbian)
9. Mariani G, Gulec AS, Rubello D. Preoprative localization and radioguided parathyroid surgery. J Nucl Med 2003; 44: 1443–58.
10. Mimura Y, Kanauchi H, Ogawa T, Kammori M, Kaminishi M. Review of 41 patients operated on for primary hyperparathyroidism. Biomed Pharmacother 2000; 54: 72–6.
11. Shih WJ, Rastogi A, Stipp V, Gross KK, Coupal JJ, Magoun S. 99mTc MIBI thoracic SPECT for the detection of intrathoracic tumor masses. Clin Nucl Med 1999; 23: 594–600.
12. Maxon HR. Detection of residual and recurrent thyroid cancer by radionuclide imaging. Thyroid 1999; 5: 443–6.
13. Moka D, Voth E, Dietlein M, et al. Technetium 99m-MIBI-SPECT: a highly sensitive diagnostic tool for localization of parathyroid adenomas. Surgery 2000; 128: 29–35.
14. Geatti O. Parathyroid scintigraphy. Q J Nucl Med 1999; 43: 207–16.
15. Kang YS, Rosen K, Clark OH, Higgins CB. Localization of abnormal parathyroid glands of the mediastinum with MR imaging. Radiology 1993; 189: 137–41.
16. Clark P, Wooldridge T, Kleinpeter K, Perrier N, Lovato J, Morton K. Providing optimal preoperative localization for recurrent parathyroid carcinoma: a combined parathyroid scintigraphy and computed tomography approach. Clin Nucl Med 2004; 29: 681–4.
17. Clark PB, Case D, Watson NE Jr, Perrier ND, Morton KA. Enhanced scintigraphic protocol required for optimal preoperative localization before targeted minimally invasive parathyroidectomy. Clin Nucl Med. 2003; 28: 955–60.
18. Hedman J, Hansson G, Lindberg LM, Tissel L. A clinical evaluation of radiation-induced hyperparthyiroidism based on 148 surgically treated patients. World J Surg 1984; 8: 96–103.
19. Borsato N, Zanco P, Camerani M, Saitta B, Ferlin G. Scintigraphy of the parathyroid glands with 201TI: experience with 250 operated patients. Nuklearmedizin 1989; 28: 26–8.
20. Winzelberg GG, Hydovitz JD. Radionuclide imaging of parathyroid tumors: historical perspectives and newer techniques. Semin Nucl Med 1985; 15: 161–70.

21. Feltrin GP, Miotto D, Zotti D, Borsato N, Ferlin G, D'Amico D et all. Invasive and non invasive techniques in primary hyperparathyroidism localizations. Ann Radiol 1985: 28: 143–7.
22. Coakley AJ. Parathyroid imaging. Nucl Med Commun 1995; 16: 522–33.
23. Palestro CJ, Tomas MB, Tronco GG. Radionuclide imaging of the parathyroid glands. Semin Nucl Med 2005; 35: 266–76.
24. Melton GB, Somervell H, Friedman KP, Zeiger MA, Cahid Civelek A. Interpretation of 99mTc sestamibi parathyroid SPECT scan is improved when read by the surgeon and nuclear medicine physician together. Nucl Med Commun 2005; 26: 633–8.
25. Ferlin G, Borsato N, Camerani M, Conte N, Zotti D. New perspectives in localizing enlarged parathyroids by technetium-thallium subtraction scan. J Nucl Med 1983; 24: 438–41.
26. Coakley AJ. Nuclear medicine and parathyroid surgery; a change in practice. Nucl Med Commun 2003; 24: 111–3.
27. Gayed IW, Kim EE, Broussard WF, Evans D, Lee J, Broemeling LD et all. The value of 99mTc-sestamibi SPECT/CT over conventional SPECT in the evaluation of parathyroid adenomas or hyperplasia. J Nucl Med. 2005; 46: 248–52.
28. Sheu SY, Otterbach F, Frilling A, Schmid KW. Hyperplasia and tumors of the parathyroid glands. Pathologe 2003; 24: 373–81.
29. Penner CR, Thompson LD. Primary parathyroid hyperplasia. Ear Nose Throat J 2003; 82: 363.
30. Krausz Y, Bettman L, Guralnik L, et al. Technetium-99m-MIBI SPECT/CT in primary hyperparathyroidism. World J Surg 2006; 30: 76–83.
31. Adamek S, Libansky P, Nanka O, Sedy J, Pafko P. Surgical therapy of primary hyperparathyroidism and it's complications: Experience with 453 patients. Zentralbl Chir 2005; 130: 109–13.
32. Lorenz K, Dralle H. Surgical treatment of hyperparathyroidism. Chirurg 2003; 74: 593–615.