

METASTASIS OF SUBMANDIBULAR ADENOID CYSTIC CARCINOMA TO THE FEMUR BONE CAUSING PATHOLOGICAL FRACTURE: A CASE REPORT

Karaca Onur Mustafa, Balaban Kamil, Yildiz Yusuf Huseyin

Department of Orthopedics and Traumatology, Faculty of Medicine, Ankara University, Turkey

Primljen/Received 14. 10. 2022. god.

Prihvaćen/Accepted 07. 11. 2022. god.

Abstract: Introduction: Adenoid cystic carcinoma (ACC) is a rare head and neck malignancy and is likely to be diagnosed in the major salivary glands. It's also known for its slow clinical course and prolonged survival unless no distant metastasis occurs. Even after a long period from the detection of the primary tumor, metastasis to the lung, brain, liver, and bone has a tendency to occur.

Case presentation: We report a 53-year-old man who presented with a pathological femur fracture thirteen years after the presentation of submandibular ACC. Our patient reported an improved patient-reported outcome after undergoing resection hemiarthroplasty for his bone metastasis.

Conclusion: We tried to accentuate the importance of periodical visits for the probability of distant metastasis and the work-up if it's necessary in such a rare case. It should be kept in mind that proper management of bone metastasis may lead to improvements in the quality of life.

Keywords: Adenoid cystic carcinoma, submandibular gland, bone metastasis, pathological fracture, femur.

INTRODUCTION

Adenoid cystic carcinoma (ACC) is known for a tenacious and recurrent growth pattern with an aggressive long-term course and also late-onset distant metastasis. Besides being an infrequent tumor that accounts for about 1% of all head and neck malignancies, it is common for the major salivary glands, and the most likely location is the submandibular gland (1). It's considered a high-grade neoplasm, and radical surgical resection with postoperative radiotherapy is chosen for treatment mostly.

ACC has a characteristic pattern that is a long period to metastasis after initial diagnosis with or with-

out locoregional recurrence. Distant metastasis is often detected in the lungs, followed by bone, brain, and liver (2). We present a rare case in which metastasis to the femur bone from the submandibular ACC causes a pathological fracture as a first sign. Bone metastasis of the ACC of the major salivary glands has not been extensively discussed in the literature, and the management of these patients is indefinite. Consequently, improvements in the quality of life for our patients were obtained with proper patient management and orthopedic surgery.

CASE REPORT

A 53-year-old man underwent surgery for a left submandibular gland origin mass thirteen years ago. At the time, he had no other symptoms or complaints. Also, there was no other distant metastasis on 18F-fluorodeoxyglucose positron emission tomography (18F-FDG PET) along with computed tomography (CT) scan. Once a diagnostic work-up was completed, after immediate removal of the mass, the results of the histopathological evaluation revealed adenoid cystic carcinoma (ACC). He then received adjuvant radiotherapy.

He presented to the emergency department with a left intertrochanteric fracture after falling from a standing position - low-energy trauma - a year and a half ago (Figure 1). After deepening the anamnesis, we learned that the patient had non-restrictive pain localized to his left hip area for about two or three years until a fracture occurred. He was treated with a Dynamic Hip Screw (DHS) plate for his misdiagnosed potential pathological fracture, and no other investigation for the possibility of metastasis was made. During his early follow-up, he was able to walk with no restrictions and no use of aids. Even though his fracture seemed to

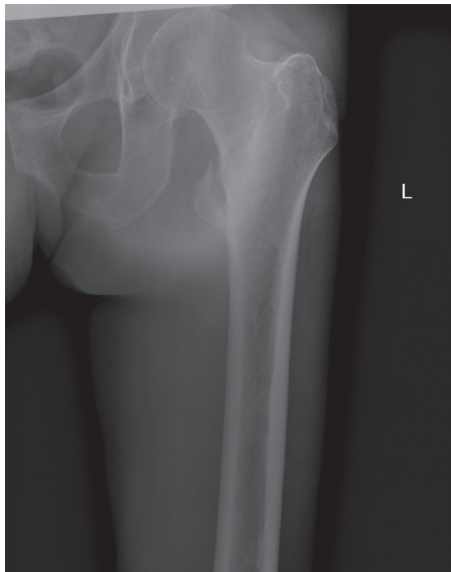


Figure 1. Anteroposterior radiograph of the left thigh shows an intertrochanteric femur fracture with lesser tubercle avulsion

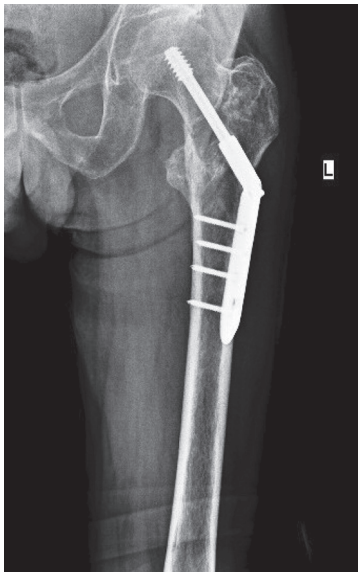


Figure 2. Anteroposterior radiograph of the left thigh shows an appearance one year after surgery of the femur treated with a Dynamic Hip Screw (DHS) plate

be unioned at the end of one year (Figure 2), he complained of persistent pain localized to his left proximal thigh, aggravated with motion and walking. Radiographs of the left femur showed a suspicious lytic lesion located near the lesser trochanter, which indicated the possibility of metastasis. For further investigation, CT and MRI studies were conducted on his left thigh (Figure 3 a, b, c, d).

After applying a closed bone biopsy, an ^{18}F -FDG PET-CT scan showed multiple bone metastases and pulmonary nodules but no evidence of locoregional recurrence. Because of the pathologic fracture and

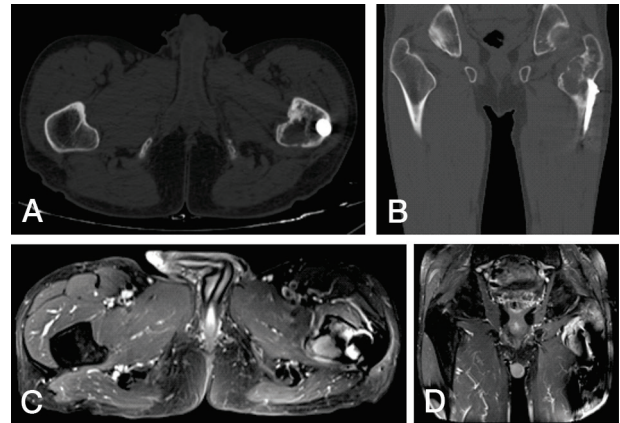


Figure 3. Axial (A) and coronal (B) computerized tomography of the thigh shows a lytic lesion originating from the left lesser tubercle. Axial (C) and coronal (D) magnetic resonance imaging of the thigh also shows a mass arising from the left lesser tubercle that extends adjacent soft tissue

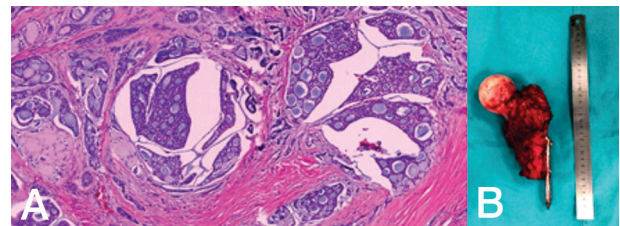


Figure 4. (a) Histological image of the adenoid cystic carcinoma in the left proximal femur (hematoxylin and eosin X 200). (b) Surgical resection material of the left proximal femur

persistent pain risk, the patient underwent left femoral resection hemiarthroplasty after histopathological examination of the biopsy material confirmed ACC metastasis (Figure 4 a, b). The patient was informed, and written consent was obtained.

DISCUSSION AND CONCLUSION

ACC is a rare tumor reported with a yearly 3–4.5 cases per million, accounting for 1% of all head and neck malignancies and 10% of salivary gland tumors (1). It's also known for being commonly detected in major salivary glands. ACC is much more likely to be diagnosed in the submandibular gland, which accounts for 40% of salivary gland cancers (1).

ACC is known for having a slow biological and clinical course but is an expanding and infiltrative malignancy. Authors reported that five-year survival was favorable (75%–80%), contrary survival for fifteen–twenty years was poor (10%–30%) (2). This poor survival in long term was related to insufficiency in preventing and controlling distant metastasis. Happening of distant metastasis in the earlier stage of tu-

mor growth is possible even if cured of the primary tumor in 33% of patients (2). Also, it might be seen even without the recurrence of the primary region. Our patient presented with metastasis to the bone about thirteen years after the treatment for submandibular ACC was completed. Previous studies reported that the mean time for distant metastasis is between 32 and 46 months, with a rate of 20 to 52% (2). Distant metastasis usually occurs within 5 years after treatment, but even fifteen years later, some reported (3). However, distant metastases are independent diseases and should be evaluated differently from local treatment outcomes.

Because a distant metastasis had occurred, we conducted radiological exams to detect other possible distant metastasis in case it was asymptomatic. Eventually, the ¹⁸F-FDG PET-CT scan showed that the patient had multiple metastatic pulmonary nodules and multiple bone metastases in addition to the left intertrochanteric region. Previous literature has indicated that mostly lungs, followed by bones, and less often liver and brain are the sites of distant metastasis additionally multiple metastatic sites are seen in many patients (2). Some authors suggested that previously reported incidences of distant metastasis rate to other sites, such as bone had likely higher because after a lung metastasis was seen, no additional diagnostic examinations were made (1).

There are few studies reported on bone metastasis of submandibular ACC (4, 5, 6). Two studies reported that a 52-year-old man and a 62-year-old woman had metastasis to the left great toe seven and eight years after diagnosis of submandibular ACC (4, 6). In the other case, a 54-year-old woman had multiple bone metastasis to vertebrae from surgically resected submandibular ACC (5). The patients whose metastasis to the great toe were treated with orthopedic surgery like amputation, but the patient who had metastasis to the vertebrae was treated with oral steroid therapy and decompressive palliative radiotherapy.

If a pathological fracture is evaluated as a benign fracture, it could be treated and managed like so. Finally, it results in delays in the diagnosis of malignancy (7). In this case, radiological studies showed a left intertrochanteric fracture with a lesser trochanter fracture at the patient's first emergency admission. After he was treated like it was not pathological, his fracture healed partially at the last follow-up visit. Around the fracture including the lesser trochanter, cortical bridges extended one side to another bone segment that indicated union. But after a long period of follow-ups, it was accepted as a delayed union based on the lytic lesion localized to the intertrochanteric region congruent with his persistent pain.

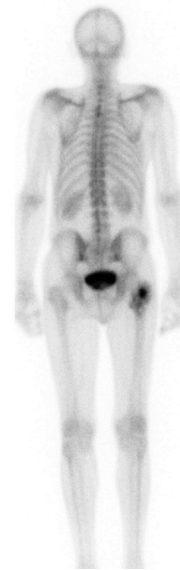


Figure 5. Total body bone scan shows increased uptake from the left intertrochanteric femoral region

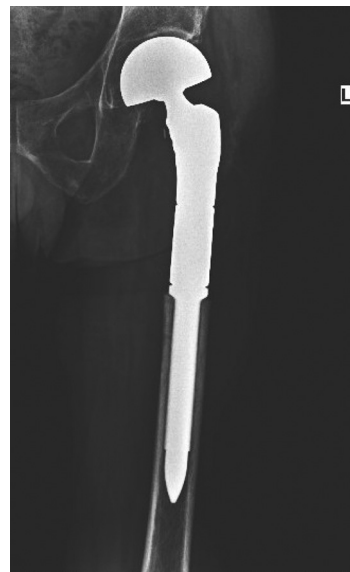

Figure 6. A proximal femoral endoprosthesis was used to reconstruct the bone defect

Periodical assessments are needed because of the clinical manner of ACC with late distant metastasis. While CT or MRI is recommended in the diagnostic control of the primary site for locoregional recurrence, a conventional radiograph of the chest is recommended at least annually or every two years in the detection of distant metastases (3). Accordingly, we advocated that such patients who had salivary gland origin ACC history, specifically those who have complaints regarding bone, should be examined with radiographic studies for the related areas to identify distant metastases. A simple bone scan could show the pathological uptake and could lead us to a diagnosis of metastasis (Figure 5).

Concerning this rare clinical case, prosthetic reconstruction gives the patient a chance for early weight-bearing and faster functional rehab if the patient has a satisfactory general condition but has no efficacious adjuvant treatments available (8) (Figure 6). Our patient, who underwent proximal femoral endoprosthesis replacement after resection, could walk with full weight bearing on the first postoperative day and be discharged on the third postoperative day. The patient reported substantial improvements in activities of daily living on the third-month follow-up visit with no use of crutches to walk or without restrictive pain.

Our present case is distinguished and makes additions from the previously reported ones in a few ways. It is the first reported case that presented with pathological femur fracture due to submandibular ACC metastasis and one of the longest intervals to distant metastasis by thirteen years after initial diagnosis. In

parallel with the previous literature, our case implied that there is a predilection for distant metastasis from submandibular ACC and bone, one of the main sites should therefore be kept in mind.

Conflict of Interests: The authors declare no conflicts of interest related to this article.

Funding: None

Data availability statement

The data that support the findings of this study are available from the corresponding author, KB, upon reasonable request.

Licensing

This work is licensed under a Creative Commons Attribution 4.0 International (CC BY 4.0) License.

Sažetak

METASTAZA SUBMANDIBULARNOG ADENOIDNOG CISTIČNOG KARCINOMA NA FEMURU KAO UZROK PATOLOŠKOG PRELOMA: PRIKAZ SLUČAJA

Karaca Onur Mustafa, Balaban Kamil, Yildiz Yusuf Huseyin

Katedra za ortopediju i traumatologiju, Medicinski fakultet Univerziteta u Ankari, Turska

Uvod: Adenoidni cistični karcinom (ACC) je retka maligna bolest glave i vrata i najčešće se dijagnosticuje u pljuvačnim žlezdama. Takođe je poznat po sporom kliničkom toku i produženom preživljavanju osim ako ne dođe do udaljenih metastaza. Čak i nakon dužeg perioda od otkrivanja primarnog tumora, metastaze u plućima, mozgu, jetri i kostima imaju tendenciju da se pojave.

Prikaz slučaja: Predstavljamo 53-godišnjeg muškarca koji se javio s patološkim prelomom femura trinaest godina nakon pojave submandibularnog ACC.

Naš pacijent je prijavio poboljšani ishod nakon resekcione hemiartroplastike zbog metastaza u kostima.

Zaključak: Pokušali smo da istaknemo važnost periodičnih pregleda zbog verovatnoće udaljenih metastaza i obrada ukoliko je to neophodno u tako retkim slučajevima. Treba imati na umu da pravilno lečenje koštanih metastaza može dovesti do poboljšanja kvaliteta života.

Cljučne reči: adenoidno cistični karcinom, submandibularna žlezda, koštane metastaze, patološki prelom, femur.

REFERENCES

1. Coca-Pelaz A, Rodrigo JP, Bradley PJ, Vander Poorten V, Triantafyllou A, Hunt JL, et al. Adenoid cystic carcinoma of the head and neck - An update. *Oral Oncol.* 2015; 51(7): 652-61. doi: 10.1016/j.oraloncology.2015.04.005.
2. Bradley PJ. Adenoid cystic carcinoma evaluation and management: progress with optimism! *Curr Opin Otolaryngol Head Neck Surg.* 2017; 25(2): 147-53. doi: 10.1097/MOO.0000000000000347.
3. Kokemueller H, Eckardt A, Brachvogel P, Hausamen JE. Adenoid cystic carcinoma of the head and neck - A 20 years experience. *Int J Oral Maxillofac Surg.* 2004; 33(1): 25-31. doi: 10.1054/ijom.2003.0448.
4. Zhang J, Sun Y, Li Z, Feng H. Metastasis of submandibular gland carcinoma to the toe bone: a case report. *Br*

J Oral Maxillofac Surg. 2019; 57(4): 368-70. doi: 10.1016/j.bjoms.2019.03.011.

5. Thariat J, Fournier LS, Badoual C, Marcy PY, Housset M. Aggressive Adenoid cystic carcinoma with asymptomatic spinal cord compression revealed by a "Curtain sign." *J Radiol Case Rep.* 2008; 2(1): 12-5. doi: 10.3941/jrcr.v2i1.3.

6. Weitzner S. Adenoid cystic carcinoma of submaxillary gland metastatic to the great toe. *Am Surg.* 1975; 41(10): 655-8.

7. Marshall RA, Mandell JC, Weaver MJ, Ferrone M, Sodickson A, Khurana B. Imaging features and management of stress, atypical, and pathologic fractures. *Radio Graphics.* 2018; 38(7): 2173-92. doi: 10.1148/rg.2018180073.

8. Anract P, Biau D, Boudou-Rouquette P. Metastatic fractures of long limb bones. *Orthop Traumatol Surg Res.* 2017; 103(1): S41-S51. doi: 10.1016/j.otsr.2016.11.001.

Correspondence to/Autor za korespondenciju

Dr. Kamil Balaban

Ankara University Faculty of Medicine, Orthopedics and Traumatology Department

06230, Altindag, Ankara, Turkey

Phone: +90 505 567 22 72

Fax: +90 312 5082321

E-mail: kamilbalaban1@gmail.com

<https://orcid.org/0000-0002-5179-2058>

How to cite this article: Karaca OM, Balaban K, Yildiz YH. Metastasis of submandibular adenoid cystic carcinoma to the femur bone causing pathological fracture: a case report. *Sanamed*. 2022; 17(3): 179-183. Doi: 10.5937/sanamed0-40661.