

# RETROGRADE TALON INTRAMEDULLARY NAILS VERSUS DISTAL LOCKING PLATES IN THE MANAGEMENT OF EXTRA-ARTICULAR DISTAL FEMORAL SHAFT FRACTURES

Dundar Abdulrahim,<sup>1</sup> Ipek Deniz,<sup>1</sup> Kaya Şehmuz<sup>2</sup>

<sup>1</sup>Hitit University Erol Olçok Training and Research Hospital,  
Department of Orthopedics and Traumatology, Çorum, Turkey

<sup>2</sup> Van Yüzüncü Yıl University Department of Orthopedics and Traumatology, Van, Turkey

Primljen/Received 16. 06. 2023. god.

Prihvaćen/Accepted 16. 07. 2023. god.

**Abstract: Introduction:** Distal femoral shaft fractures are characterized by their increasing incidence and complexity, presenting a significant challenge in management. The objective of this retrospective study was to compare the clinical and radiological results of patients with extra-articular distal third femoral shaft fractures treated using either retrograde Talon Distal Fix nail or a distal femur locking plate.

**Material and Method:** The study comprised 40 patients aged > 18 years who presented at our hospital with a distal third femoral shaft fracture between January 2017 and January 2023. The patients were divided into two groups: Group TDN, treated with retrograde Talon Distal Fix nailing (n = 18), and Group DLP, treated with a distal locking plate (n = 22). Demographic data, follow-up period, operating time, time to union, range of motion (ROM), mechanism of injury (traffic accident, fall from height, workplace accident, gunshot injury), fracture type, complications, and surgical method were retrospectively recorded. Clinical evaluation included deformity, knee ROM, pain, and the knee total score (KSS) for walking and knee stability.

**Results:** The mean age of the patients was 48.03 ± 12.31 (min-max: 23-69) years, and the mean follow-up time for all patients was 15.88 ± 2.32 (12-21) months. The mean time to union was 25.55 ± 1.86 (22-30) weeks. Delayed union and non-union rates were similar between the research groups ( $P = 1.000$ ,  $P = 0.673$ , respectively). Union time (weeks) and mean ROM were not significantly different between the groups ( $P = 0.881$ ,  $P = 0.892$ , respectively). The mean operation time of the TDF group (48.78 ± 3.94 minutes) was significantly lower than that of the DLP group (62.45 ± 3.33 minutes) ( $P < 0.001$ ). The mean

blood loss values of the TDF group (267.5 ± 32.4) were significantly lower than those of the DLP group (324.1 ± 20.2) ( $P < 0.001$ ).

**Conclusion:** This study demonstrated that both retrograde talon nails and locking plates provided satisfactory clinical and radiological results in the management of distal third femoral shaft fractures. Moreover, the retrograde talon nail offered the advantages of a shorter operating time and less intraoperative blood loss.

**Keywords:** Talon Distal Fix, locking plate, distal third femur, union, distal locking.

## INTRODUCTION

Distal third femoral shaft fractures account for approximately 4-6% of all femur fractures (1). These fractures are associated with a high risk of complications, including non-union and delayed union. They commonly occur in young patients due to high-energy trauma, while in elderly patients, low-energy trauma may be the cause. The primary goal of treatment is to achieve problem-free union and enable patients to resume their previous daily activities. Despite advancements in surgical techniques and implant technology, there is an ongoing debate among surgeons regarding the optimal choice of implants for treating distal femoral fractures, leading to variations in surgical procedures.

Several treatment options exist for extra-articular distal femoral fractures, such as open reduction and internal fixation using anatomic plating, less invasive stabilization systems (LISS), antegrade and retrograde intramedullary nailing, and distal femur replacement. However, there is currently no consensus on the in-

dications for each of these treatment strategies, and the debate among surgeons continues (2, 3). The use of locking plates in minimally invasive fixation techniques involves a biological osteosynthesis method, which minimizes damage to soft tissues and preserves the fracture hematoma. Intramedullary fixation techniques offer greater biomechanical stability compared to plate fixation and require less surgical dissection (4).

A newly introduced femoral intramedullary nailing system, the deployable Talon Distal Fix, can be used both antegrade and retrograde in femoral fractures. The Talon Distal Fix Femoral Nail (Orthopedic Designs North America Inc., FL, USA) features a distal locking mechanism provided by expandable talons, eliminating the need for traditional distal locking techniques. This unique locking system shortens operating time, reduces blood loss, and minimizes radiation exposure. To the best of our knowledge, there are no reports in the literature regarding the use of retrograde Talon Distal Fix in the treatment of distal femur fractures.

The objective of this retrospective study was to compare the clinical and radiological outcomes of patients with extra-articular distal third femoral shaft fractures treated with retrograde Talon Distal Fix and distal femur locking plate.

## MATERIAL AND METHODS

This retrospective study was conducted at the Orthopaedics and Traumatology Department of a tertiary-level training and research hospital. Approval for the study was obtained from the Ethics Committee of Hitit University, and informed consent was obtained from all participants in accordance with the Declaration of Helsinki. The study included 40 patients aged > 18 years who presented at the hospital with a distal third femoral shaft fracture between January 2017 and January 2023, and met the study inclusion criteria. The patients were divided into two groups: Group TDF (retrograde Talon Distal Fix nailing, n = 18) and Group DLP (distal locking plate, n = 22).

The study inclusion criteria were as follows: age  $\geq$  18 years, fracture classified as AO/OTA 33 A1, A2, or A3, and a postoperative follow-up period of at least 12 months. Patients were excluded from the study if they were aged < 18 years, if more than 3 weeks had passed since the trauma, if they had multi-trauma, a neuropathic diagnosis, rheumatoid arthritis, a fracture extending to the joint, pathological fracture, active or chronic infection, or a history of surgery on the same side leg. Fractures were classified according to the AO classification system. Radiographic and clinical evaluations were performed on first preoperative presentation, at 2 weeks, 2 months, 4 months postoperatively, and then at 3-month intervals until the end of 1 year.

Demographic data, follow-up period, operating time, time to union, range of joint motion (ROM), mechanism of injury (traffic accident, fall from height, workplace accident, firearms injury), fracture type, complications, and surgical method (Talon nail or locking plate) were recorded retrospectively. Clinical evaluations included assessment of deformity, knee ROM, pain, and the knee total score (KSS) (5) for walking and knee stability, which were categorized as excellent, good, fair, or poor.

Femur alignment was evaluated with respect to varus-valgus, shortening, and antecurvatum-recurvatum using radiological evaluation scores on anteroposterior (AP) and lateral radiographs (6). Osseous healing was defined as the presence of callus in at least 3 of 4 cortices on AP and lateral radiographs, while clinical healing was defined as the absence of pain and sensitivity in the fracture region.

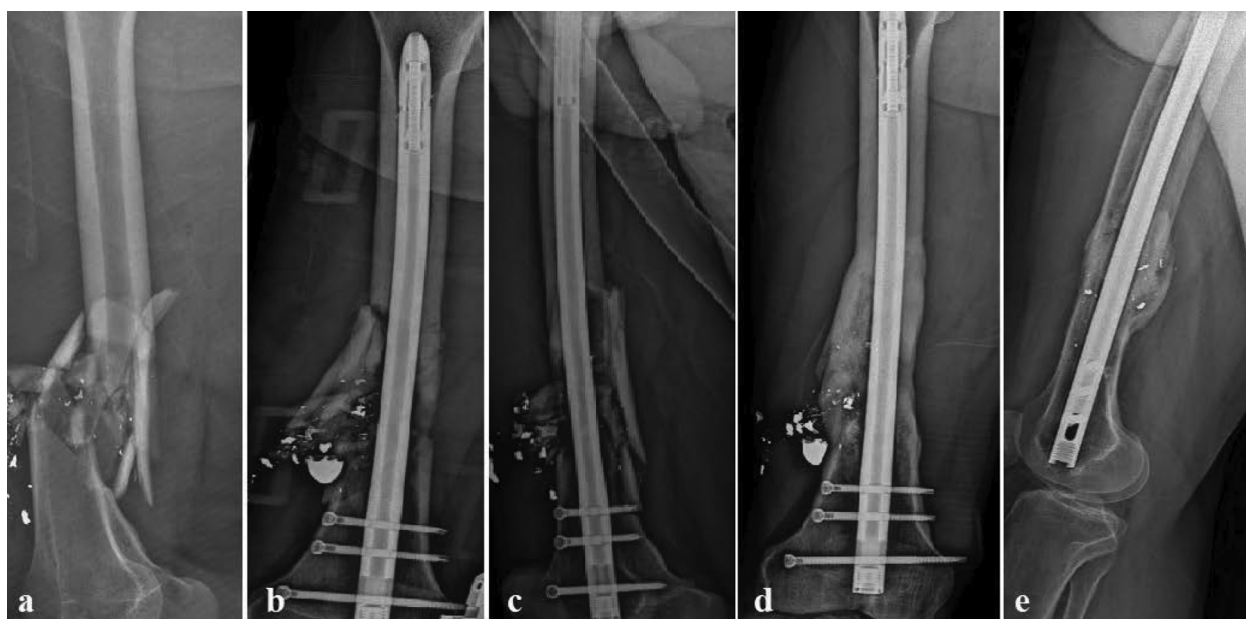
### *Surgical Technique for Group TDF*

The operations were performed on a radiolucent operating table under general or spinal anesthesia. With the patient in a supine position, the knee was flexed to 30° to relieve the deforming forces of the gastrocnemius and facilitate nail placement. A 3 cm infrapatellar skin incision was made, and the patellar tendon was longitudinally separated from the midline. The placement point was defined under fluoroscopy guidance to be on the intercondylar notch on the anterior side of the Blumensaats line and parallel to the mid-axis of the femoral shaft, as confirmed on both AP and lateral radiographs.

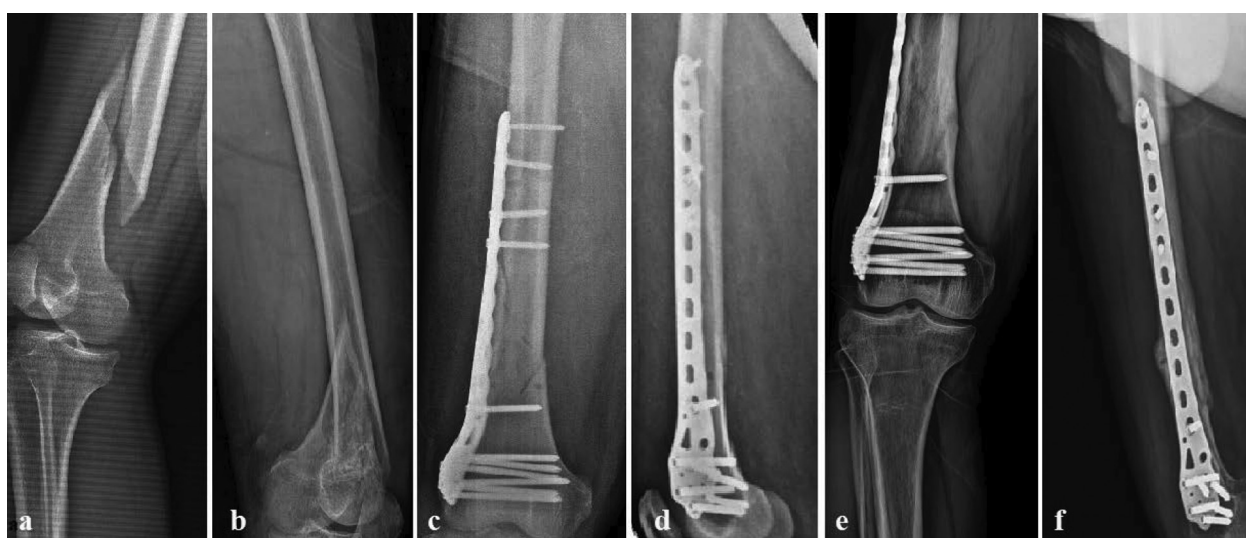Following closed reduction, the reduction status was confirmed on imaging. A guidewire was advanced intramedullary to the proximal femoral fragment, and reaming was initiated. Nail length was measured, and a talon nail one size smaller than the last reamer used was placed intramedullary over the guidewire. The retractable talon anchors providing axial and rotational stability for distal locking were fully expanded, followed by the placement of 2 or 3 screws for proximal locking (Figure 1).

### *Surgical Technique for Group DLP*

Under general or spinal anesthesia, the patient was positioned supine with the knee flexed at 40°. An incision was made at the joint level, extending proximally from the lateral side. The distal locking plate (DLP) was inserted submuscularly below the vastus lateralis toward the proximal part and was fixed with a temporary Kirschner wire under fluoroscopy guidance. Closed reduction was performed, and distal and proximal locking screws were placed percutaneously



**Figure 1.** (a), Preoperative radiograph of a 38-year-old man with type A3 open distal third femoral fracture; (b and c) early postoperative radiograph of distal third femoral fracture managed by Talon distal fix nail; (d and e) Follow up radiograph at 18 weeks showing fracture consolidation



**Figure 2.** (a and b), Preoperative anteroposterior and lateral radiographs of a 52-year-old woman with type A2 distal third femoral fracture; (c and d) early postoperative radiograph of distal third femoral fracture managed by locking plate; (e and f) Follow up radiograph at 18 weeks showing fracture consolidation

over the plate. A compression screw was used when compression of the proximal part was required. The reduction and implant status were confirmed under fluoroscopy (Figure 2).

### **Postoperative Protocol**

Under the supervision of a physiotherapist, isometric quadriceps exercises were initiated as tolerated, along with early passive and graduated active knee and hip joint movements on the first postoperative day for both groups. Non-weight-bearing mobilization with a walker was allowed from the first postoperative day.

Partial weight-bearing was permitted in the 3<sup>rd</sup> week for AO A1 fractures and in the 5<sup>th</sup> week for AO A2 and AO A3 fractures in Group TDF, and in the 6<sup>th</sup> week for Group DLP. Full weight-bearing was allowed as tolerated after confirming bone union on AP and lateral radiographs in both groups.

### **Statistical Methods**

Data analysis was performed using SPSS (Version 22, SPSS Inc., Chicago, IL, USA) software. Descriptive statistics for categorical data were reported as frequency and percentage. The Pearson Chi-square test or

Fisher's exact test were used for comparing categorical variables between research groups based on sample sizes in the crosstab. Descriptive statistics for continuous data were reported as mean  $\pm$  standard deviation (SD) since the assumption of normal distribution was met. Shapiro-Wilk test, Histogram, and Q-Q graphs were used to examine the assumption of normal distribution for numerical data. Levene's test was used to examine the assumption of homogeneity of variances. Since the parametric test assumptions were met, Student's t-test was used to compare continuous data between the two independent groups. The level of statistical significance was set at  $P < 0.05$  for all comparisons.

## RESULTS

The study analyzed data from 40 patients, with 18 (45%) in the TDF (Talon Distal Fix Nail) group and 22 (55%) in the DLP (Distal Locking Plate) group.

Among the patients, 55% ( $n = 22$ ) were male and 45% ( $n = 18$ ) were female. The mean age of the patients was  $48.03 \pm 12.31$  years (min-max: 23-69). The average follow-up time for all patients was  $15.88 \pm 2.32$  months (range: 12-21 months), and the mean time to union was  $25.55 \pm 1.86$  weeks (range: 22-30 weeks).

The comparison of demographic and clinical characteristics between the research groups is presented in Table 1. The distribution of gender ratios was statistically similar between the study groups ( $P = 0.482$ ). The mean age did not show a significant difference between the groups ( $P = 0.302$ ). Specifically, the mean age was  $45.78 \pm 13.22$  years in the TDF group and  $49.86 \pm 11.49$  years in the DLP group. Additionally, the rates of delayed union and non-union were similar among the research groups ( $P = 1.000$ ,  $P = 0.673$ , respectively). The distribution of AO 33 classification rates was also similar between the groups ( $P = 0.894$ ).

*Table 1. Statistical findings for the comparison of socio-demographic and clinical characteristics of the patients*

		Groups		P values
		TDF (n = 18)	DLP (n = 22)	
Gender	Male	11 (61.1%)	11 (50%)	0.482 <sup>a</sup>
	Female	7 (38.9%)	11 (50%)	
Delayed union	No	15 (83.3%)	19 (86.4%)	1.000 <sup>b</sup>
	Yes	3 (16.7%)	3 (13.6%)	
Non-union	No	16 (88.9%)	18 (81.8%)	0.673 <sup>b</sup>
	Yes	2 (11.1%)	4 (18.2%)	
AO 33 classification	A1	8 (44.4%)	10 (45.5%)	0.894 <sup>a</sup>
	A2	6 (33.3%)	6 (27.3%)	
	A3	4 (22.2%)	6 (27.3%)	
KSS score	Poor	1 (5.6%)	1 (4.5%)	0.617 <sup>b</sup>
	Fair	2 (11.1%)	4 (18.2%)	
	Good	3 (16.7%)	7 (31.8%)	
	Excellent	12 (66.7%)	10 (45.5%)	
Radiological score	Poor	0 (0%)	2 (9.1%)	0.681 <sup>b</sup>
	Fair	2 (11.1%)	3 (13.6%)	
	Good	5 (27.8%)	7 (31.8%)	
	Excellent	11 (61.1%)	10 (45.5%)	
Age		$45.78 \pm 13.22$	$49.86 \pm 11.49$	0.302 <sup>c</sup>
Follow-up time (month)		$15 \pm 2.14$	$16.59 \pm 2.26$	<b>0.029<sup>c</sup></b>
Union time (week)		$25.5 \pm 1.91$	$25.59 \pm 1.86$	0.881 <sup>c</sup>
ROM		$109.1 \pm 6.26$	$108.8 \pm 5.17$	0.892 <sup>c</sup>
Operation time (minute)		$48.78 \pm 3.94$	$62.45 \pm 3.33$	<b>&lt; 0.001<sup>c</sup></b>
Blood loss		$267.5 \pm 32.4$	$324.1 \pm 20.2$	<b>&lt; 0.001<sup>c</sup></b>

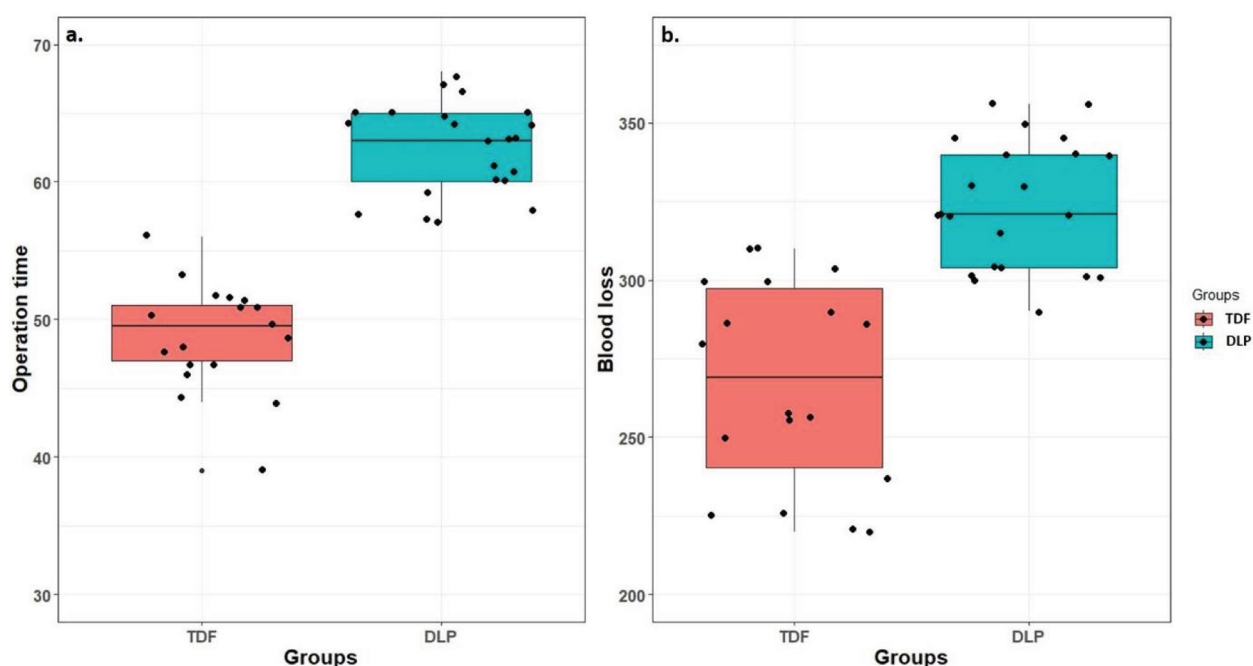
<sup>a</sup>Chi-square test with n (%)

<sup>b</sup>Fisher exact test with n (%)

<sup>c</sup>Student's t-test with mean  $\pm$  standard deviation (SD)

TDF: Talon DistalFix Nail, DLP: Distal Locking Plate





**Figure 3.** Boxplot with jitters showing operative times (minutes) (a.) and blood loss (b.) values between groups TDF: Talon DistalFix Nail, DLP: Distal Locking Plate

**Table 2.** Statistical findings for the comparison of the reasons for the operation between the groups

		Groups		P values
		TDF (n = 18)	DLP (n = 22)	
<b>Traffic accident</b>	No	14 (77.8%)	17 (77.3%)	1.000 <sup>b</sup>
	Yes	4 (22.2%)	5 (22.7%)	
<b>Fall from height</b>	No	10 (55.6%)	10 (45.5%)	0.525 <sup>a</sup>
	Yes	8 (44.4%)	12 (54.5%)	
<b>Work accident</b>	No	15 (83.3%)	18 (81.8%)	1.000 <sup>b</sup>
	Yes	3 (16.7%)	4 (18.2%)	
<b>Shooting</b>	No	15 (83.3%)	20 (90.9%)	0.642 <sup>b</sup>
	Yes	3 (16.7%)	2 (9.1%)	

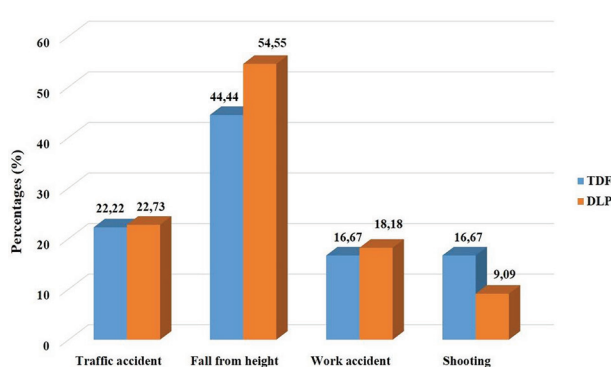
<sup>a</sup>Chi-square test with n (%)

<sup>b</sup>Fisher exact test with n (%)

TDF: Talon DistalFix Nail, DLP: Distal Locking Plate

Furthermore, the distributions of KSS and radiological scores did not show significant differences among the study groups ( $P = 0.617$ ,  $P = 0.681$ , respectively).

The mean follow-up time in the TDF group ( $15 \pm 2.14$  months) was significantly lower than the mean follow-up time in the DLP group ( $16.59 \pm 2.26$  months) ( $P = 0.029$ ). However, the union time (weeks) and mean ROM were not significantly different between the two groups ( $P = 0.881$ ,  $P = 0.892$ , respectively). The mean operation time in the TDF group ( $48.78 \pm 3.94$  minutes) was significantly lower than the mean operation time in the DLP group ( $62.45 \pm 3.33$  minutes) ( $P < 0.001$ ). Additionally, the mean blood loss in the TDF group ( $267.5 \pm 32.4$ ) was significantly lower than the mean blood loss in the DLP group ( $324.1 \pm$



**Figure 4.** Bar graph showing percentages of operation reasons among groups, TDF: Talon DistalFix Nail, DLP: Distal Locking Plate

20.2) ( $P < 0.001$ ). Box plots displaying the distribution of operation times and blood loss values among the groups are shown in Figure 3.

The statistical findings for the comparison of the reasons for the operation between the research groups are presented in Table 2. The distributions of traffic accidents, falls from height, workplace accidents, and gunshot injuries were statistically similar between the groups ( $P = 1.000$ ,  $P = 0.525$ ,  $P = 1.000$ ,  $P = 0.642$ , respectively). Bar graphs illustrating the distribution of the reasons for the operation among the groups are shown in Figure 4.

## DISCUSSION

The results of this retrospective study showed that both retrograde talon intramedullary nailing and locking plate can be safely used in the treatment of distal third femoral shaft fractures. There were no significant differences between the two groups in terms of bone union, delayed union, fracture healing, or complications.

Distal third femoral shaft fractures pose a challenge due to their complexity and high rates of complications. These fractures can result from high-energy trauma in young patients and low-energy trauma in older adults (7). Despite advancements in surgical techniques and implants, complications such as osteoarthritis, non-union, malunion, and residual stiffness are still common (8). Therefore, the optimal treatment for these fractures remains a topic of debate.

Both retrograde intramedullary nailing and locking plate fixation are common surgical methods for distal femoral fractures (9). Minimally invasive approaches with biological osteosynthesis principles are preferred to reduce complication rates. The aim of this study was to evaluate the efficacy of retrograde talon nailing in distal third femoral shaft fractures and compare the results with those of patients treated with locking plate.

The functional and radiological results of both groups were found to be similar, except for the mean operating time and intraoperative blood loss. Retrograde talon nailing showed advantages in terms of shorter operating time and less intraoperative blood loss compared to conventional femoral nails. The deployable talons at the distal end of the Talon Distal Fix nail facilitated distal locking, resulting in these advantages.

There is limited literature on Talon implants (10, 11), and the current study is the first to report the results of retrograde Talon Distal Fix in distal femur fractures.

Both intramedullary nailing and locking plate fixation have shown satisfactory results in previous studies, but the superiority of one technique over the other is not yet fully defined. Biomechanical studies have

suggested that locking systems may be better than classic internal fixation systems. However, clinical studies have not consistently demonstrated significant differences in functional outcomes between the two techniques (12-20).

In the current study, both groups showed similar rates of non-union and delayed union, consistent with previous findings. The functional results at the end of the first year were also similar between the groups. The main advantages of the Talon Distal Fix were its ease of application and shorter operating time compared to conventional locking nails.

The limitations of this study include its retrospective design and relatively small sample size. Larger prospective, controlled studies are needed to further investigate the efficacy of retrograde talon nailing in distal femoral shaft fractures. Despite its limitations, this study is valuable as the first to assess the use of retrograde talon nails in these fractures (12-24).

In conclusion, both retrograde talon intramedullary nailing and locking plate fixation are effective and safe treatment options for distal third femoral shaft fractures. The choice of surgical technique should be based on fracture type, characteristics, comorbidities, and the risk of non-union. The retrograde talon nail offers advantages of shorter operating time and reduced intraoperative blood loss, making it a valuable option in the management of these fractures. Further research with larger patient populations is warranted to validate the findings of this study and provide more comprehensive insights into the use of retrograde talon nails in distal femoral fractures.

## CONCLUSION

In conclusion, the study results demonstrated satisfactory clinical and radiological outcomes with both retrograde talon nails and locking plates in the management of distal third femoral shaft fractures. The retrograde talon nail showed additional advantages, including shorter operating time and reduced intraoperative blood loss, which contributed to decreased morbidity, infection, and anesthesia-related complications.

## Author Contributions

Conceived and designed the analysis: AD, Dİ, ŞK; Collected the data: AD, Dİ; Contributed data or analysis tools: Dİ, ŞK; Performed the analysis: AD, Dİ, ŞK; Wrote the paper: AD, ŞK.

## Abbreviations

**TDN** — Talon Distal Fix nailing  
**DLP** — Distal locking plate  
**ROM** — Range of motion

**KSS** — Knee total score  
**LISS** — Less invasive stabilisation system

**Acknowledgements:** None

**Conflict of Interests:** The authors declare no conflicts of interest related to this article.

**Funding:** None

**Licensing**

This work is licensed under a Creative Commons Attribution 4.0 International (CC BY 4.0) License.

## Sažetak

# RETROGRADNI INTRAMEDULARNI KLIHOVI NASPRAM DISTALNIH PLOČA ZA ZAKLJUČAVANJE U LEČENJU EKSTRAARTIKULARNIH PRELOMA DISTALNE FEMORALNE OSOVINE

Dundar Abdulrahim,<sup>1</sup> Ipek Deniz,<sup>1</sup> Kaya Şehmuz<sup>2</sup>

<sup>1</sup> Hitit Univerzitet, Bolnica za obuku i istraživanje Erol Olçok, Odeljenje za ortopediju i traumatologiju, Corum, Turska

<sup>2</sup> Odeljenje za ortopediju i traumatologiju Univerziteta Van Yüzüncü Yıl, Van, Turska

**Uvod:** Prelomi distalnog dela butne kosti karakterišu se povećanom učestalošću i složenošću i predstavljaju značajan izazov u lečenju. Cilj ove retrospektivne studije bio je uporediti kliničke i radiološke rezultate lečenja pacijenata sa ekstraartikularnim prelomima distalnog dela butne kosti, lečenih retrogradnim intramedularnim klinom ili distalnom zaključavajućom pločom butne kosti.

**Materijali i Metode:** Studija je obuhvatila 40 pacijenata starijih od 18 godina koji su se javili u našu bolnicu sa prelomom distalnog trećeg dela butne kosti u periodu od januara 2017. do januara 2023. godine. Pacijenti su podeljeni u dve grupe: Grupa TDN, koja je lečena retrogradnim intramedularnim klinom (n = 18), i Grupa DLP, koja je lečena distalnom zaključavajućom pločom butne kosti (n = 22). Demografski podaci, period praćenja, vreme operacije, vreme spajanja preloma, opseg pokreta (ROM), mehanizam povrede (saobraćajna nesreća, pad sa visine, radna povreda, prostrelna rana), tip preloma, komplikacije i hirurška metoda su retrospektivno zabeleženi. Klinička procena uključila je deformitet, opseg pokreta u kolenu, bol i ukupni bodovi za koleno (KSS) za hodanje i stabilnost kolena.

**Rezultati:** Prosečna starost pacijenata bila je 48,03 ± 12,31 (min-max: 23-69) godina, a prosečno vreme

praćenja svih pacijenata bilo je 15,88 ± 2,32 (12-21) meseci. Prosečno vreme spajanja preloma iznosilo je 25,55 ± 1,86 (22-30) nedelja. Stope kasnog spajanja i neujedinjenja bile su slične između istraživačkih grupa (P = 1.000, P = 0.673, redom). Vreme spajanja (u nedeljama) i prosečni opseg pokreta (ROM) nisu značajno različiti između grupa (P = 0.881, P = 0.892, redom). Prosečno vreme operacije u grupi sa retrogradnim intramedularnim klinom (48,78 ± 3,94 minuta) bilo je značajno kraće od prosečnog vremena operacije u grupi sa distalnom zaključavajućom pločom (62,45 ± 3,33 minuta) (P < 0,001). Prosečne vrednosti gubitka krvi u grupi sa retrogradnim intramedularnim klinom (267,5 ± 32,4) bile su značajno manje od prosečnih vrednosti gubitka krvi u grupi sa distalnom zaključavajućom pločom (324,1 ± 20,2) (P < 0,001).

**Zaključak:** Ova studija je pokazala da su kako retrogradni intramedularni klinovi tako i distalne zaključavajuće ploče pružili zadovoljavajuće kliničke i radiološke rezultate u lečenju preloma distalnog trećeg dela femura. Osim toga, retrogradni intramedularni klin je pružio prednosti kraćeg vremena operacije i manjeg gubitka krvi tokom operacije.

**Ključne reči:** Distalni fiksator, distalna zaključavajuća ploča, distalni trećina femura, spajanje, distalno zaključavanje.

## REFERENCES

1. Court-Brown CM, Caesar B. Epidemiology of adult fractures: a review. *Injury*. 2006; 37(8): 691–7. doi: 10.1016/j.injury.2006.04.130.
2. Smith JR, Halliday R, Aquilina AL, Morrison RJ, Yip GC, McArthur J, et al. Distal femoral fractures: the need to review the standard of care. *Injury*. 2015; 46(6): 1084–8. doi: 10.1016/j.injury.2015.02.016.

3. Khan AM, Tang QO, Spicer D. The epidemiology of adult distal femoral shaft fractures in a central london major trauma centre over five years. *Open Orthop J*. 2017; 11: 1277–91. doi: 10.2174/1874325001711011277.

4. B Redondo-Trasobares, M Sarasa-Roca, J Rosell-Pradas, L Gracia-Villa, J Albareda Albareda. Comparative clinical and biomechanical study of different types of osteosynthesis in the treatment of distal femur fractures. *Rev Esp Cir Ortop Traumatol*. 2023; 67(3): 216–25. doi: 10.1016/j.recot.2023.01.003.

5. Insall JN, Dorr LD, Scott RD, Scott WN. Rationale of the Knee Society clinical rating system. *Clin OrthopRelat Res.* 1989; (248): 13-4. doi: 10.1097/00003086-198911000-00004.
6. Handolin L, Pajarinen J, Lindahl J, Hirvensalo E. Retrograde intramedullary nailing in distal femoral fractures – Results in a series of 46 consecutive operations. *Injury.* 2004; 35(5): 517-22. doi: 10.1016/S0020-1383(03)00191-8.
7. Hoffmann MF, Jones CB, Sietsema DL, Tornetta III P, Koenig SJ. Clinical outcomes of locked plating of distal femoral fractures in a retrospective cohort. *J Orthop Surg Res.* 2013; 8:43. doi: 10.1186/1749-799X-8-43.
8. Wang SH, Wu CC, Li WT, Shen HC, Lin LC, Pan RY. Outcomes of distal femoral fractures treated with minimally invasive plate osteosynthesis versus open reduction internal fixation with combined locking plate and interfragmentary screws. *Int J Surg.* 2019; 65:107–12. doi: 10.1016/j.ijso.2019.03.019.
9. Ehlinger M, Ducrot G, Adam P, Bonnomet F. Distal femur fractures. Surgical techniques and a review of the literature. *Orthop Traumatol Surg Res.* 2013; 99(3): 353-60. doi: 10.1016/j.otsr.2012.10.014.
10. Dündar A, İpek D, Zehir S. Treatment of basicervical femoral fracture with retractable talon hip compression screw. *Cureus.* 2022; 14(1): e20951. doi: 10.7759/cureus.20951.
11. Çamurcu Y, Sofu H, Issin A, Koçkara N, Genç E, Çetinkaya M. Is talon tibial intramedullary nailing clinically superior compared to conventional locked nailing? *Eklemler Hast Cerrahisi.* 2017; 28(3): 152–7. doi: 10.5606/ehc.2017.55349.
12. Zhang F, Zhu L, Li Y, Chen A. Retrograde versus antegrade intramedullary nailing for femoral fractures: a meta-analysis of randomized controlled trials. *Curr Med Res Opin.* 2015; 31(10): 1897–902. doi: 10.1185/03007995.2015.1078783.
13. Medici A, Meccariello L, Grubor P, Falzarano G. Indications and limitations of retrograde dynamic nailing in the treatment of shaft and distal femoral fractures in young adult. *GIOT.* 2016; 42:1–8.
14. Li B, Gao P, Qiu G, Li T. Locked plate versus retrograde intramedullary nail for periprosthetic femur fractures above total knee arthroplasty: a meta-analysis. *Int Orthop.* 2016; 40(8): 1689-95. doi: 10.1007/s00264-015-2962-9.
15. Fulkerson E, Koval K, Preston CF, Iesaka K, Kummer FJ, Egol KA. Fixation of periprosthetic femoral shaft fractures associated with cemented femoral stems: a biomechanical comparison of locked plating and conventional cable plates. *J Orthop Trauma.* 2006; 20(2): 89–93. doi: 10.1097/01.bot.0000199119.38359.96.
16. Zlowodzki M, Williamson S, Zardiackas LD, Kregor PJ. Biomechanical evaluation of the less invasive stabilization system and the 95-degree angled blade plate for the internal fixation of distal femur fractures in human cadaveric bones with high bone mineral density. *J Trauma.* 2006; 60(4): 836-40. doi: 10.1097/01.ta.0000208129.10022.f8.
17. Dunbar RP, Egol KA, Jones CB, Ertl JP, Mullis B, Perez E, et al. Locked lateral plating versus retrograde nailing for distal femur fractures: a multicenter randomized trial. *J Orthop Trauma.* 2023; 37(2): 70-6. doi: 10.1097/BOT.0000000000002482.
18. Demirtaş A, Azboy I, Özkul E, Gem M, Alemdar C. Comparison of retrograde intramedullary nailing and bridge plating in the treatment of extra-articular fractures of the distal femur. *Acta Orthop Traumatol Turc.* 2014; 48(5): 521–6. doi: 10.3944/AOTT.2014.14.0004.
19. Hierholzer C, Von Rüden C, Pötzel T, Woltmann A, Bühren V. Outcome analysis of retrograde nailing and less invasive stabilization system in distal femoral fractures: A retrospective analysis. *Indian J Orthop.* 2011; 45(3): 243-50. doi: 10.4103/0019-5413.80043.
20. Gao K, Gao W, Huang J, Li H, Li F, Tao J, et al. Retrograde nailing versus locked plating of extra-articular distal femoral fractures: comparison of 36 cases. *Med Princ Pract.* 2013; 22(2): 161-6. doi: 10.1159/000342664.
21. Gupta SKV, Govindappa CVS, Yalamanchili RK. Outcome of retrograde intramedullary nailing and locking compression plating of distal femoral fractures in adults. *OA Orthopaedics.* 2013; 1(3): 23. doi: 10.13172/2052-9627-1-3-969.
22. Markmiller M, Konrad G, Südkamp N. Femur-LISS and distal femoral nail for fixation of distal femoral fractures: are there differences in outcome and complications? *Clin OrthopRelat Res.* 2004; 426: 252-7. doi: 10.1097/01.blo.0000141935.86481.ba.
23. Zlowodzki M, Bhandari M, Marek DJ, Cole PA, Kregor PJ. Operative treatment of acute distal femur fractures: systematic review of 2 comparative studies and 45 case series (1989 to 2005). *J Orthop Trauma.* 2006; 20(5): 366-71. doi: 10.1097/00005131-200605000-00013.
24. Schandelmaier P, Partenheimer A, Koenemann B, Grün OA, Krettek C. Distal femoral fractures and LISS stabilisation. *Injury.* 2001; 32(suppl 3): 55-63. doi: 10.1016/s0020-1383(01)00184-x.

### Correspondence to/Autor za korespondenciju

Abdulrahim Dündar

Çepni Mah. İnönü Caddesi No:176 Merkez Çorum Turkey

Hitit University Erol Olçok Training and Research Hospital, Department of Orthopaedics and Traumatology, Çorum, Turkey

Mobile phone: +95337113273

Fax: +90.(364) 2193030

Orcid: 0000-0003-2617-2073

email: dundarabd@hotmail.com

*How to cite this article:* Dundar A, Ipek D, Kaya Ş. Retrograde Talon Intramedullary Nails versus Distal Locking Plates in the Management of Extra-Articular Distal Femoral Shaft Fractures. *Sanamed.* 2023; 18(2): 105-112. Doi: 10.5937/sanamed0-45059.