10.5937/bjdm2202100Q

BALKAN JOURNAL OF DENTAL MEDICINE

ISSN 2335-0245

A Micro-Computed Tomographic Assessment of Oval-Shaped Root Canals Obturated with Bioceramic Sealer Using Different Obturation Techniques

SUMMARY

Background/Aim: *To evaluate void volumes in oval-shaped root canals obturated with three different obturation systems using micro-computed tomography (micro-CT).* ***Material and Methods:*** *Twenty-four distal roots of mandibular molar teeth canals were prepared and randomly divided into three groups (n = 8 in each group). The canals were obturated using single cone (SC), GuttaCore (GC), and warm vertical compaction (WVC) techniques. Each specimen was scanned using a micro-CT device. The volumes of the voids were calculated, and the data were statistically analyzed using a one-way analysis of variance and post hoc Tukey's (P < .05).* **Results:** *The void volumes in the WVC group were significantly lower than those in the other groups (P < .05). When different root canal parts were examined, the void volumes increased significantly from the apical to the coronal level in the GC and SC groups (P < .05). In the WVC group, most voids were observed in the middle part (P < .05), whereas there was no significant difference in void volumes in the coronal and apical parts (P > .05).* **Conclusions:** *None of the systems provided void-free root filling. However, the void volume using the WVC system was significantly lower than that observed using the other systems.*

Keywords: Filling Quality, Void, GuttaCore, Single Cone, Warm Vertical Compaction

Taha Özyürek[1], Neslihan Büşra Keskin, Zeliha Uğur Aydın[3]

[1] Department of Endodontics, Faculty of Dentistry Bahçeşehir University, Istanbul, Turkey
[2] Department of Endodontics, Faculty of Dentistry, Yıldırım Beyazıt University, Ankara, Turkey
[3] Department of Endodontics, Faculty of Dentistry, Bolu Abant Izzet Baysal University Bolu, Turkey

ORIGINAL PAPER (OP)
Balk J Dent Med, 2022;100-105

Introduction

An ideal root canal filling should obturate the whole root canal space, with a homogeneous density in all three dimensions. When root canals are not homogeneously filled, voids may remain within the canals. Those voids prevent successful adaptation of filling materials to the root canal walls and create a suitable medium for bacterial leakage[1,2]. Viable bacteria within the root canal system may leak into periapical tissues and cause tissue inflammation or contribute to existing inflammation in the periapical area after root canal treatment. Previous research showed that apical periodontitis that developed after endodontic treatment was related to voids between the canal wall and canal filling[3]. Thus, a radiographic assessment of the quality of obturation after root canal treatment is important for the prognosis of endodontic treatment[1,2].

Various canal filling methods, including single cone (SC), GuttaCore (GC), and warm vertical compaction (WVC) techniques, have been developed to improve the quality of root canal filling[4]. The single cone (SC) technique involves filling the root canal with gutta-percha after root canal preparation, which is performed using nickel-titanium rotary files with a size and taper similar to those used in the last phase of preparation. The most important advantage of the SC technique is that the dentist can complete canal filling more easily and in a shorter time than is possible using other methods[5]. Major disadvantages of this technique are the relatively higher volume of sealer, possible leakage because of the sealer dissolving over time, and incomplete adaptation to the anatomic structures of root canals[5,6].

To better adapt to the irregularities of root canals, the root canal filling material (gutta-percha) is heated, and the root canal walls are covered with a thin layer of sealer[7]. Injection of thermo-plasticized gutta-percha, thermo-mechanical compaction of gutta-percha, and carrier-based filling methods are performed to soften the gutta-percha.

The aim of the present study was to assess void volumes between dentin wall and obturation materials applied to mandibular molar teeth with oval-shaped distal canals using different filling methods (SC, GuttaCore [GC], and warm vertical compaction [WVC]) utilizing micro-computed tomography (micro-CT). The null hypothesis was that there would be no difference between root canals filled using different filling methods in terms of void volumes between the root canal walls and dentin.

Material and Methods

Sample size determination

Based on a previous study[8], a power calculation was performed using variance statistical test (G*Power 3.1 software; Heinrich Heine University, Dusseldorf, Germany), with $\alpha = 0.05$ and $\beta = 0.95$. The results indicated that the sample size should be a minimum of eight teeth in each group.

Selection and preparation of specimens

After obtaining the approval of the ethics committee (no: 2019-270), the distal roots of 24 mandibular molar teeth, which had completed their development and been extracted because of orthodontic and periodontal reasons, were included in the study. The teeth were scanned using micro-CT. Only roots of teeth with oval-shaped canals were included[2].

The roots were examined under 12× magnification (Olympus BX43; Olympus Co., Tokyo, Japan) to detect cracks, resorption, and calcification. The specimens were then stored in 0.1% thymol solution at 5° C until used.

Root canal shaping

After preparation of the access cavities of the teeth, a #10 K-type file (VDW, Munich, Germany) was then inserted into the root canal until it was visible at the apical. The working length of each root canal was determined to be 1 mm shorter than this value. The root canals were prepared using EndoSequence BC (Brasseler USA, Savannah, GA) rotary files and an endodontic motor (VDW) in accordance with the manufacturer's instructions (torque setting: 1.8–2.3 Ncm, speed setting: 500–600 RPM) until a 45.04 apical size was achieved. After each file change, the root canals were irrigated using 3 ml of 2.5% sodium hypochlorite (CanalPro; Coltene-Whaledent, Allstetten, Switzerland) solution. For the final irrigation, all the samples were irrigated using 5 ml of 17% EDTA (CanalPro; Coltene-Whaledent) solution for 1 min. The irrigation protocol was completed by irrigating the root canals with 3 ml of distilled water. The root canals were dried using paper points (Brasseler USA). In all the irrigation procedures, a 31-gauge Navi Tip double side-port needle (Ultradent Products Inc., South Jordan, UT, USA) was used. The teeth were then randomly divided into three groups for root canal filling ($n = 8$ in each group).

Root canal filling

Group 1: SC technique

Size 45.04 EndoSequence BC (Brasseler USA) master cones were tugged back. The master cones were then covered with EndoSequence (Brasseler USA) root canal sealer, and the root canals were filled using the SC cone protocol. Following the filling procedure, excessive material was removed using a heat source and vertically compacted.

Group 2: GC technique

After reaching the working length, the size verifiers were tugged back. The EndoSequence (Brasseler USA) root canal sealer was applied to the canal walls using paper points that had the same taper size of the final file. GuttaCore (Dentsply Sirona, Ballaigues, Switzerland) with a 40.04 taper preset to the working length was used. The gutta-percha was softened by heating in an oven (ThermaPrep 2 Oven; Dentsply Sirona) according to the instructions of the manufacturer and placed in the canals at a length 0.5 mm shorter than the working length. The stem parts of the obturators were removed by cutting using a rounded diamond burr.

Group 3: WVC technique

Pluggers that can penetrate the canal at a length 0.5 mm shorter than the working length were used. All pluggers were suitable for the apical, middle, and coronal regions of the canal. The EndoSequence BC points and master cones (45.04) were tugged back. The apical parts of the master cones were cut by 1 mm. The EndoSequence points (45.04) were then covered with EndoSequence canal pat and pushed until they reached the working length. The root canal fillings were cut using a heated plugger (Calamus Dual 3D Obturation System; Dentsply Sirona) set to 200° C, leaving 5 mm gutta-percha at the apical. Excessive gutta-percha material was removed from the coronal. The gutta-percha material in the apical part was compacted using the plugger. The part of the Calamus Dual 3D Obturation System (Dentsply Sirona) carrying the gutta-percha was used for filling the rest of the parts of the root canal fillings, and the plugger was used to compact the gutta-percha material in an apical direction.

For all the specimens, access cavities were dressed using temporary filling material (Cavit G; 3M Espe, Seefeld, Germany). The specimens were stored at 37° C (100% humidity) for 1 week to achieve complete hardening of the canal path. The same clinician performed all the procedures (Figure 1).

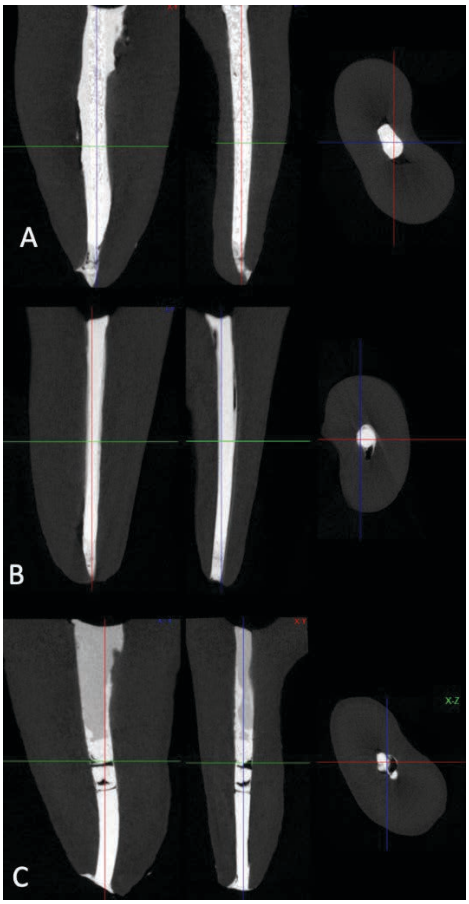

Figure 1. Representative three-dimensional reconstructional image of oval-shaped canals of distal roots of mandibular molar teeth obturated using Single Cone (A), GuttaCore (B), and Warm Vertical Compaction techniques (C).

Micro-CT assessment

The specimens were scanned using micro-CT (SkyScan 1172; Bruker- microCT, Kontich, Belgium) at 10 µm/pixel resolution and 10 kV and 100 100 µA power before and after root canal preparation. To reduce the level of noise, each image was taken three times, and the mean images were obtained. All the scanning procedures were performed at 360°, and the specimens were rotated by a 0.4° angle between each scan. Aluminum and copper filters were used to prevent beam hardening. After the scanning operation, a structuring procedure was performed using Nrecon (Bruker MicroCT software. The before and after comparison of the specimens was performed using the isolog feature of DataViewer (Bruker MicroCT) software. The analyses of the specimens were performed using CTAn (Bruker MicroCT) software, and CTVox (Bruker MicroCT) software was used for imaging. The volumes of the voids were calculated using the method reported by Iglecias *et al.*[9]. CTVol (Bruker MicroCT) software was used for 3D imaging of the specimens.

Statistical analysis

To verify the assumption of normality, the data were analyzed using the Shapiro-Wilk test. A one-way analysis and post hoc Tukey's tests were performed for comparisons. The statistical analyses were performed using SPSS 21.0 software (IBM-SPSS Inc., Chicago, IL, USA). The statistical significance level was set at 5%.

Results

The percentage of void volumes (mean and standard deviations) in the three groups are summarized in Table 1. When the total void volume was calculated, the void volume in the WVC group was significantly lower than that in the GG and SC groups ($P < .05$). The total void volume in the GC group was significantly lower than that in the SC group. However, there was no significant difference in the void volume in the apical third among the three groups ($P > .05$). The void volumes in the middle and coronal thirds of the WVC group were significantly lower than those in the GC and SC groups ($P < .05$). In the GC group, the void volume was significantly lower than that in the SC group in the middle and coronal thirds ($P < .05$).

The void volume in the coronal third was significantly higher than that in the apical and middle thirds in the GC and SC groups ($P < .05$). The highest void volume was observed in the middle third in the WVC group ($P < .05$). There was no statistically significant difference in the void volume in the coronal and apical parts in the WVC group ($P > .05$).

Table 1. Mean and standard deviations of percentage (%) of voids volume detected in root canal filling after different obturation techniques

Obturation Technique	**Apical**	**Middle**	**Coronal**	***P*-value**	**Total**
Single Cone	7.05 ± 2.15^{ax}	16.54 ± 2.41^{by}	22.94 ± 5.02^{bz}	< .05	46.54 ± 6.17^{a}
GuttaCore	5.69 ± 1.14^{ax}	12.77 ± 1.45^{ay}	15.66 ± 1.04^{az}	< .05	34.12 ± 1.02^{b}
Warm Vertical Compaction	5.15 ± 0.54^{ax}	8.75 ± 0.77^{cy}	5.72 ± 0.68^{cx}	< .05	19.62 ± 0.90^{c}
***P*-value**	> .05	< .05	< .05		< .05

* Different superscripts indicate statistically significant difference at 5% significance level ($^{a, b, c}$ for columns; $^{x, y, z}$ for rows).

Discussion

The quality of obturation depends on various factors, such as the anatomical characteristics of the root canal system, type of root canal sealer, experience of the clinician, and obturation method[2]. Due to anatomical variations, some regions of the root canal cannot be accessed using endodontic devices, resulting in less than optimum root canal filling[10,11]. In the present study, the quality of SC, GC, and WVC root canal filling techniques in canals with anatomical variations (i.e., oval-shaped canals) was studied.

Various methods, such as liquid filtration, staining tests, radioisotopes, scanning electron microscope, analysis, and bacterial leakage, can be used to assess the quality of root canal filling[12,13]. However, these methods create irreversible damage to experimental models. An ideal experimental model should preserve the integrity of the specimen[14]. Thus, in accordance with previous research[2,15,16], in the present study, we used nondestructive and repeatable micro-CT analysis to obtain quantitative values and 3D imaging of voids left different void volumes were observed in the three groups at different root canal levels in the present study. Thus, the null hypothesis was rejected. In the present study, the void volumes in the coronal and middle thirds in the WVC group were significantly lower as compared with those in the other groups. Similar to the present study, in a micro-CT analysis study, Keleş *et al.*[2] reported that as compared with the lateral compaction technique, the WVC technique resulted in fewer voids in oval-shaped canals. In contrast, other studies that compared WVC and SC techniques reported no significant difference in voids left after root canal filling[17-19].

In the present study, the void volume using the WVC technique was lower than that using the GC technique. Other studies that compared these two filling techniques using micro-CT reported no significant difference in the canal filling quality of two techniques[15,20]. Using confocal laser microscope analysis, which is a destructive technique, Marciano *et al.*[21] reported no significant difference between Thermafil (Dentsply Sirona), WVC, and SC techniques in terms of void volumes. The discordant results may be due to the type of tooth, quality of root canal preparation, type of canal sealer, and different assessment methods used. Previous research reported that existing voids might be compressed by compacting gutta-percha using pluggers while filling[22]. Compacting of warm gutta-percha in a vertical direction using the WVC technique may explain the reduced void volume in the WVC group in the present study as compared with that in the other groups.

According to the results of the present study, there was no significant difference between the filling techniques in terms of void volumes in the apical third. However, as compared with the GC and WVC techniques, the SC technique resulted in significantly more voids in the coronal and middle thirds of the root canals. Castagnola *et al.*[23] reported that thermoplastic gutta-percha used in the GC technique better adapted to the root canal anatomy and therefore contained fewer voids on micro-CT than root canals filled using the SC system. Schafer *et al.*[24] used a digital stereomicroscope to assess void volumes and observed no voids at distances of 2 mm and 4 mm from the apical when using the GC technique. They also found that the GC technique resulted in fewer voids in the coronal third as compared with the void volume using the SC technique. Based on a micro-CT assessment, Çelikten *et al.* [25] reported that the SC technique led to more voids than root canal filling using the Thermafill technique. However, Somma *et al.*[14] detected no significant difference in void formation in single-root teeth after root canal filling using SC, System B, and Thermafill systems. The carrier-based filling technique is similar to the SC technique in terms of placing the gutta-percha into the canal in a single step at working length. Previous research attributed void formation using this technique to failure in placing the gutta-percha into the canal or gutta-percha escaping from the carrier and adhering to the canal walls in narrow and curved canals[14]. Zogheib *et al.*[26] reported that carrier-based systems provided better sealing than other systems, although they created voids. Other studies reported that a reduced amount of canal sealer was needed during root canal filling using carrier-based systems [27,28]. Another study found that the pressure applied to the apical region during filling decreased the formation of voids and improved adaptation of the filling material to the root canal[16]. The results of the present study were similar to those of some previous studies[22,23,29], although there were methodological differences between the studies.

Wu *et al.*[30] and Somma *et al.*[14] emphasized that a larger volume of canal sealer was required when using the SC technique as compared with that needed when using other filling techniques. When using the SC technique, voids form in the coronal and middle thirds when the master cone is placed into irregular-shaped canals[28]. Although the SC technique can be used for filling narrow and curved canals, it is not recommended for wide and oval-shaped canals, as it creates voids in the apical and middle thirds[5,23].

In the present study, when void volumes using the different filling techniques were compared at different root canal levels, the void volume was highest in the middle third of roots in the WVC group. Heated gutta-percha expands and then shrinks by 1-2% as it cools. During this process, voids form in the root canal walls[20]. The Calamus Dual 3D Obturation system has a hybrid structure. Previous research attributed the increased void formation in the middle third to shrinkage during the cooling process, as gutta-percha is in the beta phase in the

apical third and in the alpha-phase in middle and coronal thirds during filling.

As is well known, voids in root canals allow residual microorganisms to reach the periapical region and induce inflammation or contribute to existing inflammation. The latter can have a negative effect on the success of endodontic treatment[3]. Further studies on the relationship between void volumes in root canals and the amount of bacterial leakage into the periapex under clinical conditions would shed light to what extent the void volume in root canals contributes to disease.

Conclusions

None of the systems provided completely homogeneous, void-free root fillings. The WVC system was associated with a lower percentage of void volume as compared with that of the other systems.

References

1. Whitworth J. Methods of filling root canals: principles and practices. Endod Topics, 2005;12:2-24.
2. Keles A, Alcin H, Kamalak A, Versiani MA. Micro-CT evaluation of root filling quality in oval-shaped canals. Int Endod J, 2014;47:1177-1184.
3. Moreno JO, Alves FR, Goncalves LS, Martinez AM, Rocas IN, Siqueira JF, Jr. Periradicular status and quality of root canal fillings and coronal restorations in an urban Colombian population. J Endod, 2013;39:600-604.
4. Combe EC, Cohen BD, Cummings K. Alpha- and beta-forms of gutta-percha in products for root canal filling. Int Endod J, 2001;34:447-451.
5. Horsted-Bindslev P, Andersen MA, Jensen MF, Nilsson JH, Wenzel A. Quality of molar root canal fillings performed with the lateral compaction and the single-cone technique. J Endod, 2007;33:468-471.
6. Carrotte P. Endodontics: Part 8. Filling the root canal system. Br Dent J, 2004;197:667-672.
7. De-Deus G, Reis C, Beznos D, de Abranches AM, Coutinho-Filho T, Paciornik S. Limited ability of three commonly used thermoplasticized gutta-percha techniques in filling oval-shaped canals. J Endod, 2008;34:1401-1405.
8. Gagliardi J, Versiani MA, de Sousa-Neto MD, Plazas-Garzon A, Basrani B. Evaluation of the Shaping Characteristics of ProTaper Gold, ProTaper NEXT, and ProTaper Universal in Curved Canals. J Endod, 2015;41:1718-1724.
9. Iglecias EF, Freire LG, de Miranda Candeiro GT, Dos Santos M, Antoniazzi JH, Gavini G. Presence of Voids after Continuous Wave of Condensation and Single-cone Obturation in Mandibular Molars: A Micro-computed Tomography Analysis. J Endod, 2017;43:638-642.
10. Wu MK, Wesselink PR. A primary observation on the preparation and obturation of oval canals. Int Endod J, 2001;34:137-141.
11. Wu MK, Fan B, Wesselink PR. Diminished leakage along root canals filled with gutta-percha without sealer over time: a laboratory study. Int Endod J, 2000;33:121-125.
12. Selem LC, Li GH, Niu LN, Bergeron BE, Bortoluzzi EA, Chen JH, et al. Quality of obturation achieved by a non-gutta-percha-based root filling system in single-rooted canals. J Endod, 2014;40:2003-2008.
13. Haikel Y, Freymann M, Fanti V, Claisse A, Poumier F, Watson M. Apical microleakage of radiolabeled lysozyme over time in three techniques of root canal obturation. J Endod, 2000;26:148-152.
14. Somma F, Cretella G, Carotenuto M, Pecci R, Bedini R, De Biasi M, et al. Quality of thermoplasticized and single point root fillings assessed by micro-computed tomography. Int Endod J, 2011;44:362-369.
15. Li GH, Niu LN, Selem LC, Eid AA, Bergeron BE, Chen JH, et al. Quality of obturation achieved by an endodontic core-carrier system with crosslinked gutta-percha carrier in single-rooted canals. J Dent, 2014;42:1124-1134.
16. Gandolfi MG, Parrilli AP, Fini M, Prati C, Dummer PM. 3D micro-CT analysis of the interface voids associated with Thermafil root fillings used with AH Plus or a flowable MTA sealer. Int Endod J, 2013;46:253-263.
17. Alshehri M, Alamri HM, Alshwaimi E, Kujan O. Micro-computed tomographic assessment of quality of obturation in the apical third with continuous wave vertical compaction and single match taper sized cone obturation techniques. Scanning, 2016;38:352-356.
18. Angerame D, De Biasi M, Pecci R, Bedini R, Tommasin E, Marigo L, et al. Analysis of single point and continuous wave of condensation root filling techniques by micro-computed tomography. Ann Ist Super Sanita, 2012;48:35-41.
19. Kim S, Kim S, Park JW, Jung IY, Shin SJ. Comparison of the Percentage of Voids in the Canal Filling of a Calcium Silicate-Based Sealer and Gutta Percha Cones Using Two Obturation Techniques. Materials, 2017;10:1170.
20. Zogheib C, Hanna M, Pasqualini D, Naaman A. Quantitative volumetric analysis of cross-linked gutta-percha obturators. Ann Stomatol, 2016;7:46-51.
21. Marciano MA, Ordinola-Zapata R, Cunha TV, Duarte MA, Cavenago BC, Garcia RB, et al. Analysis of four gutta-percha techniques used to fill mesial root canals of mandibular molars. Int Endod J, 2011;44:321-329.
22. Baser Can ED, Keles A, Aslan B. Micro-CT evaluation of the quality of root fillings when using three root filling systems. Int Endod J, 2017;50:499-505.
23. Castagnola R, Marigo L, Pecci R, Bedini R, Cordaro M, Liborio Coppola E, et al. Micro-CT evaluation of two different root canal filling techniques. Eur Rev Med Pharmacol Sci, 2018;224:778-783.
24. Schafer E, Schrenker C, Zupanc J, Burklein S. Percentage of Gutta-percha Filled Areas in Canals Obturated with Cross-linked Gutta-percha Core-carrier Systems, Single-Cone and Lateral Compaction Technique. J Endod, 2016;42:294-298.
25. Celikten B, F Uzuntas CF, I Orhan AI, Tufenkci P, Misirli M, Demiralp KO, et al. Micro-CT assessment of the sealing ability of three root canal filling techniques. J Oral Sci, 2015;57:361-366.

26. Zogheib C, Naaman A, Sigurdsson A, Medioni E, Bourbouze G, Arbab-Chirani R. Comparative micro-computed tomographic evaluation of two carrier-based obturation systems. Clin Oral Investig, 2013;17:1879-1883.
27. Gencoglu N, Garip Y, Bas M, Samani S. Comparison of different gutta-percha root filling techniques: Thermafil, Quick-fill, System B, and lateral condensation. Oral Surg Oral Med Oral Pathol Oral Radiol Endod, 2002;93:333-336.
28. Weis MV, Parashos P, Messer HH. Effect of obturation technique on sealer cement thickness and dentinal tubule penetration. Int Endod J, 2004;37:653-663.
29. Gordon MP, Love RM, Chandler NP. An evaluation of .06 tapered gutta-percha cones for filling of .06 taper prepared curved root canals. Int Endod J, 2005;38:87-96.
30. Wu MK, Bud MG, Wesselink PR. The quality of single cone and laterally compacted gutta-percha fillings in small and curved root canals as evidenced by bidirectional radiographs and fluid transport measurements. Oral Surg Oral Med Oral Pathol Oral Radiol Endod, 2009;108:946-951.

Acknowledgments. This work was funded by the Scientific Research Projects Coordination Unit of Abant Izzet Baysal University (project no.: 2018.06.02.1290). The authors deny any conflicts of interest related to this study.

Conflict of Interests: Nothing to declare.
Financial Disclosure Statement: Nothing to declare.
Human Rights Statement: None required.
Animal Rights Statement: None required.

Received on March 29, 2021.
Revised on June 12, 2021.
Accepted on September 20, 2021.

Correspondence

Neslihan Büşra Keskin
Department of Endodontics, Faculty of Dentistry
Yıldırım Beyazıt University, Turkey
e-mail: ozerolbkeskin@gmail.com