



CASE REPORT

doi: 10.18575/msrs.sm.e.17.21
UDC 616.12-089.84
COBISS.RS-ID 6837016

Left Ventricular Assist Device Implantation as Bridge to Heart Transplantation

ABSTRACT

Heart transplantation is a method of choice for the surgical treatment of a terminal stage of cardiac insufficiency. The lack of donors that all health systems in the world are experiencing has led to the intensive development of devices for permanent mechanical support of circulation. Implantable devices, such as the LVAD circulation pump, are widely accepted as a therapeutic option for improving the quality of life and survival of patients with terminal heart failure. Indications for incorporation include bridge to transplant (BTT), bridge to candidacy (BTC) and destination therapy (DT). The article presents a case of successful surgical treatment of terminal heart failure. The patient was implanted with a circular support device for left heart chamber for the maintenance of vital parameters and bridging the period to heart transplantation.

Key words: LVAD, heart transplantation, bridge to transplantation, Heart Ware

(*Scr Med 2017;48:141-144*)

**Duško Terzić¹,
Svetozar Putnik¹,
Emilija Nestorović¹,
Dejan Marković¹,
Miljko Ristić¹**

¹ The Heart Transplantation Unit,
LVAD and ECMO, Clinic for Cardiac
Surgery, Clinical Center of Serbia

Contact address:

Duško Terzić,
Clinic for cardiac surgery, Clinical
Center of Serbia
Street address: Dr. Koste
Todorovića 8
11000 Beograd, Serbia
e-mail: terzic.dusko@gmail.com
phone number: +381-66-830-1966

Submitted: June 20th, 2017
Accepted: July 11th, 2017

Introduction

Devices for permanent mechanical circulatory support (MCS) are widely used today due to the limited number of available donors and the limited effectiveness of conservative clinical methods in order to provide an adequate therapeutic response in terminal cardiac failure. In practice, the left ventricular support devices are mostly used, but the MCS concept also includes devices for supporting the right chamber, devices for biventricular support and total artificial heart.¹

Case Report

A left ventricular assist device was implanted in a 29-year-old patient with a medical history of cardiomyopathy of an unknown cause, diagnosed eight years ago. Five years earlier, the patient underwent radiofrequency ablation, and four years earlier, CRT-P was implanted. Ten days

prior to the admission, the patient was hospitalized at the regional health center after a heart failure due to ventricular fibrillation and a successful reanimation procedure. At the time of the admission to our clinic, the patient showed signs of dyspnea and anxiety, he was in a state of cardiac decompression with low impact volume and progressive multiple organ dysfunction despite all the therapeutic measures taken. The patient was categorized as NYHA Class IV, INTERMACS Class 3.

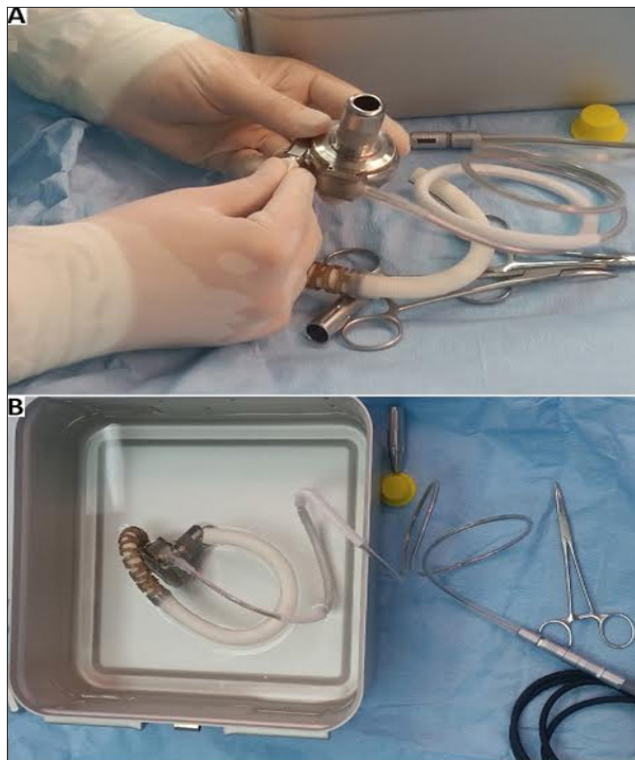
The echocardiographic finding upon the admission showed a normal diameter of aorta in a bulb with an aortic valve which has three cusps and a trace of AR. A dilated left ventricle (7.8/7.0cm), globally hypocontractile, with normal wall thicknesses, decreased total systolic function (EF by Teicholz 22%, by Simpson 10%) and paradoxical septum movements was verified. The mitral apparatus

had a regular morphology, with a mild MR 1+ in the left atrium of regular dimensions. The right chamber was of regular size, with good systolic and longitudinal functions, TAPSE 25 mm, FAC 38%. A TR trace was registered through the tricuspid valve. The right heart pressure of 21 mmHg was indirectly assessed.

After prioritized diagnostic procedures, it was found that the patient was a candidate for heart transplantation. Taking into consideration that at that moment there was no available donor, a decision was made to implant a left ventricular assist device (LVAD).

After medial sternotomy and heparinization, an extracorporeal blood flow-cardiopulmonary bypass was used up to the time of achieving an adequate active coagulation time (480 s). The LVAD device was prepared in sterile conditions for implantation (fused components and rinsing and de-irrigation). (Figure 1)

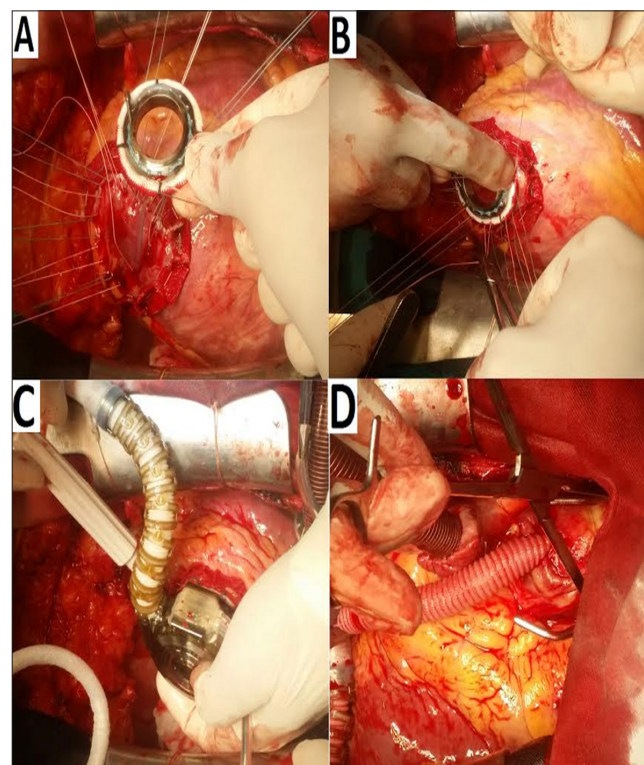
Figure 1. Sterile preparation of the Heart Ware device:
A-Connecting the outlet graft with the pump, B-Rinsing the pump which is connected to the power source by the cable within the preparation for implantation



The Heart Ware device was implanted without the aortic banding and heart stopping. The inlet cannula was installed at the top of the left ventricle by the pre-fixed fixation ring. The power supply cable was in the form of a double tunnel through the skin in the left upper

quadrant of the abdomen and connected to the source of energy. The outlet graft pump was fastened to the ascendant aorta. The device was completely placed in the pericardial and there was no need for opening the pleural or peritoneal space. After the deaeration, the pump was started and the patient was gradually separated from the extracorporeal bloodstream machine. (Figure 2)

Figure 2. Installation of LVAD: A-fastening of the fixation ring to the top of the left ventricle, B-ring fastening to the previously echocardiographically confirmed location (orientation of the inlet cannula to the mitral valve), C-after the circular opening of the left ventricle, the ring pump was fixed and hemostasis checked, D-outlet graft fastened to the ascendant aorta.



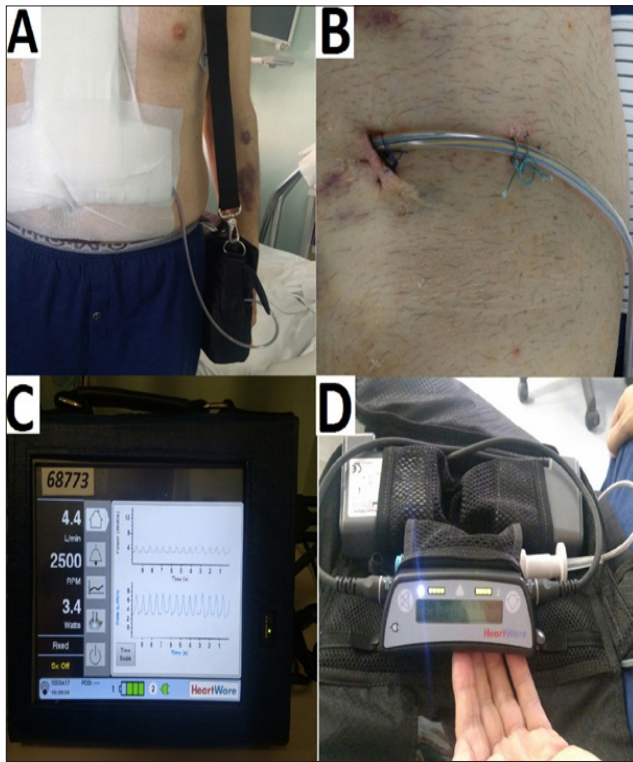
The post-operative course was without complications. Rhythmic cardiac action with clear LVAD pump noise without variations in intensity was confirmed by auscultation. The patient was fully activated in the postoperative period. Laboratory and radiological analyzes were in reference values. (Figure 3)

Training of patients and members of his family was carried out regarding the hygiene of the exit point of the power supply cable and the interpretation of the basic findings and alarm at the pump controller.

Echocardiography at the discharge registered left ventricle increased in size, volume relieved compared to

the preoperative findings, EDD 7.3 cm, 6.6 cm ESD with mild MR 1+ in the left atrium of normal dimensions of 3.4 cm. Right chamber was of regular dimensions of 2.0 cm, good systolic and longitudinal functions TAPSE 17 mm, Sm Tricuspid anus 7 cm / s. PG 20 mmHg, SPDK 30 mmHg. A flow through the tricuspid valve was 0.83 m/s. Mild to moderate TR 1-2+ was observed. Inlet cannula of the pump was of excellent color with a flow rate of 1.68 m/s. Outlet cannula was of excellent color with a flow rate of 1.24 m/s.

Figure 3. External components of the Heart Ware device: A-patient after surgery - outlet power cable connected to the controller and batteries in the bag, B-exit point of the power cable on the skin that is daily dressed, the C-monitor system (a fixed part when a patient is in bed) which showed pump parameters, D-controller and batteries stored in the bag were visible



The pump speed was set at 2500 rpm, the pump flow up to 4.9 L / min, the pump power at 3.4 W and Hematocrit was 32%. The alternate controller was also set at a speed of 2500 rpm.

A month later, the patient was discharged. Anticoagulant therapy upon the discharge included Warfarin with clavulan INR of 2-3, as well as a preparation of Acetylsalicylic acid with a dose of 100 mg per day. His other medications (from the last check-up four months ago) included Ramipril 5mg daily, Amlodipine Besylate 5

mg daily, spironolactone 25 mg daily, Furosemide 20 mg twice a day, Pantoprazole 40 mg twice a day, Amiodarone 200mg daily, Levothyroxine 50 mcg daily, Atorvastatin 20 mg daily.

During the check-ups after a month, two months, six months and a year, the patient did not show signs of heart failure and the LVAD parameters on the controller were stable. The patient is on the heart transplant waiting list in the Republic of Serbia.

Discussion

Implantation of the LVAD, apart from being a life-saving treatment for patients, allows a large number of patients in the terminal stage of heart failure to live long enough and to have a good quality of life prior to the heart transplantation (bridge to transplantation in cases when patients are candidates for Htx) or to have an acceptable quality of life with a built-in device as a definitive therapy (for patients who are not candidates for HTx). In fewer cases, cardiac function occurs after the installation device and then the device is explanted (bridge to recovery).

Implantation of the LVAD, on the basis of previous results, has been recognized as a valuable alternative to cardiac transplantation. Furthermore, the need for heart transplantation as a first-choice therapy can be reduced when taking into account the post-transplant survival results in a group of patients who had the LVAD implanted as a bridge to transplantation.²

The number of LVAD devices implanted in the world has been steadily increasing due to a significant improvement in survival rates in recent years. New systems are easier to implant, longer-lasting, patients have a "customized" normal life in their homes while they wait for a cardiac transplantation or they carry the LVAD as a definitive therapy.³

The Heart Ware support system of the left ventricle is a centrifugal pump of a miniature design that achieves a continuous blood flow of up to 10 liters per minute. An optimized blood flow is accomplished using a hybrid magnetic hemodynamic, hemocompatible and centrifugal system. The Heart Ware pump that is implanted at the top of the left ventricle and whose outlet graft is connected to the aorta is connected to the controller and the source of energy (batteries) through a thin flexible power cable. The cable is most commonly carried out through the skin in the left upper quadrant of the abdomen. The pump controller is a device that enables precise estimation of a flow and memorizes significant hemodynamic parameters on the basis of which the pump operation is adjusted.⁴ (Figure 3)

The challenge that multi-disciplinary teams involved in the diagnosis and treatment of terminal heart failure are faced with lies in the identification of patients who can benefit from the implantation of the LVAD, taking into account the possibilities of a heart transplant and appropriate timing of implantation. The decision is made on the basis of clinical parameters, conducted examinations according to protocols and operational risk assessments.⁵

Conservative treatment measures in the case of patients who is the subject of the case report, with heart indulgence along with multiple organ dysfunction in the progression, have not yielded satisfactory results. Echocardiographic analysis showed a weakened function of the left ventricle with a preserved function of the right ventricle of the heart, which is one of the prerequisites for successful post-implantation outcome. Since there was no adequate donor, in order to maintain vital parameters, it was decided to implant the LVAD device as a bridge to heart transplantation. The procedure continued without any complications and the patient was discharged after one month. All check-ups during the period of one year after the implantation showed a regular hemodynamic status, the patient is fully physically active and on the heart transplant waiting list.

Conclusion

The use of left ventricular assist device as a bridge to transplantation continues to demonstrate a high rate of one-year survival with satisfactory post-implantation quality of life. The incidence of complications is reduced

compared to previous devices evaluated in earlier studies, although the period of use of the pump is prolonged.

References

1. Khazanie P, Rogers JG. Patient selection for left ventricular assist devices. *Congest Heart Fail.* 2011;17(5):227–34. <https://doi.org/10.1111/j.1751-7133.2011.00236.x> PMID:21906247
2. Takeda K, Takayama H, Kalesan B, Uriel N, Colombo PC, Jorde UP, et al. Long-term outcome of patients on continuous-flow left ventricular assist device support. *J Thorac Cardiovasc Surg* 2014; 148: 1606–1614. <https://doi.org/10.1016/j.jtcvs.2014.04.009> PMID:25260275
3. Rodriguez LE, Suarez EE, Loebe M, et al. Ventricular assist devices (VAD) therapy: new technology, new hope? *Methodist DeBakey Cardiovasc J.* 2013;9:32–7. <https://doi.org/10.14797/mdcj-9-1-32> PMID:23519193 PMID:PMC3600882
4. Slaughter, M.S., Pagani, F.D., McGee, E.C. et al. HeartWare ventricular assist system for bridge to transplant: combined results of the bridge to transplant and continued access protocol trial. *J Heart Lung Transplant.* 2013; 32: 675–683 <https://doi.org/10.1016/j.healun.2013.04.004> PMID:23796152
5. Ammirati E, Oliva F, Cannata A et al Current indications for heart transplantation and left ventricular assist device: a practical point of view. *Eur J Intern Med* 2014;25(5):422–429 <https://doi.org/10.1016/j.ejim.2014.02.006> PMID:24641806

Ugradnja uređaja za trajnu cirkulatornu potporu lijeve komore kao most do transplantacije srca

SAŽETAK

Uvod: Transplantacija srca je metoda izbora za hirurško liječenje terminalnog stadijuma srčane insuficijencije. Nedostatak donora sa kojim se susreću svi zdravstveni sistemi u svijetu uslovio je intenzivan razvoj uređaja za trajnu mehaničku potporu cirkulacije. Implantabilni uređaji, poput pumpe za mehaničku potporu cirkulacije lijeve komore (LVAD), široko su prihvaćeni kao terapijska opcija za poboljšanje kvaliteta života i preživljavanje bolesnika sa terminalnom srčanom slabošću. Indikacije za ugradnju uključuju premošćavanje perioda do transplantacije, premošćavanje perioda do oporavka srčane funkcije i ugradnju kao definitivnu terapijsku opciju. U članku je prezentovan slučaj uspješnog hirurškog liječenja terminalnog srčanog popuštanja. Bolesniku je implantiran uređaj za cirkulatornu potporu lijeve komore Heart Ware u cilju održavanja vitalnih parametara i premošćavanja perioda do transplantacije srca.

Ključne riječi: LVAD, transplantacija srca, most do transplantacije, Heart Ware