



The Value of Dynamic Contrast-Enhanced MRI and Diffusion-Weighted Sequence in the Evaluation of Endometrial Lesions

Lina Saad Jaafar Al-Zubaidi,¹ Salam Mohammad Joori,² Hiba Mohammed Abdulwahid³

Abstract

Background/Aim: Endometrial abnormalities represent a diagnostic challenge due to overlapping imaging features with normal endometrium. Aim of this study was to assess accuracy of dynamic contrast-enhanced and diffusion-weighted magnetic resonance imaging (MRI) in evaluation of endometrial lesions in comparison with T2 and to assess local staging validity and degree of myometrial invasion in malignancy.

Methods: Forty patients with abnormal vaginal bleeding or sonographic thickened endometrial were recruited. MRI examination of pelvis was performed using 1.5 T scanner with a pelvic array coil. Conventional T1-and T2, dynamic contrast-enhanced (DCE) sequences and diffusion-weighted image (DWI) were performed.

Results: Mean age of patients was 53.2 years and 60 % of patients complained of post-menopausal bleeding. Irregular margin, type III enhancement curve, a high signal in T2WI and DWI and low signal of apparent diffusion coefficient (ADC) were significantly associated with malignancy. The optimum ADC threshold value for distinguishing benign from malignant endometrial lesions was $0.905 \times 10^{-3} \text{ mm}^2/\text{S}$, with 95.5 % sensitivity and 92.9 % specificity. DWI was most sensitive to malignant endometrial lesions, followed by DCE (89.6 %, 98.4 %) and T2 (86.7 %, 91.4 %). DWI and DCE staging correlated with FIGO staging ($p = 0.0001$ and $p = 0.019$, respectively). DWI had the best sensitivity for myometrial invasion (95.6 %), followed by DCE (91.9 %) and T2WI (90.1 %). All three sequences had 89.7 % specificity.

Conclusion: DWI and DCE MRI were superior to conventional MRI at distinguishing malignant from benign endometrial lesions and can improve myometrial invasion depth evaluation and therapy planning when combined with morphological T2WI. ADC cutoff at a high b value improved MRI diagnostic sensitivity and specificity.

Key words: MRI; Dynamic contrast enhancement; Diffusion-weighted images; Endometrial lesions; Benign; Malignant; Myometrial invasion.

1. Radiology Department, Yarmouk Teaching Hospital, Baghdad, Iraq.
2. Radiology Institute, Medical City, Baghdad, Iraq.
3. Radiology Department, College of Medicine, University of Baghdad, Baghdad, Iraq.

Citation:

Al-Zubaidi LSJ, Joori SM, Abdulwahid HM. The value of dynamic contrast-enhanced MRI and diffusion-weighted sequence in the evaluation of endometrial lesions. *Scr Med.* 2024 Jan-Feb;55(1):13-22.

Corresponding author:

HIBA MOHAMMED ABDULWAHID
E: hibamohamedresearch@gmail.com

Received: 17 November 2023

Revision received: 21 January 2024

Accepted: 21 January 2024

Introduction

Endometrial abnormalities represent a significant diagnostic challenge for radiologists. This may be attributed to the potentially overlapping imaging

features of the normal endometrium influenced by the menstrual phase in addition to variable benign and malignant endometrial lesions

including submucosal fibroid, endometrial polyp, endometrial hyperplasia and endometrial neoplasms. Ultrasonography (US) and endometrial biopsy have been the gold standard for identifying endometrial abnormalities prior to surgery. Sonographic observations of endometrial thickness, heterogeneity and a focal endometrial lesion are non-specific, with probable interference between malignant and benign illnesses and must be considered in conjunction with the patient's age, symptoms and hormonal state.¹ Endometrial curettage or biopsy should be performed in these circumstances for a definitive diagnosis.² However, since these tests are typically performed blindly, it is not always possible to provide an accurate diagnosis.³

The International Federation of Gynaecology and Obstetrics (FIGO) approach, which is used to stage endometrial cancer (EC) was recently revised.⁴ The most important morphologic prognostic indicator is the depth of myometrial invasion, which correlates with the tumour grade, the presence of lymph node metastases and overall patient survival. Magnetic resonance imaging (MRI) can reliably identify the depth of myometrial invasion, whereas endometrial biopsy can determine the histologic grade. The myometrial extension is a reliable index of lymphatic spread. The prevalence of lymph node metastases increases from 3 % with superficial myometrial invasion to 46 % with deep myometrial invasion.⁵ Patients with lymph node metastases have a significantly higher recurrence rate and a lower 5-year survival rate than those without lymph node metastases.⁶ More advanced diseases, such as cervical stromal invasion or adnexal involvement, can be accurately assessed by MRI. Additional information from an MRI staging assessment (eg uterine size, tumour size, presence of ascites or adnexal illness) may aid in determining whether surgery should be trans-abdominal, transvaginal or laparoscopic.⁷

Diffusion-weighted and dynamic multiphase contrast-enhanced MRI sequences have been found to increase MR imaging accuracy in measuring the depth of myometrial invasion. These sequences can be used to monitor tumour response to therapy and differentiate tumour recurrence from post-treatment alterations.⁷ The purpose of this study was to evaluate the diagnostic performance of dynamic contrast-enhanced MRI and diffusion-weighted sequence in the evaluation and characterisation of endo-

metrial lesions in comparison with morphological T2-weighted image, as well as the degree of myometrial invasion in malignant-appearing lesions in these sequences.

Methods

This was a prospective analytic study carried out in the Radiology Department of Oncology Teaching Hospital/Medical City Complex in Baghdad, Iraq during the period from 1 December 2020 to December 2021.

Included patients were referred from the gynaecological department in Baghdad teaching Hospital/Medical City with abnormal vaginal bleeding (post-menopausal, peri-menopausal, pre-menopausal bleeding, postcoital bleeding and/or abnormal vaginal discharge), abnormal endometrial pathology or endometrial thickening by transvaginal and/or abdominal ultrasound. Endometrial thickening was defined as an increase of the endometrial thickness over 5 mm in post-menopausal women and an increased thickness of endometrium non-compatible with the expected thickness in proliferative or secretory phases in reproductive women) decided by a clinician according to clinical and sonographic findings). Patients with previous surgical history for uterine/endometrial pathology and EC treated previously with suspected recurrence or adenomyosis were excluded. Patients with general contraindications for MRI and those who did not fit within the MRI gantry, had severe motion artifact and degraded MRI and did not have diffusion-weighted image (DWI) or dynamic contrast-enhanced (DCE) or histopathology report were not included in the study.

Clinical and demographic information was recorded for each patient using a prepared case sheet. The final diagnosis of the patients was based on the histopathological results of the material obtained after surgery and/ or dilation and curettage (D and C).

MRI protocol

The patients were asked to fast for about 4 to 6 h before the examination as part of preparation. Pelvic MRI was performed using a (*Siemens Healthineers: MAGNETOM Aera*, Erlangen,

Germany, 1.5 T) with both conventional MRI sequences and dynamic contrast enhancement (CE) MRI, in addition to the DWI sequence in pre-contrast images. All the patients were imaged in the supine position using a pelvic array coil, with the arms along their body and were instructed not to move during the examination. Axial, coronal and sagittal localiser images were captured, then fast spin echo (FSE) T1-weighted (TR 500 ms, TE 10 ms, matrix 320,512, slice thickness: 5 mm with an interslice gap of 1–2 mm, FOV 300 mm and a flip angle of 90 degrees) in the axial, oblique and sagittal plane followed by FSE T2-weighted images (TR 1400 ms, TE 93 ms, matrix 256,512, slice thickness: 5 mm with an interslice gap of 3–4 mm, FOV 200–240 mm and a flip angle of 90 degrees) in the axial oblique and sagittal plane. Image acquisition was optimised and perpendicular to the endometrium for T2WI. To get axial oblique images of a tilted uterus, “double oblique images” at an angle in both the sagittal and coronal planes produce a “true oblique” that is orthogonal to the endometrium. These pictures were taken perpendicular to the parasagittal T2-weighted MR imaging and were centred on the imaging plane in which the endometrium was clearly seen.

CEMRI procedure

After manually injecting 0.1 mmol/kg gadopentetate dimeglumine (*Magnevist*) intravenously (iv), volumetric interpolated breath-hold examination (VIBE) was used for 4–5 min of sagittal dynamic MR imaging. Images were taken at 30, 70, 120 min and 4–5 min following iv contrast administration. In the first 30 s after contrast material administration, “the arterial phase” revealed the sub-endometrial zone, which enhanced earlier than the myometrium and corresponds to the inner junctional zone (JZ). Early myometrial invasion detection requires identifying this zone.⁸ In “the venous phase” (70 s), the tumour-inner myometrium contrast peaks, revealing the superficial layer. “The parenchymal phase” (120 s) (equilibrium phase) which is considered excellent for assessing the tumour against myometrial and deep myometrial invasion was carefully examined since the difference in enhancement between the tumour and the outer myometrial muscle layer peaks at this phase. Four to five min after contrast material delivery, “the delayed phase”, allowed cervical stromal invasion measurement in sagittal planes with the same settings as unenhanced T1-weighted spin-echo imaging. A high-signal-intensity (SI)

mass in the endo-cervical canal or disruption of the typical low-signal cervical stroma indicated uterine cervix infiltration.

Diffusion-weighted image (DWI)

All examinations included a fat-suppressed single-shot echo-planar DWI sequence of the pelvis employing tridirectional motion-probing gradients with b-values of 0, 400 and 800 s/mm² (with an inline reconstruction of the apparent diffusion coefficient (ADC) map and the following parameters: TR/TE 2100–2500/76–82 ms; slice thickness 6–8 mm; FOV 350 mm with 75–80 % rectangular FOV; matrix 144 x 192; 3 signal averages; receiver bandwidth 1300 Hz/voxel.

Interpretation

Two senior radiologists blinded to the pathology analysed images on the workstation. T2-weighted images were evaluated for tumour signal intensity in relation to the surrounding endometrium and myometrium. An EC tumour appeared as a diffuse or focal soft tissue mass within the endometrial cavity with heterogeneous intermediate SI relative to the hyperintense normal endometrium and hypointense myometrium. The JZ was visible as a band of low signal intensity immediately subjacent to the endometrial stripe. In cases with a focal endometrial lesion, the maximal endometrial thickness on sagittal T2-weighted images and the maximal focal endometrial abnormality diameter in any plane was recorded. The minimal transverse diameter cutoff value of 10 mm indicated enlarged pelvic and/or para-aortic lymph nodes. The T1WI was checked for haemorrhage and necrosis inside the endometrial cavity or related to the lesion to be avoided while calculating DWI ADC values or DCE enhancement curves. Lesions were then examined visually on DWI/ADC, compared to the myometrium. The lesions either had low signal intensity on diffusion images and high signal in the accompanying ADC maps (facilitated diffusion) or high signal intensity on diffusion images and low signal in the ADC maps (restricted diffusion). Compared to normal outer myometrium, DWI was higher and the ADC signal was lower. The ADC value was automatically calculated after manually drawing the region of interest (ROI) within the lesion's most restricted part. Three ADC measurements per lesion were averaged and expressed in a value of 10⁻³ mm²/s. Similarly, an ROI was manually created on the lesion's most enhancing area in the dynamic phase. Type I, II and III enhancement curves were created from the time

– SI curve. Each subject had two parallel/similar curve measurements. According to delayed phase enhancement, persistent Type I curves (continuous increase in signal intensity on each successive contrast-enhanced image), plateau Type II curves (initial increase in signal intensity followed by a flattening of the enhancement curve) and washout Type III curves (rapid rising curve and rapid wash out).

Statistical analyses

Data was analysed using Statistical Package for Social Sciences (SPSS) version 26. Continuous data were presented in simple measures of frequency, percentage, mean, standard deviation and range (minimum-maximum values). The significance of the difference in different percentages (qualitative data) was tested using the Pearson Chi-square test. Statistical significance was considered whenever the p-value was equal to or less than 0.05.

Results

A total of 40 female patients were recruited in this study. The mean age of the patients was 53.2 ± 9.5 years and 65 % were middle age (41-60 years) (Table 1). The majority (92.5 %) were married and 57 % were postmenopausal. The main presenting complaint was vaginal bleeding, only 15 % had postcoital bleeding (Table 1). Half of the patients underwent hysterectomy and the other half had curettage.

According to histopathological results of the endometrial lesions, there were 25 benign endometrial lesions (19 patients had benign endometrium hyperplasia and 6 patients had benign polyp) and 15 malignant endometrium lesion (10 patients with adenocarcinoma, 2 patients had squamous cell carcinoma, 1 patient for each of adenosquamous carcinoma, endometrioid carcinoma and sarcoma).

Association between MRI appearance and endometrial lesion nature

The majority of the benign endometrial lesion had a type I enhancement curve whereas the type III curve was the dominant type in the malignant lesions, $p = 0.0001$ (Table 2, Figure 1E and J). Regarding signal intensity in T2WI, there was a statistical association between high T2

Table 1: Demographic characteristics of participants

Demographic characteristics	N	%
Age		
≥ 40 years	4	10.0
41-60 years	26	65.0
> 60 years	10	25.0
Mean ± SD	53.2 ± 9.5	
Marital status		
Married	37	92.5
Single	3	7.5
Menopausal status		
Postmenopausal	23	57.5
Premenopausal	17	42.5
Clinical presentation		
Postcoital bleeding	6	15.0
Perimenopausal bleeding	11	27.5
Postmenopausal bleeding	23	57.5
Surgery type		
D and C	20	50.0
Hysterectomy	20	50.0
Total	40	100.0

D and C: dilation and curettage;

Table 2: The association of the MRI signals, enhancement curve and lesion morphology with the type of the endometrial lesion

Signal	Endometrium lesion n (%)		p-value
	Benign (n = 25)	Malignant (n = 15)	
Enhancement curve			
I	20 (80.0)	2 (13.3)	0.0001
II	3 (12.0)	1 (6.7)	
III	2 (8.0)	12 (80.0)	
T2 signal			
High	3 (12.0)	6 (40.0)	0.0390
Intermediate	6 (24.0)	6 (40.0)	
Low	10 (40.0)	1 (6.7)	
Mixed	6 (24.0)	2 (13.3)	
DWI signal			
High	6 (24.0)	12 (80.0)	0.0030
Intermediate	12 (48.0)	2 (13.3)	
Low	7 (28.0)	1 (6.7)	
ADC signal			
High	20 (80.0)	1 (6.7)	0.0001
Intermediate	0 (0.0)	2 (13.3)	
Low	5 (20.0)	12 (80.0)	
Endometrial lesion morphology			
Lesion outline			
Regular	24 (96.0)	5 (33.0)	0.0001
Irregular	1 (4.0)	10 (67.0)	
Focal or diffuse endometrial lesion			
Focal	7 (28.0)	5 (33.0)	0.7210
Diffuse	18 (72.0)	10 (67.0)	

DWI: diffusion-weighted image; ADC: apparent diffusion coefficient;




Figure 1: A-E, A 69 years old female presented with vaginal bleeding; sagittal dynamic contrast-enhanced MRI showed (A) arterial enhancement; (B) venous phase; (C) parenchymal phase; (D) delayed phase showed early enhancement of the mass and (E) post-processing time enhancement curve shows type III curve. Histopathology by total abdominal hysterectomy revealed endometrioid cancer stage Ia. F-J, 51 years female with vaginal bleeding dynamic contrast-enhanced MRI; (F) early arterial enhancement; (G) late arterial phase; (H) parenchymal phase and (I) delayed phase MR showed mild and late enhancement of the mass and (J) post-processing time enhancement curve shows type I curve. Histopathology by dilatation and curettage revealed benign endometrial hyperplasia.

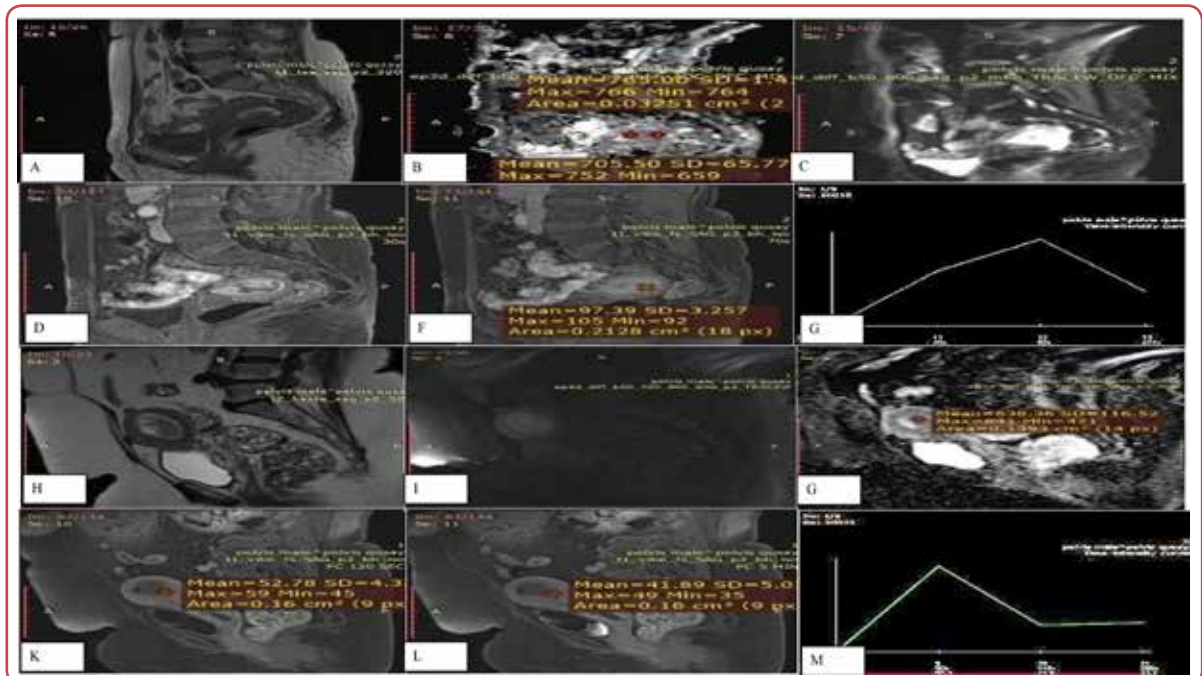


Figure 2: A-G, a 70 years old female with MRI stage T1a (A) T2 WI sagittal MRI the junctional zone is disrupted at the posterior wall with an extension of abnormal signal intensity more than 50 % of the myometrial wall; (B and C) DWI and ADC map shows restriction diffusion with ADC value = 0.76×10^{-3} and also shows disruption of the junctional zone and extension through less than 50 % of myometrial wall (D and F) dynamic contrast series shows extension more than 50 % of the myometrial wall; (E) post-processing time-intensity curve shows type III. The final histopathological stage confirmed a T1a (less than 50 % myometrial invasion). H-M, a 50 years old woman with MRI stage T1b (H). Sagittal T2 shows mixed signal endometrial mass, with deep myometrial invasion; (I) diffusion WI ($b = 800 \text{ s/mm}^2$) showed a homogenous hyper-intense restricted endometrial mass with a sign of deep myometrial invasion; (G) ADC shows the low signal intensity of endometrial mass, ADC value = 6.5×10^{-3} ; (K and L) dynamic contrast series shows deep myometrial invasion; (M) post-processing time-intensity curve shows type III enhancement curve. Final histopathology confirmed Stage Ib endometrial cancer.

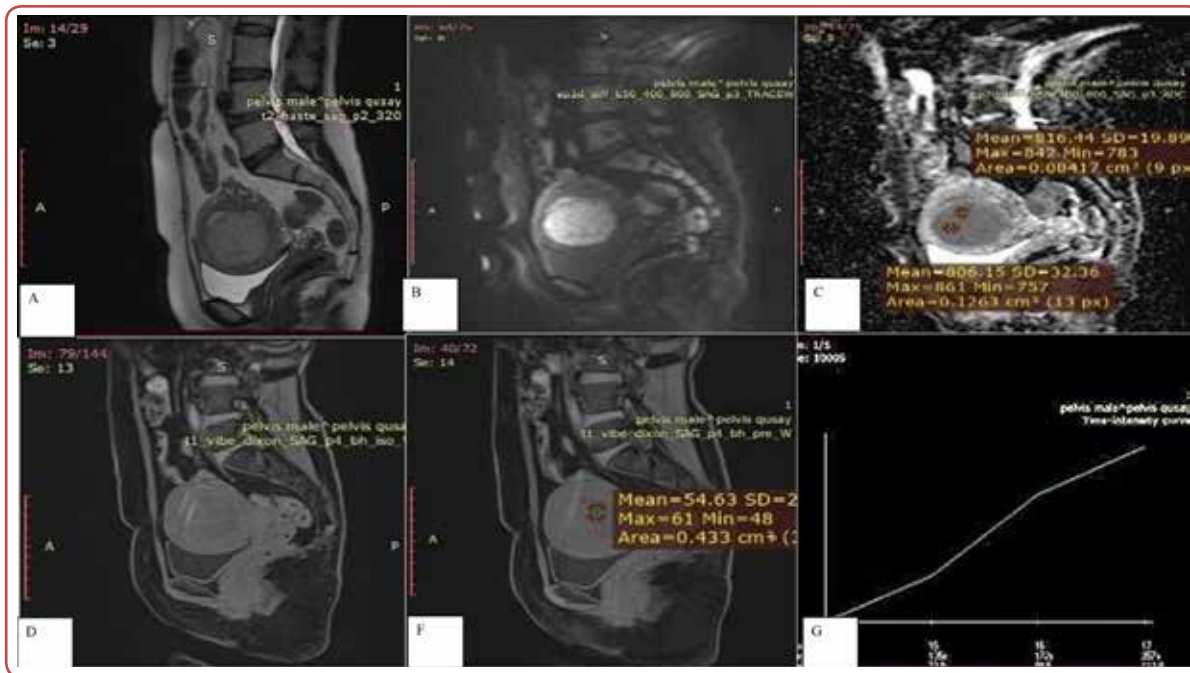


Figure 3: A 50-year-old woman with MRI Stage Ib endometrial cancer. (A) Sagittal T2 shows mixed signal endometrial mass, with deep myometrial invasion; (B) Diffusion WI ($b = 800 \text{ s/mm}^2$) depicted a homogenous hyper-intense restricted endometrial mass with a sign of deep myometrial invasion; (C) ADC show the low signal intensity of endometrial mass with a value of 6.5×10^{-3} . (D and F) dynamic contrast series showed deep myometrial invasion (G) post-processing time-intensity curve shows type III enhancement curve. Final histopathology confirmed Stage Ib endometrial carcinosarcoma.

signal and malignant endometrium in 40 % of the participants while low signals were associated with a benign lesion in 40 % of them, $p = 0.039$ (Figure 1). Similarly, the high signals in DWI were found mostly among malignant lesions, $p = 0.003$, (Figures 1 and 2). While high ADC signals were found among benign lesions (80 %) compared to 80 % of malignant lesions with low signal $p = 0.0001$ (Table 2). The mean ADC value of the benign lesions was $1.137 \pm 0.16 \text{ mm}^2/\text{s}$ ranging between 0.9 to 1.6 which was significantly higher than that of malignant lesions $0.746 \pm 0.12 \text{ mm}^2/\text{s}$ ranging between 0.6-1.0 ($p = 0.025$). The lowest ADC value (0.5×10^{-3}) was seen in carcinosarcoma followed by endometrial carcinoma (Figure 3 G).

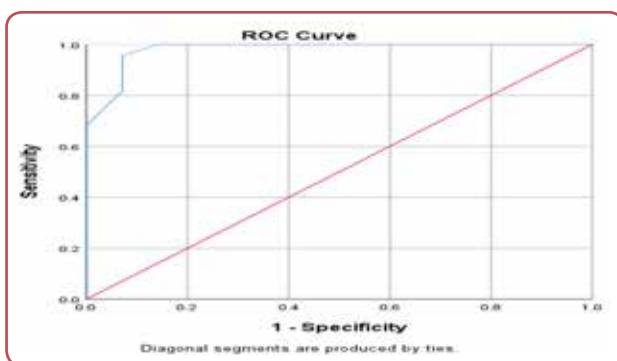


Figure 4: ROC curve comparative diagnostic value of ADC value parameter for discriminating between benign and malignant endometrium lesions

Regarding the lesion's morphology, there was a significant association between the lesion outline lesion nature. About (67 %) of malignant endometrial lesions had an irregular outline compared to (96 %) of benign endometrial lesions which depicted a regular outline with a significant difference ($p = 0.0001$). No significant association was observed between the benign or malignant lesion in terms of diffusion type.

The utility of ADC value in differentiating malignant and benign lesions was tested using the ROC curve. A value of $0.905 \times 10^{-3} \text{ mm}^2/\text{s}$ was suggested to be the optimal cutoff value with a sensitivity of 95.5 % and specificity of 92.9 % as shown in Figure 4.

Diagnostic performance of T2, DWI and DCE MRI in distinguishing between benign and malignant endometrial lesions

DWI had the highest sensitivity (93.3 %) in distinguishing benign from malignant endometrial lesions with the highest negative predictive value (NPV) of 96.2 % followed by DCE and T2 with a sensitivity of 89.6 % and 86.7 %, respectively, while the specificity of DCE, DWI and T2 were 98.4 %, 94.8 % and 91.4 %, respectively as shown in Table 3.

When T2 and DWI were combined, their sensitivity was increased to 95.2 % and the specificity reached 92.7 % with an NPV of 94.3 %. Similarly, when T2+DCE were combined an increase in the sensitivity, specificity, positive productive value and NPV was observed (Table 3).

When it comes to the depth of myometrium invasive, DWI had the highest sensitivity (95.6 %) followed by DCE and T2 with a sensitivity of 91.9 % and 90.1 %, respectively, while the specificity, positive predictive value (PPV) and NPV were very close (Table 3).

Table 3: The sensitivity, specificity, positive predictive value and negative predictive value of MRI sequences in distinguishing benign from malignant endometrial lesions

MRI imaging	Sensitivity	Specificity	PPV	NPV
Endometrium malignancy				
T2	86.70 %	86.70 %	86.70 %	86.70 %
DWI	93.30 %	93.30 %	93.30 %	93.30 %
DCE	89.60 %	89.60 %	89.60 %	89.60 %
T2+DWI	95.20 %	95.20 %	95.20 %	95.20 %
T2+DCE	92.10 %	92.10 %	92.10 %	92.10 %
Myometrium invasive				
T2	90.10 %	90.10 %	90.10 %	90.10 %
DWI	95.60 %	95.60 %	95.60 %	95.60 %
DCE	91.90 %	91.90 %	91.90 %	91.90 %

PPV: positive predictive value; NPV: negative predictive value; DWI: diffusion-weighted image; DCE: dynamic contrast-enhanced;

Table 4: The association of the MRI staging with the histopathological staging among malignant endometrial lesions (n = 15)

MRI stage	Histopathological T stage of malignant lesions (n = 15)				p-value
	T1 (n = 3)	T1a (n = 7)	T1b (n = 3)	T1I (n = 2)	
Stage in T2					
I	0 (0.0)	1 (14.3)	0 (0.0)	0 (0.0)	0.332
Ia	2 (66.7)	1 (14.3)	0 (0.0)	0 (0.0)	
Ib	0 (0.0)	4 (57.1)	3 (100.0)	2 (100.0)	
No	1 (33.3)	1 (14.3)	0 (0.0)	0 (0.0)	
Stage in DWI					
I	2 (66.7)	0 (0.0)	0 (0.0)	0 (0.0)	0.0001
Ia	0 (0.0)	7 (100)	0 (0.0)	0 (0.0)	
Ib	0 (0.0)	0 (0.0.0)	3 (100.0)	2 (100.0)	
No	1 (33.3)	0 (0.0)	0 (0.0)	0 (0.0)	
Stage in DCE					
I	0 (0.0)	1 (14.3)	0 (0.0)	0 (0.0)	0.019
Ia	2 (66.7)	3 (42.9)	0 (0.0)	0 (0.0)	
Ib	0 (0.0)	2 (28.6)	3 (100.0)	0 (0.0)	
II	0 (0.0)	0 (0.0)	0 (0.0)	2 (100.0)	
no	1 (33.3)	1 (14.3)	0 (0.0)	0 (0.0)	
Stage T2 + DWI					
I	3 (100.0)	0 (0.0)	0 (0.0)	0 (0.0)	0.0001
Ia	0 (0.0)	7 (100.0)	0 (0.0)	0 (0.0)	
Ib	0 (0.0)	0 (0.0)	3 (100.0)	2 (100.0)	
Stage T2 + DCE					
I	1 (33.3)	0 (0.0)	0 (0.0)	0 (0.0)	0.008
Ia	2 (66.7)	4 (57.1)	0 (0.0)	0 (0.0)	
Ib	0 (0.0)	2 (28.6)	3 (100.0)	0 (0.0)	
II	0 (0.0)	0 (0.0)	0 (0.0)	2 (100.0)	
No	0 (0.0)	1 (14.3)	0 (0.0)	0 (0.0)	

DWI: diffusion-weighted image; DCE: dynamic contrast-enhanced;

MRI staging and assessment of myometrial invasion in malignant-looking lesion

The association of staging on T2 and histopathology was not significant. There was a strong significant association between histopathology staging and DWI and DCE, $p = 0.0001$ and 0.019 , respectively. On DWI there was 100 % concordance of T1a, T1b and equivalent histopathology stage (Table 4). Combined T2+DWI and T2+DCE showed strong associations pathological staging ($p = 0.0001$ and 0.008 , respectively). Representative cases are illustrated in Figure 2.

Discussion

MRI features relating to both morphology and signal characteristics in conventional MRI sequences are beneficial in the assessment of endometrial lesion's nature and in the early staging of known cancers but their accuracy remained uncertain.⁸ To authors' knowledge, this is the first study in Iraq that evaluated the efficiency of dynamic contrast-enhanced MRI in conjunction with MRI DWI in the assessment of endometrial lesions and assessed its validity in EC staging.

In agreement with other studies, the main referring cause in this study was vaginal bleeding (85 %) and more than half were post-menopausal women. Approximately two-thirds of these cases were histologically confirmed benign lesions. Regular outline morphology and high ADC signal were the most distinct characteristics seen in 96 % and 80 % of benign lesions respectively compared to 33 % and 6.7 % of the malignant lesions. It is widely agreed that the most distinguishing characteristics of benign and malignant endometrial lesions are an irregular outline and a disruptive myometrial-endometrial interface.⁹

High DWI signals and low ADC signals were features of malignancy in presented study, indicating that endometrial malignancy appeared restricted in DWI. Malignant lesions also appear dense in DWI because water molecules cannot pass through their enhanced cellularity. These findings were almost identical to those mentioned by Mansour et al.¹⁰ Endometrial sarcoma had the lowest ADC value (0.5×10^{-3}) in presented study, followed by carcinoma consistent with Fujii et

al findings.¹¹ Qualitative parameters of dynamic contrast-enhanced MRI can be easily applied in daily practice and reflect the kinetic properties of the lesion which include the enhancement curves. Findings in this study revealed that type I enhancement curves were present in the vast majority of benign endometrial lesions (80 %), while type III washout curves were present in only two benign lesions (8 %). Eighty percent of malignant lesions, in contrast, exhibited a type III washout enhancement curve. Al-Shimaa et al¹² reported that the majority of benign endometrial lesions had a type I curve (17/22, 77.2 %), whereas only one lesion displayed a type III curve (4.5 %).

Presented findings indicated that DWI (93.3 %) was more sensitive than T2WI (86.7 %) and DCE (89.6 %) in distinguishing benign from malignant lesions. This was the same conclusion of study by Gharibvand et al¹³ and Masroor et al,¹⁴ the latter of whom reported that DWI is more sensitive to small lesions than T2. Compared to T2WI (91.4 %) and DWI (94.8 %), DCE had the highest specificity (98.4 %). This was higher than Ahmed et al¹² results who reported 91.6 % sensitivity and 88.6 % specificity for DCE and 85.7 % and 95.5 % for DWI.

Variable ADC cut-off values have been suggested to distinguish between benign and malignant endometrial lesions. Presented results revealed that a cutoff value of $0.905 \times 10^{-3} \text{ mm}^2/\text{s}$ had a sensitivity of 95.5 % and specificity of 92.9 %. Latif et al¹⁵ suggested a higher cutoff value of $1.21 \times 10^{-3} \text{ mm}^2/\text{s}$ with a lower sensitivity of 89.5 % and higher specificity (95.5 %). Similarly, Keceli et al¹⁶ and Elsammak et al¹ suggested ($1.10 \times 10^{-3} \text{ mm}^2/\text{s}$) and ($1.19 \times 10^{-3} \text{ mm}^2/\text{s}$) respectively with 85.7 -88.9 % sensitivity and 92.8-100 % specificity. These differences could be attributed to differences in technical parameters that might influence the ADC value such as different MRI machines, or different b values that were used.

In terms of local staging, the current study revealed a significant correlation between DWI and DCE and FIGO staging. The use of combined T2 and DWI significantly increased the accuracy of the MRI staging. In agreement with that, several studies concluded that the combination of T2WI and DWI can replace DCE imaging as the patient's primary imaging modality with EC.¹⁷⁻¹⁹

Regarding myometrial invasion, presented study found that DWI was more sensitive (95.6 %) to

myometrium invasion similar to other studies.¹⁷ Lower DCE sensitivity in the evaluation of myometrial invasion may be attributable to thinning inner myometrium, which makes the differentiation between inner and outside myometrium less apparent because most of presented patients were postmenopausal. The diagnostic accuracy of combined DWI+T2WI and DCE-T2WI was superior to that of T2WI alone, consistent with the findings of Gil et al.²⁰

Conclusion

DWI and DCE MRI differentiated malignant endometrial lesions better than conventional MRI. Qualitative time-intensity enhancement curves and ADC cutoff thresholds for high b values in pelvic MRI help distinguish benign and malignant endometrial lesions with good diagnostic sensitivity and specificity. A combination of DCE or DWI with morphological T2WI showed improved diagnostic performance in assessing myometrial invasion depth and played a crucial role in preoperative assessment and local staging of EC, enabling proper therapy planning.

Ethics

The study was approved by the Scientific Council of the Arab Board of Medical Specialisation for diagnostic radiology (registration No EAC- 20453, dated 1 September 2020). Written informed consent was obtained from patients prior to their participation in the study and for publishing of the anonymised data. The study was organised and implemented based on the adherence to the Ethical Principles for Medical Research Involving Human subjects (The Declaration of Helsinki, 8th Revision, 2013).

Acknowledgement

None.

Conflicts of interest

The authors declare that there is no conflict of interest.

Funding

This research received no specific grant from any funding agency in the public, commercial, or not-for-profit sectors.

Data access

The data that support the findings of this study are available from the corresponding author upon reasonable individual request.

Author ORCID numbers

Lina Saad Jaafar Al-Zubaidi (LA):
0009-0005-9856-9768
Salam Mohammad Joori (SJ):
0009-0002-3750-7991
Hiba Mohammed Abdulwahid (HA):
0000-0001-9517-3737

Author contributions

Conceptualisation: LA, SJ, HA
Methodology: LA, SJ, HA
Software: LA, HA
Validation: LA, HA
Formal analysis: LA, HA
Investigation: LA, SJ, HA
Resources: LA, SJ, HA
Data curation: SJ, HA
Writing - original draft: HA
Writing - review and editing: SJ, HA
Visualisation: LA, SJ
Supervision: LA, SJ, HA
Project administration: LA, SJ
Funding acquisition: None.

References

- Elsammak A, Shehata SM, Abulezz M, Gouhar G. Efficiency of diffusion weighted magnetic resonance in differentiation between benign and malignant endometrial lesions. *Egypt J Radiol Nucl Med.* 2017;48(3):751-9. doi: 10.1016/j.ejrn.2017.02.008.
- Dueholm M, Hjorth IM. Structured imaging technique in the gynecologic office for the diagnosis of abnormal uterine bleeding. *Best Pract Res Clin Obstet Gynaecol.* 2017 Apr;40:23-43. doi: 10.1016/j.bpobgyn.2016.09.010.
- Sadowski EA, Pirasteh A, McMillan AB, Fowler KJ, Kusmirek JE. PET/MR imaging in gynecologic cancer: tips for differentiating normal gynecologic anatomy and benign pathology versus cancer. *Abdom Radiol (NY).* 2022 Sep;47(9):3189-204. doi: 10.1007/s00261-021-03264-9.
- Saleh M, Virarkar M, Bhosale P, El Sherif S, Javadi S, Faria SC. Endometrial cancer, the current International Federation of Gynecology and Obstetrics staging system, and the role of imaging. *J Comput Assist Tomogr.* 2020 Sep/Oct;44(5):714-29. doi: 10.1097/RCT.0000000000001025.
- Berman ML, Ballon SC, Lagasse LD, Watring WG. Prognosis and treatment of endometrial cancer. *Am J Obstet Gynecol.* 1980 Mar 1;136(5):679-88. doi: 10.1016/0002-9378(80)91024-8.
- Kılıç F, Kimyon Cömert G, Akar S, Kılıç C, Çakır C, Yüksel D, et al. Evaluation of peripheral nodal recurrence in patients with endometrial cancer. *J Turk Ger Gynecol Assoc.* 2022 Mar 8;23(1):38-50. doi: 10.4274/jtgga.galenos.2021.2021.0072.
- McEvoy SH, Nougaret S, Abu-Rustum NR, Vargas HA, Sadowski EA, Menias CO, et al. Fertility-sparing for young patients with gynecologic cancer: How MRI can guide patient selection prior to conservative management. *Abdom Radiol (NY).* 2017 Oct;42(10):2488-512. doi: 10.1007/s00261-017-1179-3.
- Matsuo K, Matsuzaki S, Roman LD, Klar M, Wright JD. Proposal of an endometrial cancer staging schema with stage-specific incorporation of malignant peritoneal cytology. *Am J Obstet Gynecol.* 2021 Mar;224(3):319-21. doi: 10.1016/j.ajog.2020.10.045.
- Kierans AS, Bennett GL, Haghighi M, Rosenkrantz AB. Utility of conventional and diffusion-weighted MRI features in distinguishing benign from malignant endometrial lesions. *Eur J Radiol.* 2014 Apr;83(4):726-32. doi: 10.1016/j.ejrad.2013.11.030.
- Mansour TMM, Ahmed YAA-a, Ahmed GAE-R. The usefulness of diffusion-weighted MRI in the differentiation between focal uterine endometrial soft tissue lesions. *Egypt J Radiol Nucl Med.* 2019;50(1):102. doi: 10.1186/s43055-019-0076-x.
- Fujii S, Matsusue E, Kigawa J, Sato S, Kanasaki Y, Nakaniishi J, et al. Diagnostic accuracy of the apparent diffusion coefficient in differentiating benign from malignant uterine endometrial cavity lesions: initial results. *Eur Radiol.* 2008 Feb;18(2):384-9. doi: 10.1007/s00330-007-0769-9.
- Ahmed SA, El Taieb HA, Abotaleb H. Diagnostic performance of sonohysterography and MRI diffusion in benign endometrial lesion characterization. *Egypt J Radiol Nucl Med.* 2018;49(2):579-89. doi: 10.1016/j.ejrn.2018.02.010.
- Gharibvand MM, Ahmadzadeh A, Asadi F, Fazelinejad Z. The diagnostic precision of apparent diffusion coefficient (ADC) in grading of malignant endometrial lesions compared with histopathological findings. *J Family Med Prim Care.* 2019;8(10):3372-8. doi: 10.4103/jfmpc.jfmpc_142_19.
- Masroor I, Zeeshan M, Afzal S, Ahmad N, Shafqat G. Diffusion weighted MR imaging (DWI) and ADC values in endometrial carcinoma. *J Coll Physicians Surg Pak.* 2010 Nov;20(11):709-13. PMID: 21078241.
- Latif MA, Tantawy MS, Mosaad HS. Diagnostic value of diffusion-weighted imaging (DWI) and diffusion tensor imaging (DTI) in differentiation between normal and abnormally thickened endometrium: prospective study. *Egypt J Radiol Nucl Med.* 2021;52:107. doi: 10.1186/s43055-021-00487-0.
- Kececi IS, Nural MS, Aslan K, Danacı M, Kefeli M, Tosun M. Efficacy of diffusion-weighted magnetic resonance imaging in the diagnosis and staging of endometrial tumors. *Diagn Interv Imaging.* 2016 Feb;97(2):177-86. doi: 10.1016/j.diii.2015.06.013.
- Beddy P, Moyle P, Kataoka M, Yamamoto AK, Joubert I, Lomas D, et al. Evaluation of depth of myometrial invasion and overall staging in endometrial cancer: comparison of diffusion-weighted and dynamic contrast-enhanced MR imaging. *Radiology.* 2012 Feb;262(2):530-7. doi: 10.1148/radiol.11110984.
- Nougaret S, Reinhold C, Alsharif SS, Addley H, Arceneau J, Molinari N, et al. Endometrial cancer: combined MR volumetry and diffusion-weighted imaging for assessment of myometrial and lymphovascular invasion and tumor grade. *Radiology.* 2015 Sep;276(3):797-808. doi: 10.1148/radiol.15141212.
- Rechichi G, Galimberti S, Signorelli M, Perego P, Valsecchi MG, Sironi S. Myometrial invasion in endometrial cancer: diagnostic performance of diffusion-weighted MR imaging at 1.5-T. *Eur Radiol.* 2010 Mar;20(3):754-62. doi: 10.1007/s00330-009-1597-x.
- Gil RT, Cunha TM, Horta M, Alves I. The added value of diffusion-weighted imaging in the preoperative assessment of endometrial cancer. *Radiol Bras.* 2019 Jul-Aug;52(4):229-36. doi: 10.1590/0100-3984.2018.0054.