

VIDEO ASISTIRANA TORAKOSKOPSKA RESEKCIJA EKTOPIČNIH MEDIJASTINALNO LOKALIZOVANIH PARATIREOIDNIH ŽLEZDA: ISKUSTVA NAŠEG CENTRA

ORIGINALNI RAD

ORIGINAL ARTICLE

VIDEO ASSISTED THORACOSCOPIC RESECTION OF MEDIASTINAL ECTOPIC PARATHYROID GLANDS: A SINGLE-CENTER EXPERIENCE

Aleksandar Ristanović^{1,2}, Nebojša Marić^{1,2}, Aleksandar Nikolić¹, Stevan Čičić¹

¹ Vojnomedicinska akademija, Klinika za grudnu i kardiohirurgiju, Beograd, Srbija

² Univerzitet odbrane, Medicinski fakultet Vojnomedicinske akademije, Beograd, Srbija

¹ Military Medical Academy, Clinic for Cardiothoracic Surgery, Belgrade, Serbia

² University of Defense, Faculty of Medicine of the Military Medical Academy, Belgrade, Serbia

SAŽETAK

Uvod/Cilj: Većina ektopično lokalizovanih medijastinalnih paratireoidnih žlezda (EMPTŽ) može se uspešno ukloniti cervikalnim pristupom, uključujući i paratireoidne žlezde (PTŽ) smeštene u gornjem medijastinumu. Međutim 1% – 3% pacijenata sa hiperparatireoidizmom (HPT) zahteva grudno hirurški pristup. Uspeh hirurškog lečenja zavisi od što preciznije preoperativne lokalizacije EMPTŽ-a i izbora odgovarajućeg pristupa. Kod ove grupe pacijenata video asistirana torakoskopska ekscizija (engl. *video-assisted thoracoscopic surgery – VATS*) EMPTŽ-a se može koristiti kao pouzdana i bezbedna metoda, kako bi se izbegla potreba za otvorenom hirurgijom, kao i zbog drugih prednosti. Prikazujemo prvih 11 pacijenata sa EMPTŽ-om koji su uspešno operisani na Klinici za grudnu i kardiohirurgiju Vojnomedicinske Akademije (VMA). Nema izveštaja o prethodnim VATS resekcijama EMPTŽ-a u Srbiji.

Materijali i metode: Na Klinici za grudnu i kardiohirurgiju Vojnomedicinske akademije, u periodu između marta 2014. i oktobra 2022. godine, video asistiranom torakoskopskim hirurškim pristupom (VATS) je operisano 11 pacijenata sa ektopično lokalizovanim medijastinalnim paratireoidnim žlezdama. Svi pacijenti su imali biohemijski dokazan hiperparatireoidizam (povišene serumske vrednosti kalcijuma i paratireoidnog hormona). Za preoperativno utvrđivanje lokalizacije ektopičnih žlezda, korišćene su: kompjuterizovana tomografija grudnog koša, *Tc-99m sestamibi* scintigrafija paratireoidnih žlezda i kompjuterizovana tomografija emisijom pojedinačnog fotona (engl. *single photon emission computed tomography – SPECT*).

Rezultati: Uspešno je izvršena ekscizija svih EMPTŽ-a VATS pristupom. Nije bilo potrebe za otvorenim grudno-hirurškim pristupom (sternotomija ili torakotomija). Prosečna dužina trajanja operacije je iznosila 80 minuta (od 34 do 150 min), a prosečna dužina hospitalizacije je bila 7 dana. Kod jednog bolesnika je došlo do razvoja infekcije operativne rane.

Zaključak: Ektopično lokalizovane medijastinalne paratireoidne žlezde mogu biti bezbedno i uspešno ekscidirane korišćenjem VATS pristupa, čime se izbegava klasično otvaranje grudnog koša. VATS obezbeđuje dobru vizualizaciju tumora, malu traumu tkiva, kratko vreme trajanja operacije, kratko vreme bolničkog lečenja, malu učestalost komplikacija i dobar kozmetički efekat.

Ključne reči: video asistirana torakoskopska hirurgija, hiperparatireoidizam, ekscizija paratireoidnih žlezda, ektopične paratireoidne žlezde

ABSTRACT

Introduction: The majority of mediastinal ectopic parathyroid glands (MEPTG) can be successfully removed through the cervical approach, including parathyroid glands (PTG) located in the upper mediastinum. However, 1% – 3% of patients with hyperparathyroidism (HPT) require the thoracic surgical approach. The success of surgical treatment depends on the precise preoperative localization of MEPTGs and on the choice of the appropriate approach. In this group of patients, video assisted thoracoscopic excision of MEPTGs can be used as a reliable method, in order to avoid open surgery, but also because of its other advantages. We present the first 11 patients with MEPTGs who were successfully surgically treated at the Clinic for Cardiothoracic Surgery of the Military Medical Academy (MMA). Previous video assisted thoracoscopic resections in Serbia have not been reported.

Materials and methods: Between March 2014 and October 2022, 11 patients with biochemically proven hyperparathyroidism were surgically treated at the Clinic for Cardiothoracic Surgery of the MMA. MEPTGs were identified preoperatively with a *Tc-99m sestamibi* scan, a CT scan of the chest, and single photon emission computed tomography (SPECT).

Results: All MEPTGs were successfully excised using video assisted thoracoscopic surgery (VATS). There was no need for an open thoracic surgical approach (sternotomy or thoracotomy). The average length of the surgery was 80 minutes (between 34 and 150 minutes). The average length of hospitalization was 7 days. Postoperative wound infection occurred in one patient.

Conclusion: MEPTGs can be safely and successfully excised using VATS, thus avoiding classical chest opening. VATS provides good visualization of the tumor, low tissue trauma, short duration of surgery and hospitalization, a low rate of complications, and a good cosmetic/aesthetic effect.

Keywords: video-assisted thoracoscopic surgery, hyperparathyroidism, excision of parathyroid glands, ectopic parathyroid glands

Autor za korespondenciju:

Stevan Čičić

Vojnomedicinska akademija, Klinika za grudnu i kardiohirurgiju

Crnotravska 17, 11000 Beograd, Srbija

Elektronska adresa: stevanmed@yahoo.com

Corresponding author:

Stevan Čičić

Military Medical Academy, Clinic for Cardiothoracic Surgery

17 Crnotravska Street, 11000 Belgrade, Serbia

E-mail: stevanmed@yahoo.com

Primljeno • Received: May 19, 2023;

Revidirano • Revised: July 5, 2023;

Prihvaćeno • Accepted: July 14, 2023;

Online first: September 25, 2023

DOI: 10.5937/smcl4-45101

UVOD

Prvu uspešnu paratireoidektomiju izveo je, 1925. godine, Feliks Mandel, kao bilateralnu eksploraciju vrata [1]. Indikacije za paratireoidektomiju su primarni i sekundarni hiperparatireoidizam (HPT). Paratireoidne žlezde (PTŽ) se nalaze na vratu i najčešće ih ima četiri. Približno 15% – 20% pacijenata kod kojih je indikovana paratireoidektomija ima ektopično lokalizovane paratireoidne žlezde [2,3]. Ektopična lokalizacija žlezda je posledica njihovog embrionalnog razvitka. Gornje paratireoidne žlezde se razvijaju iz četvrte faringealne kese, dok donje paratireoidne žlezde nastaju iz treće faringealne kese. Zbog toga, tokom embrionalnog razvitka, niže paratireoidne žlezde prelaze veću udaljenost da bi došle u svoj uobičajeni anatomske položaj. Sledstveno, njihova ektopična lokalizacija je dvostruko češća. Pošto se timus takođe razvija iz treće faringealne kese, ektopično lokalizovana donja PTŽ se često može naći u samom timusu ili oko timusa. Kada je gornja PTŽ ektopično lokalizovana, obično se nalazi pored jednjaka, traheje, štitne žlezde i velikih krvnih sudova [4–11]. Većina ektopično lokalizovanih PTŽ-a se može ukloniti cervikalnim pristupom, uključujući i paratireoidne žlezde koje se nalaze u gornjem medijastinumu. Međutim, 1% – 3% pacijenata sa ektopično lokalizovanim medijastinalnim paratireoidnim žlezdama (EMPTŽ) iziskuje grudno hirurški pristup [4–7,12]. Danas se sve češće koriste minimalno invazivne tehnike, kako bi se minimizovala trauma tkiva i smanjile komplikacije operativnog lečenja. Uspeh hirurškog lečenja prvenstveno zavisi od što preciznije preoperativne lokalizacije EMPTŽ-a i izbora odgovarajućeg pristupa. Kod ove grupe pacijenata video asistirana torakoskopska ekscizija (engl. *video-assisted thoracoscopic surgery – VATS*) EMPTŽ-a se može koristiti kao pouzdana i bezbedna metoda, kako bi se izbegla potreba za otvorenom hirurgijom, kao i zbog drugih prednosti.

MATERIJALI I METODE

U periodu od marta 2014. godine do oktobra 2022. godine, na Klinici za grudnu i kardiohirurgiju Vojnomedicinske akademije (VMA), hirurški je lečeno 11 pacijenata sa biohemijski dokazanim hiperparatireoidizmom.

Četiri pacijenta su imala primarni hiperparatireoidizam, šest pacijenata je imalo sekundarni hiperparatireoidizam, a jedan pacijent je imao tercijarni hiperparatireoidizam. Kod 7 pacijenata je prethodno urađena subtotalna paratireoidektomija cervikalnim pristupom (6 pacijenata sa sekundarnim i jedan pacijent sa tercijarnim hiperparatireoidizmom). Preoperativno, svi pacijenti su imali povišen nivo paratireoidnog hormona (PTH), dok su dva pacijenta imala povišen nivo kalcijuma u serumu. Jedan pacijent je imao smanjen nivo serumskog fosfora.

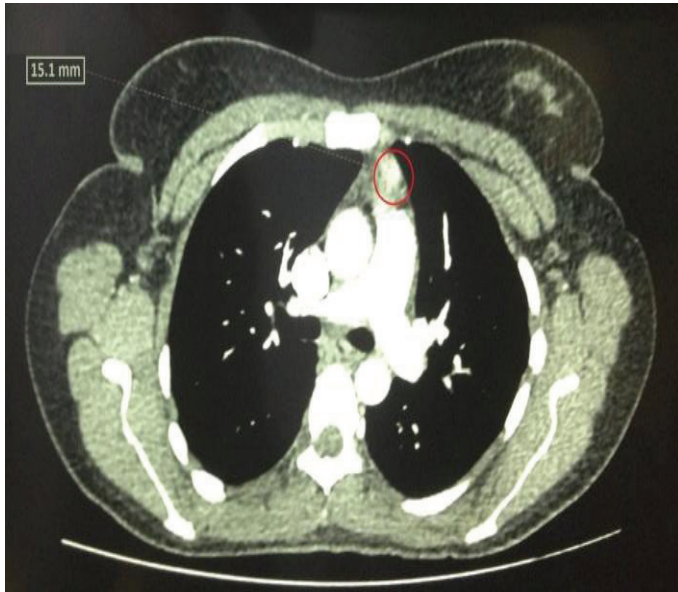
INTRODUCTION

The first successful parathyroidectomy was performed in 1925 by Felix Mandel, as a bilateral neck exploration [1]. Indications for parathyroidectomy are primary and secondary hyperparathyroidism (HPT). Parathyroid glands (PTG) are located in the neck and, most often, there are four of them. Approximately 15% – 20% of patients in whom parathyroidectomy is indicated have ectopically localized PTGs [2,3]. Ectopic localization of glands is a consequence of their embryonic development. The upper PTGs arise from the fourth pharyngeal pouch, while the lower PTGs arise from the third pharyngeal pouch. Therefore, during embryonic development, the lower PTGs travel a greater distance to reach their usual anatomical position. This is why, their ectopic localization is twice as likely. Since the thymus also develops from the third pharyngeal pouch, an ectopically localized lower PTG can commonly be found in the thymus itself or around the thymus. When an upper PTG is ectopically localized, it is usually located next to the esophagus, trachea, thyroid gland and large blood vessels [4–11]. Most ectopically localized PTGs can be removed through the cervical approach, including PTGs located in the upper mediastinum. However, 1% – 3% of patients with mediastinal ectopic parathyroid glands (MEPTG) will require a thoracic surgical approach [4–7,12]. Nowadays, minimally invasive techniques are used more often, in order to minimize tissue trauma and reduce the complications of operative treatment. The success of surgical treatment primarily depends on the precise preoperative localization of MEPTGs and the choice of an appropriate approach. In this group of patients, video assisted thoracoscopic excision of MEPTGs can be used as a reliable and safe method, in order to avoid open surgery (sternotomy and thoracotomy), but also because of its other advantages.

MATERIALS AND METHODS

Between March 2014 and October 2022, 11 patients with biochemically proven hyperparathyroidism were surgically treated at the Clinic for Cardiothoracic Surgery of the Military Medical Academy (MMA).

Four patients had primary hyperparathyroidism, six patients had secondary hyperparathyroidism, and one patient had tertiary hyperparathyroidism. In 7 patients, a subtotal parathyroidectomy had previously been performed through the cervical approach (6 patients with secondary and one patient with tertiary hyperparathyroidism). Preoperatively, all of the patients had elevated levels of the parathyroid hormone (PTH), while two patients had elevated levels of serum calcium. One patient had a decreased level of serum phosphorus.



Slika 1. CT i SPECT nalaz intratimične ektopično lokalizovane medijastinalne paratireoidne žlezde (EMPTŽ)

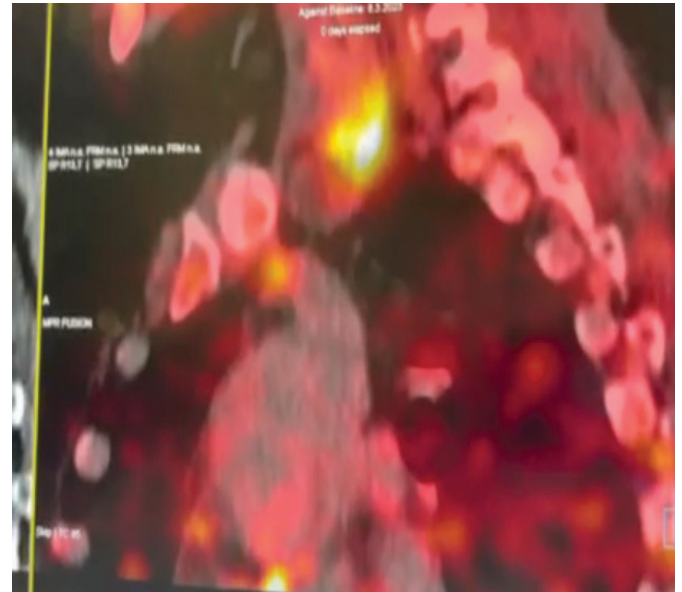


Figure 1. CT and SPECT of an intrathymic mediastinal ectopic parathyroid gland (MEPTG)

Lokalizacija ektopičnih žlezda utvrđena je preoperativno primenom $Tc-99m$ sestamibi scintigrafije paratireoidnih žlezda i kompjuterizovane tomografije (engl. *computed tomography* – CT) grudnog koša, dok je jedan pacijent podvrgnut kompjuterizovanoj tomografiji emisijom pojedinačnog fotona (engl. *single photon emission computed tomography* – SPECT), (Slika 1).

Resekcija EMPTŽ-a je izvedena VATS tehnikom. U zavisnosti od preoperativne lokalizacije žlezda, resekcija VATS tehnikom je izvedena 6 puta na levoj strani i 5 puta na desnoj. U dva slučaja, operacije su izvedene postavljanjem tri porta, u jednom slučaju postavljena su dva porta, dok je u 8 slučajeva postavljen jedan port, kao rezultat našeg sve većeg stečenog iskustva. Portovi su uvek bili plasirani na standardna mesta. Sve hirurške intervencije su obavljene u opštoj anesteziji, uz primenu dvolumenske endotrahealne cevi i jednostrane ventilacije pluća. Pacijenti su postavljani u polusedeći položaj sa ipsilateralnom rukom u abdukciji i peškirom postavljenim ispod iste strane grudnog koša pacijenta, kako bi se stvorio ugao od trideset stepeni između operacionog stola i toraksa. Sve operacije su izvedene uz pomoć standardnog krutog torakoskopa od 10 mm. Ektopično lokalizovane paratireoidne žlezde resekirane su standardnim torakoskopskim instrumentima. Nakon operacije, kroz kaudalni rez je postavljen torakalni dren. Kriterijum koji smo koristili za intraoperativnu potvrdu ekstirpirane paratireoidne žlezde bila je analiza smrznutog preseka uklonjenog tkiva.

REZULTATI

Od 11 pacijenata koji su bili podvrgnuti paratireoidektomiji, bilo je 8 (72,7%) muškaraca. Prosečna starost

The localization of MEPTGs was established preoperatively using the $Tc-99m$ sestamibi scan and computed tomography (CT) of the chest, while one patient underwent single photon emission computed tomography (SPECT) (Figure 1).

Resection of the MEPTGs was performed using the VATS technique. Depending on the preoperative localization of the glands, resection using the VATS technique was performed 6 times on the left side and 5 times on the right. In two cases the operations were performed by placing three ports, in one case two ports were placed, while in 8 cases one port was placed, as the result of our growing experience. The ports were always placed in typical places. All surgical interventions were performed under general anesthesia, using a double-lumen endotracheal tube and single-lung ventilation. The patients were placed in a semirecumbent position with the ipsilateral arm in abduction and a towel placed under the patient's ipsilateral thorax, in order to create a thirty-degree angle between the operating table and the thorax. All operations were performed using a standard 10-mm rigid thoracoscope. Ectopically localized parathyroid glands were resected using standard thoracoscopic instruments. After the operation, a thoracic drain was placed through a caudal incision. The criterion we used for intraoperative confirmation of an extirpated PTG was frozen section analysis of removed tissue.

RESULTS

Among the 11 patients who underwent parathyroidectomy, 8 (72.7%) were male. The mean age of the patients was 52 years. The average length of the sur-

pacijenta je bila 52 godine. Prosečna dužina operacije je iznosila 80 minuta (između 34 i 150 minuta). Svi pacijenti su ekstubirani u operacionoj sali. Nijedan pacijent nije zahtevao boravak u jedinici hirurške intenzivne nege. Torakalni dren je uglavnom uklanjan nakon jednog postoperativnog dana (raspon: 0 dana – 2 dana). Prosečna dvadesetčetvorčasovna drenaža je iznosila 65 ml (opseg: 0 ml – 110 ml). Prosečna dužina hospitalizacije je bila 7 dana (između tri i 15 dana). Jedan pacijent je imao infekciju rane. Kod šest pacijenata je došlo da razvoja postoperativne hipokalcemije koja je zahtevala supstitucionu terapiju kako bi se sprečio sindrom gladne kosti. Infekcija rane i postoperativna hipokalcemija su predstavljale glavne uzroke produžene hospitalizacije. Nije bilo potrebe za otvorenim pristupom pri resekciji EMPTŽ-a. Histološkom analizom utvrđen je adenom paratireoidne žlezde kod tri pacijenta, hiperplazija paratireoidne žlezde kod 7 pacijenata, a kod jednog bolesnika sa sarkoidozom utvrđeno je hronično granulomatozno zapaljenje limfnih žlezda. Srednja vrednost prečnika ekscidiranih žlezda je bila 20 mm, a sve su bile veće od 2 mm u prečniku (opseg: 2 mm – 35 mm). Nakon operacije, nivo kalcijuma u krvi se vratio na normalne vrednosti, prvog postoperativnog dana. Nakon šestomesečnog praćenja, svi pacijenti, osim jednog, imali su normalne vrednosti kalcijuma u krvi. Nivo PTH-a se vratio na normalne vrednosti kod 10 pacijenata. Kod jednog pacijenta nivo PTH-a je ostao povišen, a konačni patohistološki nalaz nije potvrdio paratireoidno tkivo, niti je daljim analizama utvrđen uzrok povišenog nivoa kalcijuma i paratireoidnog hormona.

DISKUSIJA

Uspeh hirurškog lečenja zavisi od što preciznije preoperativne lokalizacije EMPTŽ-a u medijastinumu i izbora najadekvatnijeg pristupa. Metode snimanja koje se koriste za preoperativnu vizualizaciju EMPTŽ-a su sledeće: UZ, CT, Tc-99m sestamibi scintigrafija, magnetna rezonanca, SPECT i dvofazna Tc-99m sestamibi scintigrafija sa SPECT-om. Dijagnostička osetljivost ovih procedura je prikazana u Tabeli 1 [13].

Kod pacijenata sa negativnim nalazom scintigrafije, može se koristiti 4D-CT snimanje za vizualizaciju EMPTŽ-a. Prema jednoj studiji, osetljivost 4D-CT-a je 89% u vizualizaciji paratireoidnih žlezda [14]. Kod pacijenata sa višestrukim disekcijama vrata i trajno povišenim vrednostima PTH-a, kod kojih navedene metode snimanja nisu dovele do vizualizacije ektopično lokalizovanih medijastinalnih paratireoidnih žlezda, može se primeniti selektivna venska kateterizacija u cilju merenja nivoa PTH-a [15]. PET/CT sa ¹¹C-metioninom se takođe može koristiti kao još jedan dodatni metod vizualizacije [16,17]. Mi smo koristili CT, Tc-99m sestamibi

gery was 80 minutes (between 34 and 150 minutes). All patients were extubated in the operating room. No patient required a stay in the surgical intensive care unit. The thoracic drain was usually removed after one postoperative day (range: 0 days – 2 days). The average 24-hour drainage was 65 ml (range: 0 ml – 110 ml). The mean length of hospitalization was 7 days (between three and 15 days). One patient had a wound infection. Six patients developed postoperative hypocalcemia that required substitution therapy to prevent hungry bone syndrome. Wound infection and postoperative hypocalcemia were the main causes of prolonged hospitalization. There was no need for an open approach in the resection of the MEPTGs. Histological analysis indicated parathyroid adenoma in three patients, hyperplasia of the parathyroid gland in 7 patients, and chronic granulomatous inflammation of the lymph glands was found in one patient with sarcoidosis. The mean diameter of the excised glands was 20 mm, and they were all larger than 2 mm in diameter (range: 2 mm – 35 mm). After surgery, serum calcium levels returned to normal on the first postoperative day. After six-month follow-up, all patients, except one, had normal serum calcium values. The PTH level returned to normal levels in 10 patients. In one patient, the PTH level remained elevated, and the definitive pathohistological finding did not confirm parathyroid tissue, nor was the cause of the elevated calcium and parathyroid hormone levels determined by further investigations.

DISCUSSION

The success of surgical treatment depends on the precise localization of the ectopic parathyroid gland in the mediastinum and the choice of the most appropriate approach. Imaging methods used for preoperative visualization of MEPTGs are the following: US, CT, the Tc-99m sestamibi scan, MRI, SPECT and Dual phase Tc-99m sestamibi scan with SPECT. The diagnostic sensitivity of these procedures is presented in Table 1 [13].

In patients with negative scintigraphy, a 4D-CT scan can be used to visualize MEPTGs. According to one study, the sensitivity of 4D-CT is 89% in PTG visualization [14]. In patients with multiple neck dissections and permanently elevated PTH values, in whom imaging methods did not visualize MEPTGs, selective venous catheterization can be applied in order to measure PTH levels [15]. PET/CT with ¹¹C-methionine can also be used as another supplementary visualization method [16,17]. We used the CT, the Tc-99m sestamibi scan, and SPECT for preoperative visualization of PTGs, although 18F-fluorocholine PET/CT imaging has higher sensitivity [37]. Some medical centers, in order to visualize intraoperative ectopic PTGs, use intravenous

Tabela 1. Osetljivost dijagnostičkih procedura

Dijagnostički modalitet / Diagnostic modality	Osetljivost / Sensitivity
Ultrazvuk / Ultrasound	27% – 89%
Tc-99m sestamibi scintigrafija / Tc-99m sestamibi scan	54 – 100%
CT	65%
Magnetna rezonanca / MRI	75% – 78%
SPECT	95%
Dvofazna Tc-99m sestamibi scintigrafija sa SPECT-om / Dual phase Tc-99m sestamibi scan with SPECT	96%

Table 1. Factors associated with risk of perinatal HIV transmission [25].

skeniranje i SPECT za preoperativnu vizualizaciju paratireoidnih žlezda, iako PET/CT sa ¹⁸F-fluoroholinom ima veću osetljivost [37]. Neki medicinski centri, u cilju vizualizacije intraoperativnih ektopičnih PTŽ-a, intravenski primenjuju metilen plavo [18,19]. Paratireoidno tkivo ima sposobnost da veže metilensko plavo i samim tim je tkivo lakše identifikovati. Karakteristika paratireoidne žlezde jeste sposobnost fluorescencije kada je izložena infracrvenom spektru svetlosti, a za vizualizaciju su korišćene određene talasne dužine. Postoji nekoliko metoda koje se koriste za intraoperativnu vizualizaciju fluorescencije (NIRAF (engl. *near-infrared autofluorescence*); fluorescentno kontrastno snimanje (engl. *contrast-enhanced fluorescence imaging*)) [38].

Jedan od načina da se biohemijskim putem poveća efikasnost hirurškog lečenja jeste intraoperativno praćenje PTH-a. Smatra se da je EMPTŽ uspešno ekstirpirana ako je nivo PTH-a izmeren 8 – 20 minuta nakon uklanjanja tkiva opao za više od 50%, u poređenju sa nivoom pre ekscizije [20,21]. Ukoliko nivo PTH-a ne padne na željene vrednosti, hiruršku eksploraciju treba nastaviti [22]. Ne postoji konsenzus po pitanju procentualne vrednosti i brzine smanjenja nivoa PTH-a koje bi nesumnjivo mogle da potvrde da je EMPTŽ uklonjena. Međutim, postoji niz definisanih kriterijuma [23–27]. U našem slučaju, kao intraoperativnu potvrdu paratireoidnog tkiva, koristili smo analizu smrznutog preseka ekstirpiranog tkiva. Samo u jednom slučaju, analiza smrznutog preseka nije potvrdila da je u pitanju paratireoidna žlezda, već je potvrđena hronična granulomatozna infekcija limfnih žlezda. Nekada je najčešće primenjivani pristup za ekstirpaciju PTŽ-a bila cervikalna bilateralna eksploracija vrata bez prethodne vizualizacije PTŽ-a [1]. U današnje vreme, preoperativna vizualizacija PTŽ-a je neizostavni deo planiranja lečenja. Kod EMPTŽ-a, najčešće korišćeni pristupi bili su sternotomija i torakotomija [10,12,29]. Danas se sve više koriste minimalno invazivne tehnike. U sadašnje vreme je preovlađujuće mišljenje da je, u slučaju medijastinalne lokalizacije PTŽ-a, metoda prvog izbora VATS.

application of methylene blue [18,19]. Parathyroid tissue has the ability to bind methylene blue and thus the tissue is easier to identify. A characteristic of the parathyroid gland is the ability to fluoresce when exposed to the infrared light spectrum, and specific wavelengths were used to visualize this. There are several methods used for intraoperative fluorescence visualization (near-infrared autofluorescence – NIRAF; contrast-enhanced fluorescence imaging) [38].

One of the biochemical ways to increase the efficiency of surgical treatment is intraoperative monitoring of PTH. It is considered that an MEPTG has been successfully extirpated if the PTH level measured 8 – 20 minutes after the removal of the tissue has fallen by more than 50%, as compared to the level before excision [20,21]. If the PTH level does not drop to the desired values, surgical exploration should be continued [22]. There is no consensus on the percentage and speed of PTH decrease which could undoubtedly assert that an MEPTG has been removed. However, there is a number of defined criteria [23–27]. In our case, as intraoperative confirmation of parathyroid tissue, we used frozen section analysis of extirpated tissue. In only one case, the frozen section analysis did not confirm a PTG, rather a chronic granulomatous infection of the lymphatic glands. Previously, the most commonly used approach for extirpation of PTGs was cervical bilateral exploration of the neck without prior visualization of the PTGs [1]. Today, preoperative visualization of PTGs is an indispensable part of treatment planning. In the case of MEPTGs, the most common approaches used were sternotomy and thoracotomy [10,12,29]. Nowadays, minimally invasive techniques are increasingly used. Current opinion is that, in the case of mediastinal localization of PTGs, the method of choice is VATS.

In a large study by Wang et al. [33], of 30 parathyroid mediastinal glands, 24 were intrathymic while 6 were parathymic. Edis et al. [32] and Clark [33] presented a study involving 92 mediastinal parathyroid glands and found that 85% were adjacent to the thymus. Our

U velikoj studiji koju su sproveli Vang i saradnici [33], od 30 paratireoidnih medijastinalnih žlezda, 24 su bile intratimične, a 6 paratimične. Edis i saradnici [32] i Klark [33] su predstavili studiju koja je uključivala 92 medijastinalne paratireoidne žlezde i otkrili da je 85% bilo lokalizovano uz timus. Naši rezultati podržavaju ovu studiju – 8 žlezda je bilo intratimično, dve žlezde su bile peritimične, a jedna žlezda se nalazila u aortopulmonalnom prozoru.

Angiografska ablacija predstavlja opciju u lečenju EMPTŽ-a. Ova tehnika sprečava dotok krvi u žlezdu. Nedostatak ove tehnike ogleda se u činjenici da je u 40% slučajeva bilo nemoguće lokalizovati žlezdu, kao i u stopi rane pogreške (engl. *early failure rate*) od 40%. Uz primenu ove tehnike retko se javljaju neurološke komplikacije. Međutim, ova tehnika ne obezbeđuje paratireoidno tkivo, ukoliko postoji potreba za autotransplantacijom [36–38].

U našoj seriji, operacije su, u proseku, trajale 80 minuta. Svi pacijenti sa primarnim hiperparatireoidizmom su otpušteni iz bolnice četiri dana nakon operacije, a pacijenti sa sekundarnim hiperparatireoidizmom su otpušteni unutar 7 dana od operacije. Razlog dužeg boravka u bolnici pacijenata sa sekundarnim HPT-om bila je postoperativna hipokalcemija, koja je zahtevala supstitucionu terapiju. Pojavila se jedna postoperativna komplikacija u vidu infekcije rane. Ovakav rezultat se razlikuje od rezultata Rasela i saradnika [4] za sternotomiju, koji su pokazali incidenciju od 21% plućnih komplikacija, te 8% komplikacija rane, atrijalne fibrilacije i duboke venske tromboze. Kon i saradnici [12] su prijavili stopu komplikacija od 19% (četiri od 21 pacijenta) nakon sternotomije, za resekciju ektopične paratireoidne žlezde. S obzirom na njihove male dimenzije i medijastinalnu lokalizaciju, VATS se čini idealnim pristupom u lečenju retkih medijastinalnih ektopičnih paratireoidnih žlezda. Prednosti VATS pristupa, u poređenju sa otvorenom hirurģijom (sternotomija ili torakotomija), su dobro poznate i opisane.

VATS je najmanje invazivna tehnika koja prouzrokuje najmanje bola pacijentu, pruža najbolju vizualizaciju tumora, obezbeđuje kraće trajanje operacije, manju učestalost komplikacija, kraće vreme bolničkog lečenja i dobar kozmetički/estetski efekat.

ZAKLJUČAK

Predstavljamo svoje iskustvo sa prvih jedanaest slučajeva ektopično lokalizovanih paratireoidnih žlezda reseciranih VATS tehnikom. Prednosti VATS pristupa, u poređenju sa otvorenom hirurģijom (sternotomija ili torakotomija), su dobro poznate i opisane i mogu se primeniti u hirurģskom lečenju EMPTŽ-a. Preporučuje se da se preoperativno lokalizacija PTŽ-a odredi što precizno.

results support this study – 8 glands were intrathymic, two glands were perithymic, and one gland was located in the aortopulmonary window.

Angiographic ablation is an option in the treatment of an MEPTG. This technique prevents blood flow to the gland. The disadvantage of this technique is reflected in the fact that, in 40% of cases, it was impossible to localize the gland, as well as in the early failure rate of 40%. With this technique, neurological complications rarely occur. However, it does not provide us with parathyroid tissue, if there is a need for autotransplantation [36–38].

The duration of surgery in our series averaged 80 minutes. All patients with primary hyperparathyroidism were discharged four days after surgery and patients with secondary hyperparathyroidism were discharged within 7 days of surgery. The reason for the longer hospital stays of patients with secondary HPT was postoperative hypocalcemia, which required substitution therapy. We had one postoperative complication in the form of a wound infection. This is different from the results of Russell et al. [4] for sternotomy, which showed an incidence of 21% of pulmonary complications, 8% of wound complications, atrial fibrillation, and deep vein thrombosis. Kohn et al. [12] reported a complication rate of 19% (four out of 21 patients) after sternotomy for resection of an ectopic parathyroid gland. Considering their small dimensions and mediastinal localization, VATS seems to be an ideal approach in the management of rare mediastinal ectopic parathyroid glands. The advantages of the VATS approach, as compared to open surgery (sternotomy or thoracotomy), are well known and described.

VATS is the least invasive and least painful technique, it provides the best visualization of the tumor, a shorter duration of surgery, a lower frequency of complications, shorter time of hospital treatment, and a good cosmetic/aesthetic effect.

CONCLUSION

We present our experience regarding the first eleven cases of ectopically localized parathyroid glands resected using the VATS technique. The advantages of the VATS approach, as compared to open surgery (sternotomy or thoracotomy), are well known and described, and can be applied in the surgical treatment of MEPTGs. It is recommended that the localization of the PTGs is obtained as precisely as possible preoperatively, and that the diagnosis of hyperparathyroidism is unequivocal. The VATS approach should be considered as the first and least invasive approach in the resection of ectopically localized parathyroid glands.

Conflict of interest: None declared.

znije, te da dijagnoza hiperparatireoidizma bude definitivno ustanovljena. VATS pristup treba smatrati prvim i najmanje invazivnim pristupom u resekciji ektoپیčno lokalizovanih paratireoidnih žlezda.

Sukob interesa: Nije prijavljen.

LITERATURA / REFERENCES

- Prescott JD, Udelsman R. Remedial operation for primary hyperparathyroidism. *World J Surg.* 2009 Nov;33(11):2324-34. doi: 10.1007/s00268-009-9962-0.
- Gomes EM, Nunes RC, Lacativa PG, Almeida MH, Franco FM, Leal CT, et al. Ectopic and extranumerary parathyroid glands location in patients with hyperparathyroidism secondary to end stage renal disease. *Acta Cir Bras.* 2007 Mar-Apr;22(2):105-9. doi: 10.1590/s0102-86502007000200005.
- Phitayakorn R, McHenry CR. Incidence and location of ectopic abnormal parathyroid glands. *Am J Surg.* 2006 Mar;191(3):418-23. doi: 10.1016/j.amjsurg.2005.10.049.
- Russell CF, Edis AJ, Scholz DA, Sheedy PF, van Heerden JA. Mediastinal parathyroid tumors: experience with 38 tumors requiring mediastinotomy for removal. *Ann Surg.* 1981 Jun;193(6):805-9. doi: 10.1097/0000658-198106000-00016.
- Alesina PF, Moka D, Mahlstedt J, Walz MK. Thoracoscopic removal of mediastinal hyperfunctioning parathyroid glands: personal experience and review of the literature. *World J Surg.* 2008 Feb;32(2):224-31. doi: 10.1007/s00268-007-9303-0.
- Cupisti K, Dotzenrath C, Simon D, Röher HD, Goretzki PE. Therapy of suspected intrathoracic parathyroid adenomas. Experiences using open transthoracic approach and video-assisted thoracoscopic surgery. *Langenbecks Arch Surg.* 2002 Jan;386(7):488-93. doi: 10.1007/s00423-001-0254-x.
- Randone B, Costi R, Scatton O, Fulla Y, Bertagna X, Soubrane O, et al. Thoracoscopic removal of mediastinal parathyroid glands: a critical appraisal of an emerging technique. *Ann Surg.* 2010 Apr;251(4):717-21. doi: 10.1097/SLA.0b013e3181c1c1fb0.
- Cope O. Surgery of hyperparathyroidism: the occurrence of parathyroids in the anterior mediastinum and the division of the operation into two stages. *Ann Surg* 1941;114(4):706-733.
- Iihara M, Suzuki R, Kawamata A, Horiuchi K, Okamoto T. Thoracoscopic removal of mediastinal parathyroid lesions: selection of surgical approach and pitfalls of preoperative and intraoperative localization. *World J Surg* 2012;36(6):1327-1334.
- Said SM, Cassivi SD, Allen MS, Deschamps C, Nichols FC 3rd, Shen KR, et al. Minimally invasive resection for mediastinal ectopic parathyroid glands. *Ann Thorac Surg.* 2013 Oct;96(4):1229-1233. doi: 10.1016/j.athoracsur.2013.05.084.
- Arnault V, Beaulieu A, Lifante JC, Sitges Serra A, Sebag F, Mathonnet M, et al. Multicenter study of 19 aortopulmonary window parathyroid tumors: the challenge of embryologic origin. *World J Surg.* 2010 Sep;34(9):2211-6. doi: 10.1007/s00268-010-0622-1.
- Conn JM, Goncalves MA, Mansour KA, McGarity WC. The mediastinal parathyroid. *Am Surg.* 1991 Jan;57(1):62-6.
- Noussios G, Anagnostis P, Natsis K. Ectopic parathyroid glands and their anatomical, clinical and surgical implications. *Exp Clin Endocrinol Diabetes.* 2012 Nov;120(10):604-10. doi: 10.1055/s-0032-1327628.
- Day KM, Elsayed M, Beland MD, Monchik JM. The utility of 4-dimensional computed tomography for preoperative localization of primary hyperparathyroidism in patients not localized by sestamibi or ultrasonography. *Surgery.* 2015 Mar;157(3):534-9. doi: 10.1016/j.surg.2014.11.010.
- Lebastchi AH, Aruny JE, Donovan PI, Quinn CE, Callender GG, Carling T, et al. Real-Time Super Selective Venous Sampling in Remedial Parathyroid Surgery. *J Am Coll Surg.* 2015 Jun;220(6):994-1000. doi: 10.1016/j.jamcollsurg.2015.01.004.
- Traub-Weidinger T, Mayerhoefer ME, Koperek O, Mitterhauser M, Duan H, Karanikas G, et al. 11C-methionine PET/CT imaging of 99mTc-MIBI-SPECT/CT-negative patients with primary hyperparathyroidism and previous neck surgery. *J Clin Endocrinol Metab.* 2014 Nov;99(11):4199-205. doi: 10.1210/jc.2014-1267.
- Hellman P, Ahlström H, Bergström M, Sundin A, Långström B, Westerberg G, et al. Positron emission tomography with 11C-methionine in hyperparathyroidism. *Surgery.* 1994 Dec;116(6):974-81.
- Amer K, Khan AZ, Rew D, Lagattola N, Singh N. Video assisted thoracoscopic excision of mediastinal ectopic parathyroid adenomas: a UK regional experience. *Ann Cardiothorac Surg.* 2015 Nov;4(6):527-34. doi: 10.3978/j.issn.2225-319X.2015.09.04.
- Dudley NE. Methylene blue for rapid identification of the parathyroids. *Br Med J.* 1971 Sep 18;3(5776):680-1. doi: 10.1136/bmj.3.5776.680.
- Phitayakorn R, McHenry CR. Parathyroidectomy: overview of the anatomic basis and surgical strategies for parathyroid operations. *Clin Rev Bone Miner Metab* 2007;5:89-102.
- Sagan D, Goździuk K. Surgical treatment of mediastinal parathyroid adenoma: rationale for intraoperative parathyroid hormone monitoring. *Ann Thorac Surg.* 2010 Jun;89(6):1750-5. doi: 10.1016/j.athoracsur.2010.02.076.
- Neves MC, Ohe MN, Rosano M, Abrahão M, Cervantes O, Lazaretti-Castro M, et al. A 10-year experience in intraoperative parathyroid hormone measurements for primary hyperparathyroidism: a prospective study of 91 previous unexplored patients. *J Osteoporos.* 2012;2012:914214. doi: 10.1155/2012/914214.
- Udelsman R, Åkerström G, Biagini C, Duh QY, Miccoli P, Niederle B, et al. The surgical management of asymptomatic primary hyperparathyroidism: proceedings of the Fourth International Workshop. *J Clin Endocrinol Metab.* 2014 Oct;99(10):3595-606. doi: 10.1210/jc.2014-2000.
- Di Stasio E, Carozza C, Pio Lombardi C, Raffaelli M, Traini E, Bellantone R, et al. Parathyroidectomy monitored by intra-operative PTH: the relevance of the 20 min end-point. *Clin Biochem.* 2007 Jun;40(9-10):595-603. doi: 10.1016/j.clinbiochem.2006.12.007.
- Richards ML, Thompson GB, Farley DR, Grant CS. An optimal algorithm for intraoperative parathyroid hormone monitoring. *Arch Surg.* 2011 Mar;146(3):280-5. doi: 10.1001/archsurg.2011.5.
- Barczynski M, Konturek A, Hubalewska-Dydejczyk A, Cichon S, Nowak W. Evaluation of Halle, Miami, Rome, and Vienna intraoperative iPTH assay criteria in guiding minimally invasive parathyroidectomy. *Langenbecks Arch Surg.* 2009 Sep;394(5):843-9. doi: 10.1007/s00423-009-0510-z.
- Carneiro DM, Irvin GL 3rd, Inabnet WB. Limited versus radical parathyroidectomy in familial isolated primary hyperparathyroidism. *Surgery.* 2002 Dec;132(6):1050-4; discussion 1055. doi: 10.1067/msy.2002.128695.
- Downey NJ, McGuigan JA, Dolan SJ, Russell CF. Median sternotomy for parathyroid adenoma. *Ir J Med Sci.* 1999 Jan-Mar;168(1):13-6. doi: 10.1007/BF02939573.
- Obara T, Fujimoto Y, Tanaka R, Ito Y, Kodama T, Yashiro T, et al. Mid-mediastinal parathyroid lesions: preoperative localization and surgical approach in two cases. *Jpn J Surg.* 1990 Jul;20(4):481-6. doi: 10.1007/BF02470837.

30. Sukumar MS, Komanapalli CB, Cohen JI. Minimally invasive management of the mediastinal parathyroid adenoma. *Laryngoscope*. 2006 Mar;116(3):482-7. doi: 10.1097/01.mlg.0000200582.65418.37.
31. Wang C, Gaz RD, Moncure AC. Mediastinal parathyroid exploration: a clinical and pathologic study of 47 cases. *World J Surg*. 1986 Aug;10(4):687-95. doi: 10.1007/BF01655558.
32. Edis AJ, Sheedy PF, Beahrs OH, van Heerden JA. Results of reoperation for hyperparathyroidism, with evaluation of preoperative localization studies. *Surgery*. 1978 Sep;84(3):384-93.
33. Clark OH. Mediastinal parathyroid tumors. *Arch Surg*. 1988 Sep;123(9):1096-100. doi: 10.1001/archsurg.1988.01400330072011.
34. Heller HJ, Miller GL, Erdman WA, Snyder WH 3rd, Breslau NA. Angiographic ablation of mediastinal parathyroid adenomas: local experience and review of the literature. *Am J Med*. 1994 Dec;97(6):529-34. doi: 10.1016/0002-9343(94)90348-4.
35. Doppman JL, Brown EM, Brennan MF, Spiegel A, Marx SJ, Aurbach GD. Angiographic ablation of parathyroid adenomas. *Radiology*. 1979 Mar;130(3):577-82. doi: 10.1148/130.3.577.
36. Doherty GM, Doppman JL, Miller DL, Gee MS, Marx SJ, Spiegel AM, et al. Results of a multidisciplinary strategy for management of mediastinal parathyroid adenoma as a cause of persistent primary hyperparathyroidism. *Ann Surg*. 1992 Feb;215(2):101-6. doi: 10.1097/00000658-199202000-00002.
37. Huber GF, Hüllner M, Schmid C, Brunner A, Sah B, Vetter D, et al. Benefit of 18F-fluorocholine PET imaging in parathyroid surgery. *Eur Radiol*. 2018 Jun;28(6):2700-2707. doi: 10.1007/s00330-017-5190-4.
38. Wong A, Wong JCY, Pandey PU, Wiseman SM. Novel techniques for intraoperative parathyroid gland identification: a comprehensive review. *Expert Rev Endocrinol Metab*. 2020 Nov;15(6):439-457. doi: 10.1080/17446651.2020.1831913.