

# ŠTA SMO NAUČILI IZ NEADEKVATNOG TESTIRANJA D-DIMERA – PRIKAZ SLUČAJA

PRIKAZ SLUČAJA

CASE REPORT

## LESSONS LEARNT FROM INAPPROPRIATE D-DIMER TESTING – CASE REPORT

Nikola Pantić<sup>1</sup>, Nikica Sabljic<sup>1</sup>, Andrija Bogdanović<sup>1,2</sup>, Ljubomir Jaković<sup>1</sup>, Mirjana Mitrović<sup>1,2</sup>

<sup>1</sup> Univerzitetski klinički centar Srbije, Klinika za hematologiju, Beograd, Srbija

<sup>1</sup> University Clinical Center of Serbia, Clinic of Hematology, Belgrade, Serbia

<sup>2</sup> Univerzitet u Beogradu, Medicinski fakultet, Beograd, Srbija

<sup>2</sup> University of Belgrade, Faculty of Medicine, Belgrade, Serbia

### SAŽETAK

**Uvod:** Od proglašenja KOVID-19 pandemije, testiranje D-dimera često se koristi u nestandardnim i često neopravdanim indikacijama. Ovo je dovelo do pogrešnih dijagnoza, prekomernog sprovođenja dijagnostičkih procedura i nepotrebnih troškova.

**Prikaz slučaja:** Bolesnica, stara 50 godina, javila se u službu urgentne medicine sa tegobama u vidu bola u grudima, kratkog daha, zamaranja i bola u levoj nozi. U učinjenim analizama uočen je povišen D-dimer (4,73 mg/l (N:<0,5)) zbog čega su isključeni tromboza dubokih vena, plućna tromboembolija, kao i KOVID-19. Nakon toga u terapiju je uveden rivaroksaban u dozi od 10 mg/dan. Nakon sedam dana, D-dimer je i dalje rastao (17,52 mg/l), pa je umesto rivaroksabana uveden nisko-molekularni heparin. Nakon još pet dana, D-dimer je i dalje rastao (27,26 mg/l), a u nalazu kompletne krvne slike (KKS) je uočena trombocitopenija ( $54 \times 10^9/l$ ). Kako je 4T skor za heparinom indukovanu trombocitopeniju bio 5, urađena su anti-heparin/PF4 antitela koja su bila pozitivna (4+). U terapiju je uveden fondaparinux-natrijum, a pacijentkinja je upućena hematologu. Na hematološkoj kontroli je uočeno krvarenje po koži i sluznici gingive. U laboratorijskim analizama uočeni su pancitopenija (hemoglobin = 101 g/l; leukociti (*Le*) =  $1,7 \times 10^9/l$ ; trombociti =  $29 \times 10^9/l$ ) i potrošna koagulopatija (INR = 1,7; aPTT = 27,1 s; fibrinogen = 0,8 g/l; D-dimer = 30,9 mg/l). Učinjena je aspiracija koštane srži nakon čega je postavljena dijagnoza akutne monoblastne leukemije, 47, XX, + 12 [4] / 46, XX [16], FLT3-ITD, NPM1 – divlji tip.

**Zaključak:** D-dimer je moćan dijagnostički test ukoliko se koristi prema indikacijama. Nikada se ne sme sagledavati kao izolovan rezultat, a uvođenje terapije samo na osnovu povišenih vrednosti D-dimera se ne savetuje.

**Ključne reči:** akutna monoblastna leukemija, D-dimer, heparinom indukovana trombocitopenija

### ABSTRACT

**Introduction:** Since the beginning of the COVID-19 pandemic, D-dimer testing has been widely used in not-yet-approved indications. This has led to misdiagnosis, overuse of diagnostic procedures, and unnecessary costs.

**Case report:** Herein, we report the case of a 50-year-old female patient who came to the emergency department with chest pain, shortness of breath, fatigue, and pain in her right leg. Because of an elevated level of D-dimer (4.73 mg/l (N:<0.5)), deep vein thrombosis and pulmonary embolism, as well as COVID-19 were excluded. Therapy with rivaroxaban, 10 mg/day, was initiated. Seven days later, the D-dimer level continued to rise (17.52 mg/l), which was why rivaroxaban was replaced with low molecular weight heparin (LMWH). After another five days, the level of D-dimer continued to rise (27.26 mg/l). A complete blood count revealed significant thrombocytopenia ( $54 \times 10^9/l$ ). As the 4Ts score for heparin-induced thrombocytopenia was 5, the anti-heparin/PF4 antibody test was performed, and it came back strongly positive (4+). LMWH was replaced with fondaparinux sodium, and the patient was referred to a hematologist. On examination, cutaneous bleeding and gingivorrhagia were present. Laboratory analyses registered pancytopenia (hemoglobin = 101 g/l; white blood cell count =  $1.7 \times 10^9/l$ ; platelet count =  $29 \times 10^9/l$ ) and consumption coagulopathy (INR = 1.7; aPTT = 27.1 s; fibrinogen = 0.8 g/l; D-dimer = 30.9 mg/l). Bone marrow aspirate was analyzed and the diagnosis of acute monoblastic leukemia, 47, XX, +12 [4] / 46, XX [16], wild type FLT3-ITD and NPM1, was established.

**Conclusion:** D-dimer is a powerful diagnostic tool when used properly. It should never be treated as a single, isolated result and the decision to introduce anticoagulant therapy should never be made based on its value alone.

**Keywords:** acute monoblastic leukemia, D-dimer, heparin-induced thrombocytopenia

Autor za korespondenciju:

Mirjana Mitrović

Klinika za hematologiju, Univerzitetski klinički centar Srbije

Adresa: Dr Koste Todorovića 2, 11000 Beograd, Srbija

Elektronska adresa: mirjanamitrovic777@gmail.com

Corresponding author:

Mirjana Mitrović

Clinic of Hematology, University Clinical Center of Serbia

Address: 2 Dr Koste Todorovića Street, 11000 Belgrade, Serbia

E-mail: mirjanamitrovic777@gmail.com

Primljeno • Received: May 23, 2024;

Revidirano • Revised: June 10, 2024;

Prihvaćeno • Accepted: June 11, 2024;

Online first: June 25, 2024

DOI: 10.5937/smlk5-51180

## UVOD

Molekuli D-dimera nastaju kao rezultat razgradnje fibrinskih polimera. U svakodnevnoj praksi, D-dimer služi kao marker aktivacije koagulacionih i fibrinolitičkih sistema [1,2]. Indikacije za testiranje D-dimera, kao što je isključivanje venske tromboembolije, procena rizika od ponovne tromboze, i dijagnoza i lečenje diseminovane intravaskularne koagulacije (engl. *disseminated intravascular coagulation – DIC*), su jasno definisane [3]. Međutim, od početka pandemije KOVID-19, testiranje D-dimera se široko koristi u neopravdanim indikacijama. Ovo može da dovede do prekomerne upotrebe različitih dijagnostičkih metoda snimanja i nepotrebnih troškova [4].

Prikazujemo slučaj pacijentkinje kod koje je neadekvatno testiranje D-dimera dovelo i do neadekvatne terapije antikoagulansima, komplikovane heparinom izazvanom trombocitopenijom, krvarenjem i odloženom dijagnozom akutne leukemije.

## PRIKAZ SLUČAJA

Pacijentkinja, stara 50 godina, došla je u Urgentni centar (UC) žaleći se na bol u grudima, koji je bio prisutan prethodna dva dana i javljao se na 15 minuta. Takođe se žalila se na kratak dah, zamaranje i bol u desnoj nozi, što je bilo prisutno prethodna tri dana. U ličnoj anamnezi, prijavila je arterijsku hipertenziju, displaziju dojke i KOVID-19, preležan osam meseci pre ovog pregleda. Pacijentkinja je bila nepušač i nije prijavila trombotične događaje u svojoj porodičnoj anamnezi.

Lekar koji ju je pregledao je naložio da se urade laboratorijske analize, iako je sam pregled pacijentkinje dao uredan nalaz i elektrokardiogram je bio normalan. Kompletna krvna slika je pokazala leukopeniju ( $3,2 \times 10^9/l$ ) sa normalnom leukocitarnom formulom, kao i normalne vrednosti hemoglobina i trombocita. U to vreme nije rađen razmaz periferne krvi. Utvrđen je povišen nivo laktat dehidrogenaze (LDH) ( $534 U/l$  ( $N:<460$ )) kao i D-dimera ( $4,73 mg/l$  ( $N:<0,5$ )). Srčani markeri (troponin T i kreatin kinaza MB) su bili normalni. KOVID-19 je isključen antigenim testom, a kasnije i testiranjem polimerazne lančane reakcije (engl. *polymerase chain reaction testing – PCR*). Velovi kriterijumi za duboku vensku trombozu (DVT) [5] i plućnu emboliju (PE) [6] tada nisu izračunati, ali je retrospektivno izračunavanje pokazalo vrednost od 1 (grupa umerenog rizika) za DVT i vrednost od 3 (grupa umerenog rizika) za PE. Urađena je kompjuterizovana tomografska angiografija (engl. *computed tomography angiography – CTA*) plućne arterije i nisu otkriveni znaci tromboembolije. Uvedena je terapija rivaroksabanom u dozi od 10 mg/dan i pacijentkinja je otpuštena.

Dva dana kasnije, urađena je dupleks ultrasonografija donjih ekstremiteta sa normalnim nalazom. Se-

## INTRODUCTION

D-dimer molecules are formed as the result of the degradation of fibrin polymers. In everyday practice, D-dimer serves as a marker of the activation of coagulation and fibrinolytic systems [1,2]. Indications for D-dimer testing, such as exclusion of venous thromboembolism, assessment of risk of recurrent thrombosis, and the diagnosis and management of disseminated intravascular coagulation (DIC), are clearly defined [3]. However, since the beginning of the COVID-19 pandemic, D-dimer testing has been widely used in not-yet-approved indications. This may lead to the overuse of imaging diagnostics and unnecessary costs [4].

We present the case of a patient wherein inappropriate D-dimer testing led to inadequate anticoagulant therapy complicated with heparin-induced thrombocytopenia, bleeding, and delayed diagnosis of acute leukemia.

## CASE REPORT

A 50-year-old female patient came to the emergency department (ED) with chest pain, lasting two days prior and occurring at 15-minute intervals. Moreover, she complained of shortness of breath, fatigue, and pain in the right leg, which had been present for three days. In her personal history, she reported arterial hypertension, mammary dysplasia, and COVID-19, eight months prior to the exam. She was a non-smoker and reported no thrombotic events in her family history.

The attending physician ordered laboratory tests, although her physical exam and electrocardiogram were normal. A complete blood count revealed leukopenia ( $3.2 \times 10^9/l$ ) with a normal differential and a normal hemoglobin level and platelet count. At the time, a blood smear was not performed. The level of lactate dehydrogenase (LDH) was elevated ( $534 U/l$  ( $N:<460$ )) as well as D-dimer ( $4.73 mg/l$  ( $N:<0.5$ )). Cardiac enzymes (troponin T and creatine kinase MB) were normal. COVID-19 was excluded with antigen, and later, with polymerase chain reaction (PCR) testing. Wells criteria for deep venous thrombosis (DVT) [5] and pulmonary embolism (PE) [6] were not calculated at that point, but retrospective calculation showed values of 1 (moderate risk group) for DVT and 3 (moderate risk group) for PE. Computed tomography angiography (CTA) of the pulmonary artery was performed and revealed no signs of thromboembolism. Therapy with rivaroxaban, 10 mg/day, was introduced and the patient was discharged.

Two days later, duplex ultrasonography of the lower extremities was performed with a normal finding. Seven days later, D-dimer levels continued to rise ( $17.52 mg/l$ ). Rivaroxaban was replaced with a prophy-

dam dana kasnije, nivoi D-dimera su nastavili da rastu (17,52 mg/l). Rivaroksaban je zamenjen profilaktičkom dozom heparina niske molekularne težine (engl. *low molecular weight heparin – LMWH*). Pacijentkinja je upućena na mamografiju i kod ginekologa. Mamografija nije pokazala znakove maligniteta. CT nalaz abdomena je bio normalan.

Posle još pet dana, D-dimer i LDH su nastavili da rastu (27,26 mg/l i 1.730 U/l). KKKS je pokazala značajnu trombocitopeniju ( $54 \times 10^9/l$ ), uz leukopeniju ( $Le = 2,4 \times 10^9/l$ ; neutrofili =  $1,3 \times 10^9/l$ ; limfociti =  $0,8 \times 10^9/l$ ; monociti =  $0,2 \times 10^9/l$ ), dok je nivo hemoglobina bio normalan (124 g/l). Pošto je 4Ts skor za heparinom indukovanu trombocitopeniju (HIT) bio 5 [7], urađen je test antitela na heparin-PF4, koji je bio snažno pozitivan (4+). LMWH je zamenjen fondaparinux-natrijumom, a pacijent je upućen hematologu.

Prilikom pregleda u našem centru, konstatovano je kožno krvarenje na mestima punkcije vene i mestima davanja LMWH-a, uz difuzne petehije ekstremiteta i gingivoragiju. Laboratorijskim analizama je registrovana pancitopenija (hemoglobin = 101 g/l; MCV = 84,8 fl,  $Le = 1,7 \times 10^9/l$ ; trombociti =  $29 \times 10^9/l$ ), potrošna koagulopatija (INR = 1,7; aPTT = 27,1 s; fibrinogen = 0,8 g/l; D-dimer = 30,9 mg/l; ISTH DIC skor = 7) [8]. U razmazu periferne krvi su otkriveni sledeći elementi: neutrofili 38%, limfociti 46%, monociti 4%, bazofili 1%, metamielociti 1%, mijelociti 3% i limfoidni elementi 7%. Istog dana je analiziran aspirat koštane srži i postavljena dijagnoza akutne monoblastne leukemije (AML), 47, XX, +12 [4] / 46, XX [16], FLT3-ITD i NPM1 – divlji tip (Slika 1).

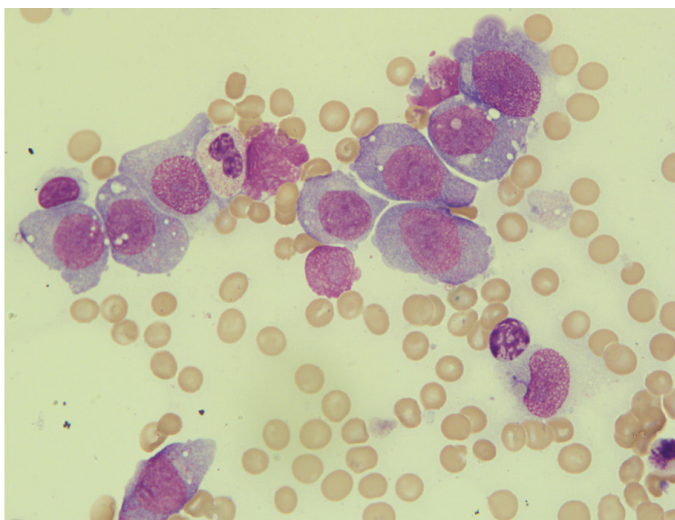
Indukciona hemioterapija, koja se sastojala od idarubicina i citarabina, započeta je zajedno sa suportivnom terapijom za DIC [9]. Posle četvrtog dana lečenja nisu bili prisutni znaci potrošne koagulopatije (Grafikon 1).

lactic dose of low molecular weight heparin (LMWH). The patient was referred for a mammography and to a gynecologist. The mammography showed no signs of malignancy. The abdominal CT finding was normal.

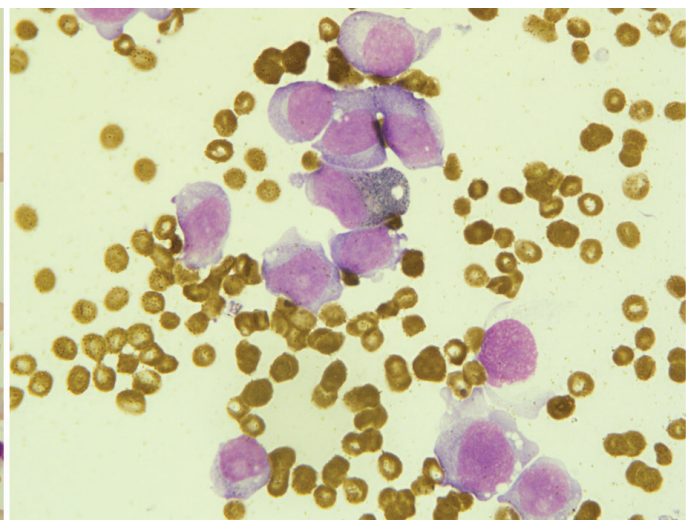
After another five days, D-dimer and LDH continued to rise (27.26 mg/l and 1,730 U/l, respectively). CBC revealed significant thrombocytopenia ( $54 \times 10^9/l$ ), along with leukopenia (WBC =  $2.4 \times 10^9/l$ ; neutrophils =  $1.3 \times 10^9/l$ ; lymphocytes =  $0.8 \times 10^9/l$ ; monocytes =  $0.2 \times 10^9/l$ ), while the hemoglobin level was normal (124 g/l). As the 4Ts score for heparin-induced thrombocytopenia (HIT) was 5 [7], the anti-heparin-PF4 antibody test was performed, and it came back strongly positive (4+). LMWH was replaced with fondaparinux sodium, and the patient was referred to a hematologist.

On examination at our center, cutaneous bleeding was noted at the venepuncture and LMWH application sites, along with diffuse limb petechiae and gingivorragia. Laboratory analyses registered pancytopenia (hemoglobin = 101 g/l; MCV = 84.8 fl, WBC =  $1.7 \times 10^9/l$ ; PC =  $29 \times 10^9/l$ ), consumption coagulopathy (INR = 1.7; aPTT = 27.1 s; fibrinogen = 0.8 g/l; D-dimer = 30.9 mg/l; ISTH DIC score = 7) [8]. The peripheral blood smear revealed the following elements: neutrophils 38%, lymphocytes 46%, monocytes 4%, basophils 1%, metamyelocytes 1%, myelocytes 3%, and lymphoid elements 7%. The bone marrow aspirate was analyzed on the same day, and the diagnosis of acute monoblastic leukemia (AML), 47, XX, +12 [4] / 46, XX [16], wild-type FLT3-ITD and NPM1, was established (Figure 1).

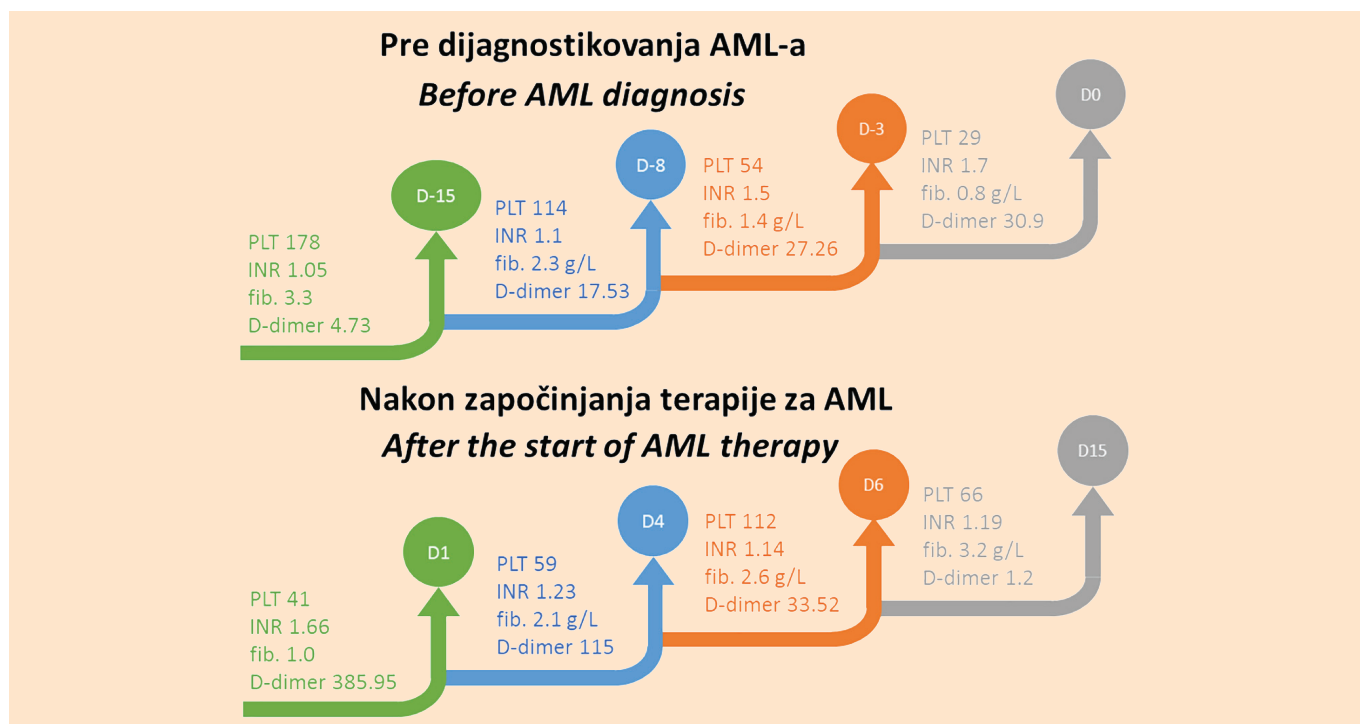
Induction chemotherapy treatment comprising idarubicin and cytarabine was initiated along with supportive measures for DIC management [9]. After the fourth day of treatment, no signs of consumption coagulopathy were present (Graph 1). Fondaparinux was



**Slika 1.** Aspirat koštane srži koji prikazuje infiltraciju leukemijskim blastima; 100x; Mej-Grinvald-Gimza metoda bojenja



**Figure 1.** The bone marrow aspirate showed infiltration of leukemic blasts; 100 x; May-Grünwald Giemsa staining



**Grafikon 1.** Pokazatelji koagulopatije pre i nakon otpočinjanja lečenja AML: AML - akutna monoblastna leukemija; PLT - broj trombocita; INR - internacionalni normalizovani odnos; fib. - fibrinogen; D0 - dan dijagnoze; D1 - dan otpočinjanja lečenja

**Graph 1.** Coagulopathy-related parameters before and after AML treatment: AML – acute monoblastic leukemia; PLT – platelet count; INR – international normalized ratio; fib. – fibrinogen; D0 – day of diagnosis; D1 – day when the treatment started

Fondaparinuks je davan u periodu od četiri nedelje. Aspirat koštane srži procenjen 27. dana lečenja pokazao je da je pacijentkinja postigla kompletnu remisiju.

## DISKUSIJA

D-dimer je koristan i jeftin test, lako dostupan u većini bolnica. Pruža relevantne dijagnostičke i prognostičke podatke u dijagnostici pacijenata kada se koristi na odgovarajući način [1]. Međutim, studije koje se bave primenom analize D-dimera u praksi su otkrile da je 40% – 60% izvršenih testova nepotrebno [10,11]. Jednom merene, visoke vrednosti D-dimera se ne mogu zanemariti, imajući u vidu potencijalno fatalne komplikacije kao što je PE [12]. Ovo može dovesti do fenomena poznatog kao dijagnostička kaskada koji ima za posledicu sprovođenje još više dijagnostičkih testova, neprijatnost za pacijenta, štetu po pacijenta i povećanje troškova zdravstvene zaštite [10,11].

U našem slučaju, glavni razlog nepotrebnog testiranja je ubrzavanje protoka pacijenata u Urgentnom centru. Prijavljeno je da u nekim ambulancama urgentne medicine testove krvi vrše medicinske sestre i pomoćno zdravstveno osoblje pre lekarske procene kako bi se smanjilo vreme koje pacijent provodi u urgentnoj službi. Ovakva praksa je dovela do nepotrebne dijagnostike, čak i kod pacijenata sa jasnom dijagnozom [12].

Nadalje, neadekvatna primena D-dimera može biti posledica nedostatka jasnog razumevanja ograničenja

administered for a period of four weeks. Bone marrow aspirate assessed on the 27<sup>th</sup> day of treatment showed that the patient had achieved complete remission.

## DISCUSSION

D-dimer is a useful and inexpensive test, readily available in most hospitals. It provides relevant diagnostic and prognostic information in patient workup when used appropriately [1]. However, studies looking at real-world D-dimer testing have found that 40% – 60% of the tests performed are unnecessary [10,11]. Once measured, high D-dimer values cannot be ignored, bearing in mind potentially fatal complications such as PE [12]. This can lead to a phenomenon known as the diagnostic cascade resulting in more diagnostic tests as well as patient discomfort, harm to the patient, and increased healthcare costs [10,11].

In our case, the main reason for unnecessary testing is speeding up the patient flow in the ED. It has been reported that in some EDs, blood tests are performed by nurses and healthcare assistants before medical assessment so as to reduce the time that the patient spends in the ER. This practice has led to unnecessary diagnostics, even in patients with a clear diagnosis [12].

Furthermore, the inappropriate use of D-dimer may be due to the lack of a clear understanding of the limitations of this test. There is a general perception that a D-dimer test is the investigative tool of choice

ovog testa. Postoji opšta percepcija da je D-dimer test analiza prvog izbora za dijagnozu venske tromboembolije kod svakog pacijenta, a da se pri tom dovoljno ne razmatranja klinički status pacijenta i komorbiditeti [13]. D-dimer može biti povišen u brojnim stanjima. Studija koju su sproveli Šut i saradnici pokazala je da su među pacijentima sa izuzetno povišenom vrednošću D-dimera (> 10 x iznad granične vrednosti) prisutna sledeća stanja: plućna embolija (32%), malignitet (29%), sepsa (24%), trauma/operacija (24%), te duboka venska tromboza (13%). Zbog toga ovi autori sugerišu da ekstremno povišen nivo D-dimera može ukazati na malignitet čak i u prisustvu tromboze [14]. Ukoliko znamo da procenimo koji pacijenti će imati koristi od testiranja D-dimera i umemo da ih adekvatno identifikujemo prilikom prijema u ambulantne urgentne medicine, smanjićemo broj nepotrebnih snimanja [1]. Pokazalo se da D-dimer treba testirati samo kod pacijenata sa malom kliničkom verovatnoćom za vensku tromboemboliju, nakon procene skorova kliničke verovatnoće. Kod onih sa velikom kliničkom verovatnoćom, malo je verovatno da će ovaj test imati značajan klinički dorinos [13].

Slučaj naše pacijentkinje pokazuje da započinjanje terapije antikoagulansima bez jasno utvrđenog razloga povišenog D-dimera može dovesti do različitih komplikacija i odložene dijagnoze. Jedna od prvih komplikacija kod naše pacijentkinje je bila heparinom indukovana trombocitopenija – HIT. Kod pacijenata sa HIT-om, broj trombocita se često vraća na bazalni nivo nakon prestanka lečenja derivatima heparina. Međutim, kod naše pacijentkinje, trombociti su nastavili da opadaju čak i nakon što je prekinuto davanje LMWH-a. Dalji testovi i klinički pregled otkrili su DIC (ISTH DIC skor = 7). Prevalencija DIC-a kod akutne leukemije varira u različitim studijama između 8,5% i 25% među pacijentima sa ne-akutnom promijelocitnom AML i akutnom limfoblastnom leukemijom [15]. Kod naše pacijentkinje, DIC je verovatno bio uzrokovan osnovnom bolešću, odnosno AML-om, međutim, treba uzeti u obzir i DIC povezan sa HIT-om, što bi mogla biti još jedna komplikacija neadekvatne upotrebe LMWH-a [16].

## ZAKLJUČAK

D-dimer je odličan dijagnostički pokazatelj, kada se pravilno koristi. Nikada se ne sme sagledavati kao izolovan rezultat, a odluku o uvođenju antikoagulantne terapije nikada ne treba donositi samo na osnovu njegove vrednosti. Na ovaj način se mogu izbeći ozbiljne komplikacije, kao što su krvarenje ili HIT. S druge strane, treba izvršiti detaljnu dijagnostičku obradu kod pacijenata sa povišenim D-dimerom i ništa se ne sme prenebregnuti.

**Sukob interesa:** Nije prijavljen.

for the diagnosis of venous thromboembolism in any patient, without enough consideration having been given to their clinical status and comorbidities [13]. D-dimer can be elevated in numerous conditions. A study by Schutte et al. showed that among patients with extremely elevated D-dimer levels (> 10 x cut-off), the following conditions were present: pulmonary embolism (32%), cancer (29%), sepsis (24%), trauma/surgery (24%), and deep vein thrombosis (13%). This is why these authors propose that an extremely elevated D-dimer level should raise suspicion of cancer even in the presence of thrombosis [14]. Knowing which patients will benefit from a testing the D-dimer level and selecting them appropriately in the ED will reduce unnecessary imaging tests [1]. It has been shown that a D-dimer test should be requested only in patients with a low clinical probability of venous thromboembolism after the assessment of the clinical probability scores. In those with high clinical probability, this test is unlikely to add any useful diagnostic value [13].

The case of our patient shows that starting anticoagulant therapy without a clearly determined reason for D-dimer elevation can lead to different complications and delayed diagnosis. One of the first complications in our patient was HIT. In patients with HIT, the platelet count often returns to basal levels after the cessation of treatment with heparin derivatives. However, in our patient, PC continued to decline even after LMWH was discontinued. Further tests and a physical examination revealed DIC (ISTH DIC score = 7). The prevalence of DIC in acute leukemia varies in different studies between 8.5% and 25% among non-acute promyelocytic AML and acute lymphoblastic leukemia patients [15]. In our patient, DIC was probably caused by the underlying AML, however, we should also take into consideration HIT-associated DIC, which could be another complication of the inappropriate use of LMWH [16].

## CONCLUSION

D-dimer is a powerful diagnostic tool when used properly. It should never be treated as a single, isolated result and the decision to introduce anticoagulant therapy should never be made based on its value alone. In this way, serious complications like bleeding or HIT may be avoided. On the other hand, thorough diagnostic workup in patients with elevated D-dimer should be performed and nothing ought to be overlooked.

**Conflict of interest:** None declared.

## LITERATURA / REFERENCES

1. Innocenti F, Lazzari C, Ricci F, Paolucci E, Agishev I, Pini R. D-dimer tests in the emergency department: current insights. *Open Access Emerg Med*. 2021 Nov 11;13:465-79. doi: 10.2147/OAEM.S238696.
2. Johnson ED, Schell JC, Rodgers GM. The D-dimer assay. *Am J Hematol*. 2019 Jul;94(7):833-9. doi: 10.1002/ajh.25482.
3. Thachil J, Lippi G, Favaloro EJ. D-dimer testing: laboratory aspects and current issues, *Methods Mol Biol*. 2017;1646:91-104. doi: 10.1007/978-1-4939-7196-1\_7.
4. Auditeau C, Khider L, Planquette B, Sanchez O, Smadja DM, Gendron N. D-dimer testing in clinical practice in the era of COVID-19. *Res Pract Thromb Haemost*. 2022 May 25;6(4):e12730. doi: 10.1002/rth2.12730.
5. Wells PS, Anderson DR, Rodger M, Forgie M, Kearon C, Dreyer J, et al. Evaluation of D-dimer in the diagnosis of suspected deep-vein thrombosis. *N Engl J Med*. 2003 Sep 25;349(13):1227-35. doi: 10.1056/NEJMoa023153.
6. Wells PS, Anderson DR, Rodger M, Ginsberg JS, Kearon C, Gent M, et al. Derivation of a simple clinical model to categorize patients probability of pulmonary embolism: increasing the models utility with the SimpliRED D-dimer. *Thromb Haemost*. 2000 Mar;83(3):416-20.
7. Lo GK, Juhl D, Warkentin TE, Sigouin CS, Eichler P, Greinacher A. Evaluation of pretest clinical score (4 T's) for the diagnosis of heparin-induced thrombocytopenia in two clinical settings. *J Thromb Haemost*. 2006 Apr;4(4):759-65. doi: 10.1111/j.1538-7836.2006.01787.x.
8. Taylor FB, Toh CH, Hoots WK, Wada H, Levi M; Scientific Subcommittee on Disseminated Intravascular Coagulation (DIC) of the International Society on Thrombosis and Haemostasis (ISTH). Towards definition, clinical and laboratory criteria, and a scoring system for disseminated intravascular coagulation. *Thromb Haemost*. 2001 Nov;86(5):1327-30.
9. Levi M, Toh CH, Thachil J, Watson HG. Guidelines for the diagnosis and management of disseminated intravascular coagulation. *Br J Haematol*. 2009 Apr;145(1):24-33. doi: 10.1111/j.1365-2141.2009.07600.x.
10. Kamolratanapiboon K, Tantanate C. Inappropriate use of D-dimer and impact on the test characteristics for deep vein thrombosis exclusion. *Scand J Clin Lab Invest*. 2019 Oct;79(6):431-6. doi: 10.1080/00365513.2019.1658214.
11. Oliver M, Karkhaneh M, Karathra J, Goubran M, Wu CM. A Review of inappropriate D-dimer ordering at a Canadian tertiary care centre. *Blood* 2019;134(Suppl 1):5778. doi: 10.1182/blood-2019-122617.
12. Jones P, Elangbam B, Williams NR. Inappropriate use and interpretation of D-dimer testing in the emergency department: an unexpected adverse effect of meeting the "4-h target." *Emerg Med J*. 2010 Jan;27(1):43-7. doi: 10.1136/emj.2009.075838.
13. Thachil J, Fitzmaurice DA, Toh CH. Appropriate use of D-dimer in hospital patients. *Am J Med*. 2010 Jan;123(1):17-9. doi: 10.1016/j.amjmed.2009.09.011.
14. Schutte T, Thijs A, Smulders YM. Never ignore extremely elevated D-dimer levels: they are specific for serious illness. *Neth J Med*. 2016 Dec;74(10):443-8.
15. Ten Cate H, Leader A. Management of disseminated intravascular coagulation in acute leukemias. *Hamostaseologie*. 2021 Apr;41(2):120-6. doi: 10.1055/a-1393-8302.
16. Greinacher A, Selleng K, Warkentin TE. Autoimmune heparin-induced thrombocytopenia. *J Thromb Haemost*. 2017 Nov;15(11):2099-114. doi: 10.1111/jth.13813.